

Zenith Alpha[®] 2 Thoracic Endovascular Graft

Instructions for Use



TABLE OF CONTENTS

1. DEVICE DESCRIPTION 8

1.1 Construction of Device 8

1.2 Performance Characteristics 8

1.3 Specifications 8

1.4 Device Compatibility 8

1.5 Qualitative and Quantitative Information 8

1.6 Patient Population 8

1.7 Intended User 8

1.8 Contact with Body Tissue 8

1.9 Operating Principle 8

2. INTENDED USE 8

3. INDICATIONS FOR USE 8

4. CONTRAINDICATIONS 9

5. WARNINGS 9

5.1 General Warnings 9

5.2 Sterile and Single Use 9

5.3 Malfunctions/Changes in Performance 9

6. PRECAUTIONS 9

6.1 General Precautions 9

6.2 Malfunctions/Changes in Performance 9

6.3 Exposure from Surroundings 10

6.4 Interference 10

6.5 Allergic Reaction 10

6.6 Training Requirements for User 10

6.7 Requirements for Facilities 10

7. MRI SAFETY INFORMATION 10

8. POTENTIAL ADVERSE EVENTS 10

9. CLINICAL STUDIES 11

9.1 Clinical Study for the Aneurysm/Ulcer Indication (Through 2 Years) 11

9.2 Summary of Supplemental Clinical Information 22

9.2.1 Continued Access – Aneurysm/Ulcer Indication (Through 2 Years) 22

9.2.2 European Post-Market Survey – Delivery System with Rotational Handle 22

9.3 Post-Approval Study 23

9.3.1 Summary of the Post-Approval Study Methods 23

9.3.2 Summary of the Post-Approval Study Results 23

9.3.2.1 Summary of Final Safety and Effectiveness Findings from the Post-Approval Study (Long-Term Results) 23

9.3.2.2 Study Strengths and Weaknesses 28

10. STERILIZATION 28

11. HOW SUPPLIED 28

12. INSPECTION OF DEVICE 28

13. DEVICE PREPARATION 28

13.1 Preprocedure Imaging and Measuring Guidelines 28

13.2 Device Selection 28

13.2.1 ZTA2 Stent Graft Diameter Sizing Guidelines 28

13.2.2 ZTA2 Stent Graft Length Sizing Guidelines 29

13.2.3 Proximal and Distal Stent Graft Overlap 29

13.3 Preprocedure Preparation 29

14. INSTRUCTIONS FOR USE 29

14.1 Patient Preparation 29

14.2 Step-by-Step Guide 29

14.2.1 Proximal and Distal Stent Graft Preparation and Flush 29

14.2.2 Placement of Proximal Stent Graft 29

14.2.3 Placement of Distal Stent Graft 30

14.2.4 Molding Balloon Insertion – Optional 30

14.2.5 Final Angiogram 30

14.3 Ancillary Devices: Distal Extension 30

14.3.1 General Use Information 30

14.3.2 Distal Extension Preparation and Flush 30

14.3.3 Placement of Distal Extension 31

14.4 Release Troubleshooting 31

14.4.1 Difficulty Removing Release Wires 31

14.5 Imaging Guidelines and Postoperative Follow-Up 31

14.5.1 Contrast and Non-Contrast CT 31

15. REQUIRED EQUIPMENT AND ACCESSORIES 31

15.1 Materials Required 31

15.2 Materials Recommended 31

16. DISPOSAL OF DEVICE 32

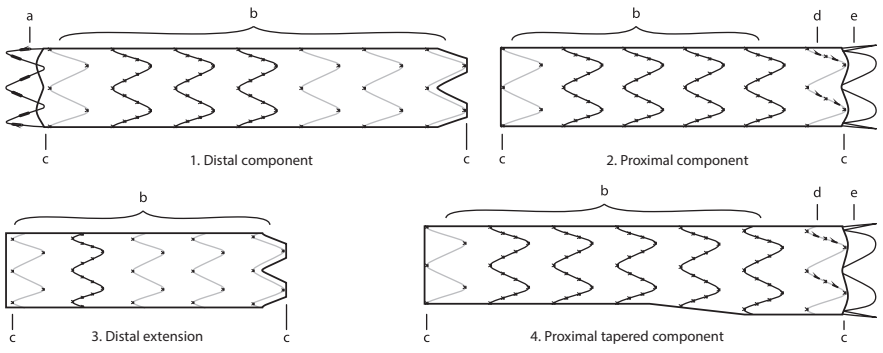
17. REFERENCES 32

18. PATIENT COUNSELING 32

18.1 Symptoms 32

18.2 Follow-Up Information for the Patient 32

19. SERIOUS INCIDENT REPORTING 32



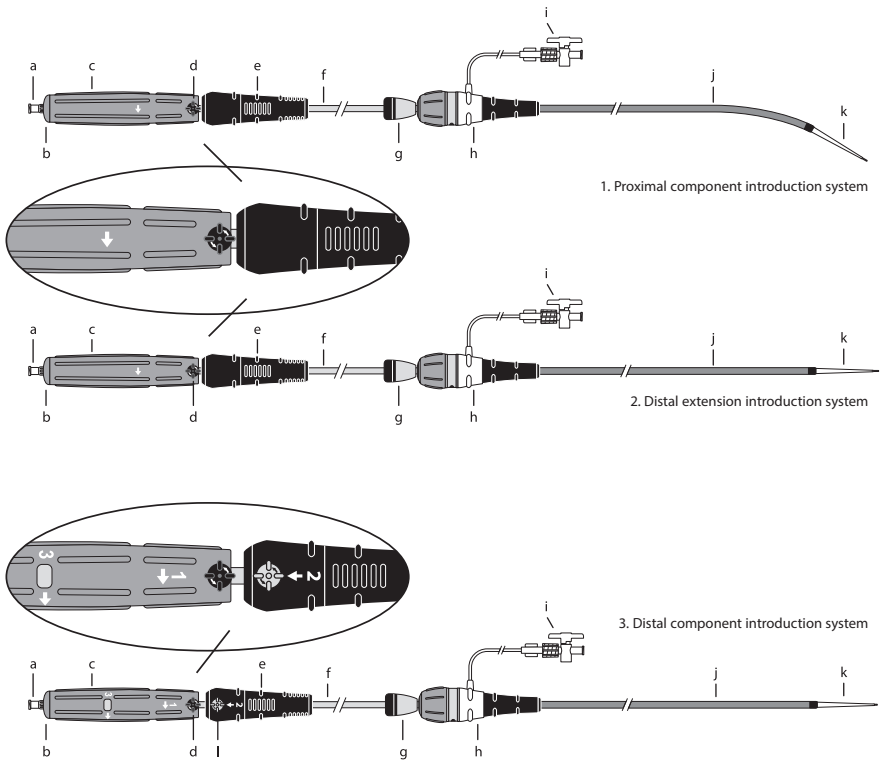
1

EN

1. Distal component
2. Proximal component
3. Distal extension
4. Proximal tapered component

Stent Graft Elements

- a. Distal bare stent with barbs
- b. Body stent (internal or external)
- c. Gold radiopaque markers (located near stent apices on proximal and distal edges of graft)
- d. Proximal sealing stent with barbs
- e. Proximal bare stent



2

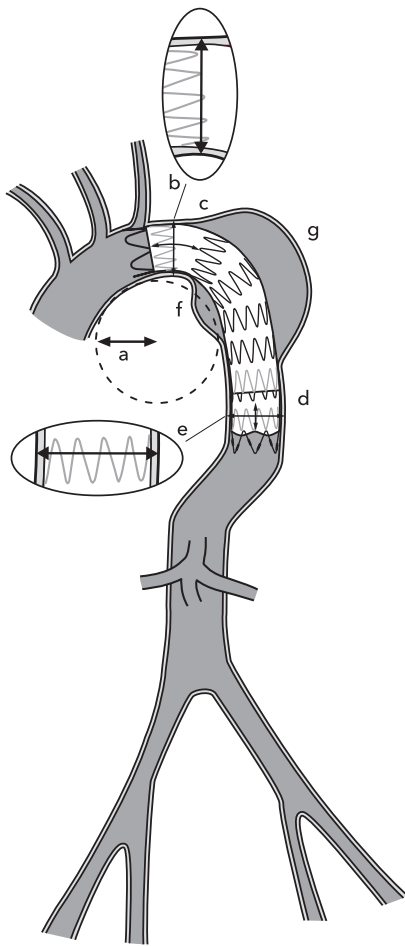
EN

1. Proximal component introduction system
2. Distal extension introduction system
3. Distal component introduction system

Introduction System Elements

- a. Cannula hub
- b. Back-end cap
- c. Blue rotation handle
- d. Black safety-lock knob
- e. Black gripper (telescoping on distal component)
- f. Gray positioner
- g. Captor® sleeve
- h. Captor® hemostatic valve
- i. Connecting tube with stopcock
- j. Flexor® introducer sheath
- k. Dilator tip
- l. Gray safety-lock knob

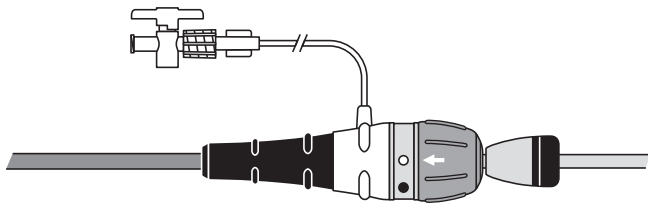
3



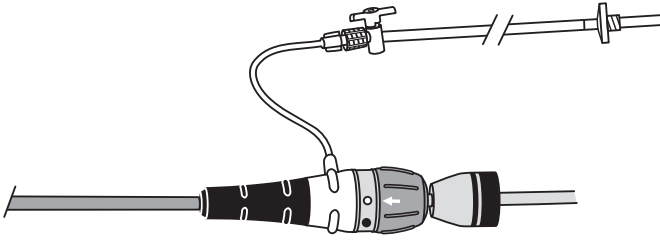
3

EN

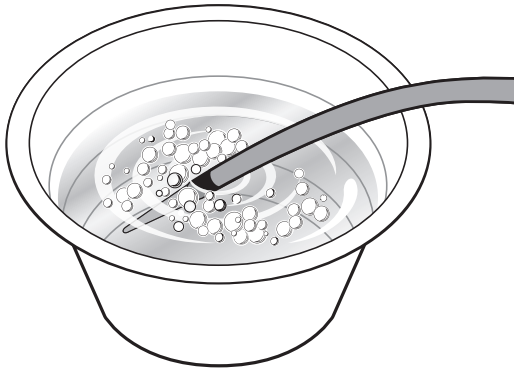
- a. Aortic arch radius of curvature ≥ 20 mm
- b. Proximal neck diameter 20-42 mm
- c. Proximal neck length ≥ 20 mm
- d. Distal neck length ≥ 20 mm
- e. Distal neck diameter 20-42 mm
- f. Lesser curve
- g. Greater curve



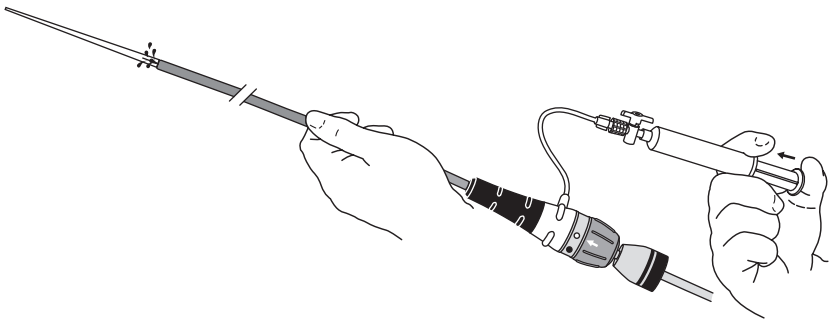
4



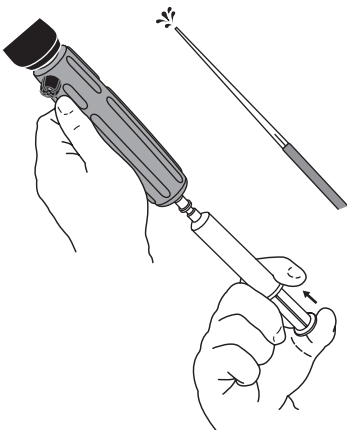
5



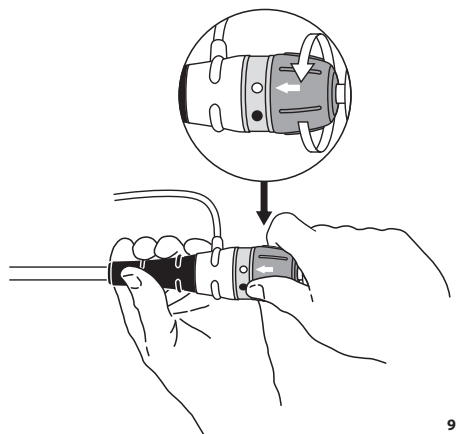
6



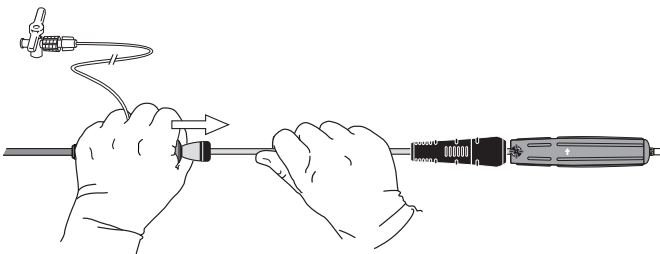
7



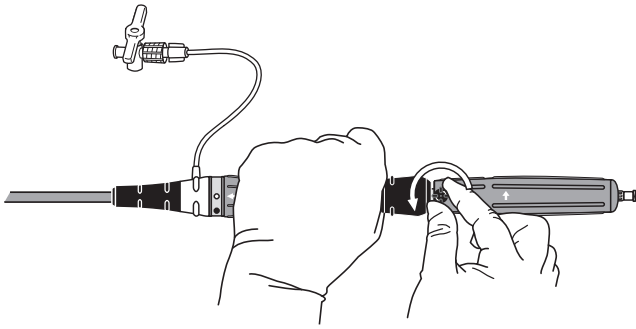
8



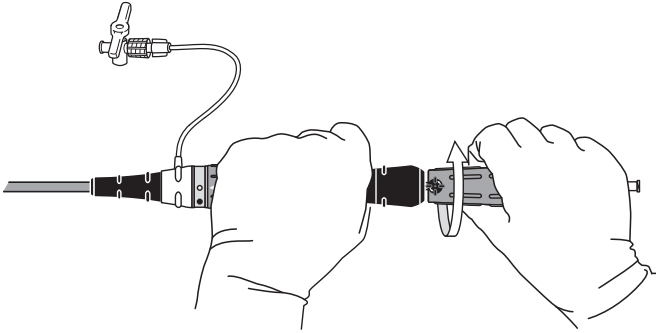
9



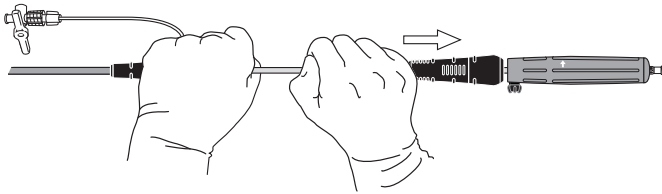
10



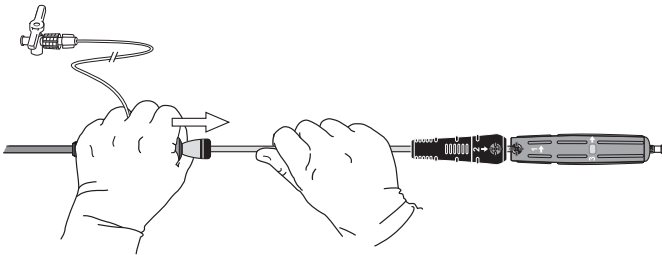
11



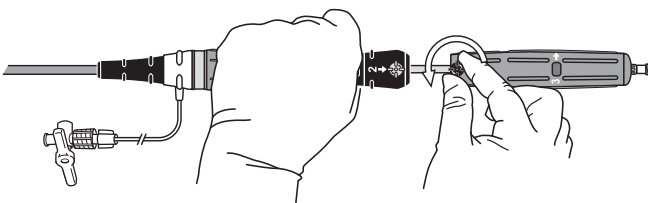
12



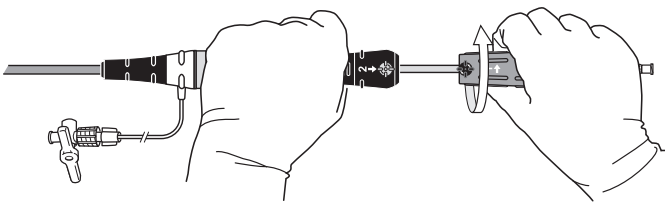
13



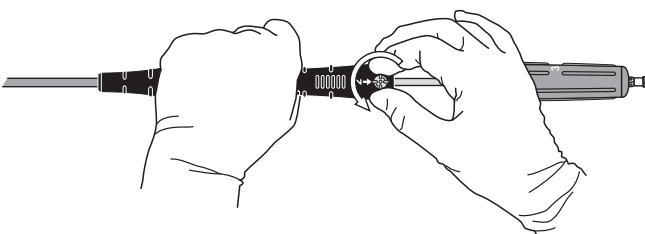
14



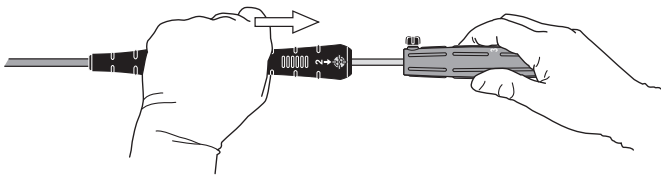
15



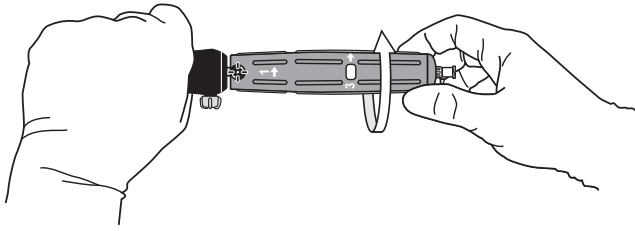
16



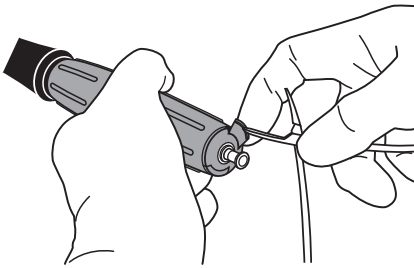
17



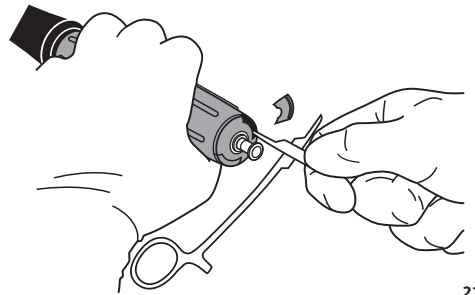
18



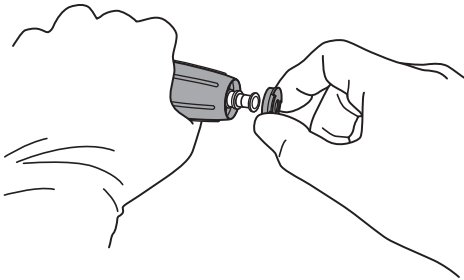
19



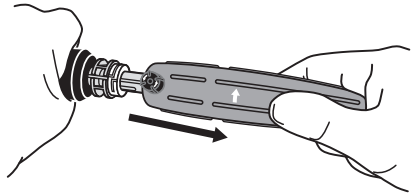
20



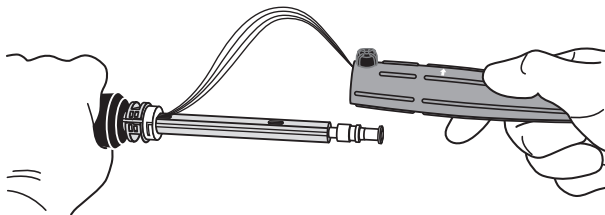
21



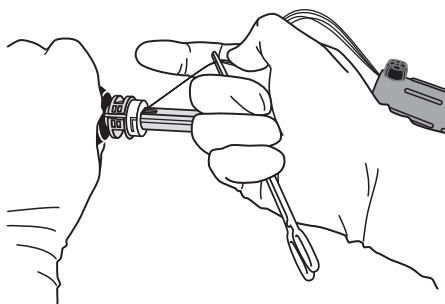
22



23



24



25

ZENITH ALPHA® 2 THORACIC ENDOVASCULAR GRAFT

Read all instructions carefully. Failure to properly follow the information provided may lead to the device not performing as intended or injury to the patient.

STERILE—DO NOT RESTERILIZE—SINGLE USE ONLY.

CAUTION: US federal law restricts this device to sale by or on the order of a physician (or properly licensed practitioner).

1. DEVICE DESCRIPTION

1.1 Construction of Device

The Zenith Alpha 2 Thoracic Endovascular Graft (hereinafter referred to as the ZTA2) is identical in design with the Zenith Alpha Thoracic Endovascular Graft (ZTA) implant and consists of a stent graft preloaded into an introduction system.

The ZTA2 is a two-piece cylindrical endovascular system consisting of proximal (ZTA2-P(T)-/-) and distal (ZTA2-D(-/-) stent graft components. The proximal component can be either tapered (ZTA2-PT(-/-) or non-tapered (ZTA2-P(-/-)). An endovascular ancillary component is available as a distal extension (ZTA2-DE(-/-)). The stent grafts are constructed of woven polyester fabric sewn to self-expanding nitinol (a nickel-titanium based alloy) stents with braided polyester and monofilament polypropylene suture.

The proximal component has one proximal bare stent, one proximal internal sealing stent with fixation bars that protrude through the graft material, and one distal internal sealing stent. The distal component has three proximal internal sealing stents, one distal internal sealing stent, and one distal bare stent with bars. The distal extension has three proximal internal sealing stents and one distal internal sealing stent. Gold markers are placed on the graft at the proximal and distal aspects of the graft margins on all components. (Fig. 1)

Introduction System

The stent grafts are deployed from a 16 French (6 mm OD), 18 French (7.1 mm OD), or 20 French (7.7 mm OD) introduction system. The introduction system features a Flexor® introducer sheath with a Captor® hemostatic valve. The proximal component's introduction system is slightly precurved. (Fig. 2) The delivery mechanism is identical between the ZTA and ZTA2 introduction systems; however, minor design changes were made to ZTA2. The ZTA2 introduction system also introduces the optional ability to flush with carbon dioxide (CO₂) in addition to saline prior to device introduction.

1.2 Performance Characteristics

The proximal component may be used independently (for ulcers/saccular aneurysms) or in combination with a distal component. Distal extensions can be used to provide additional length to the stent graft distally or to increase the length of overlap between stent grafts. An additional proximal component may be used to extend graft coverage proximally.

All components are fully stented to provide stability and the expansive force necessary to open the lumen of the stent graft during deployment. Additionally, the nitinol stents provide the necessary attachment and seal of the stent graft to the vessel wall. By sealing to the wall and directing the blood flow through the stent graft, the aortic lesion is excluded.

For added fixation and sealing, the proximal component has a proximal internal sealing stent with fixation bars that protrude through the graft material. In addition, the distal bare stent at the distal end of the distal component also contains bars. The distal extension has three proximal internal sealing stents

and one distal internal sealing stent for enhanced sealing.

To assist with alignment, the proximal component has a proximal bare stent. On proximal components with diameters of 40-46 mm, the proximal sealing stent remains constrained until final deployment to ensure alignment with the inner curvature of the aorta.

Fluoroscopic visualization of the components is facilitated by gold radiopaque markers positioned on each end of the components, denoting the edge of the graft material.

The introduction system has a sequential deployment method with built-in features to provide continuous control of the stent graft throughout the deployment procedure. The introduction system enables precise positioning before deployment of the proximal and distal components.

The slight pre-curve of the introduction system for the proximal component assists in proximal inner wall apposition of the stent graft during deployment. (Fig. 2) These systems use either a single locking mechanism (for the proximal component and distal extension) or dual locking mechanism (for the distal component) to secure the stent graft onto the introduction system until the physician releases it. The locking mechanism is released by turning the blue rotation handle.

The Captor hemostatic valve can be loosened or tightened when introducing or removing secondary devices in and out of the sheath. Tightening the Captor hemostatic valve reduces bleeding. The Flexor introducer sheath resists kinking and has a hydrophilic coating. Both features are intended to enhance trackability in the iliac arteries and the thoracic aorta. To activate the hydrophilic coating, the surface must be wiped with a sterile gauze pad soaked in saline solution under sterile conditions. The hydrophilic coating must be kept hydrated for optimal performance.

1.3 Specifications

The ZTA2 is designed to be compatible with aortic neck diameters no smaller than 20 mm and no larger than 42 mm. The ZTA2 is designed to treat proximal aortic necks (distal to either the left subclavian or left common carotid artery) of at least 20 mm in length. Stent graft length should be selected to cover the aneurysm or ulcer as measured along the greater curve of the aneurysm, plus a minimum of 20 mm of seal zone on the proximal and distal ends. A distal aortic neck length of at least 20 mm proximal to the celiac axis is required.

The ZTA2 introduction system has a sheath length of 85 cm. Information on available stent graft sizes and introduction system measures are described in Section 13.2, Device Selection.

1.4 Device Compatibility

All ZTA2 introduction systems are compatible with:

- A 0.035 inch (0.89 mm) wire guide:
 - extra stiff wire guide, 260/300 cm:
 - Cook Lunderquist® Extra Stiff Wire Guides (LESDC)
 - Cook Amplat Ultra Stiff Wire Guides (AUS)
 - standard wire guide:
 - Cook 0.035 inch (0.89 mm) wire guides
 - Cook 0.035 inch (0.89 mm) Bentson Wire Guide
 - Cook Nimble® Wire Guides
- Molding balloon if applicable:
 - Cook Coda® Balloon Catheter

1.5 Qualitative and Quantitative Information

The maximum composition representative in terms of size and materials is presented in Table 1.

Table 1 – Qualitative and Quantitative Information for the Stent Graft

Qualitative Information Implant Material		Quantitative Information Weight (grams) per Implant ¹
Nitinol (nickel-titanium based alloy)	Stent	Up to 3.61
Polyethylene Terephthalate	Graft	Up to 3.07
Polyethylene Terephthalate	Suture	Up to 0.13
Gold	Marker band	Up to 0.09
Polypropylene	Suture	Up to 0.07
Graphite	Marker	Less than 0.01

¹ The weights listed are per implant. If multiple implants are implanted the weight is relative to the number of implants.

1.6 Patient Population

The ZTA2 is for adult patients (18 years and older) with aneurysms or ulcer in the descending thoracic aorta. The risks and benefits should be carefully considered for each patient before use of the ZTA2.

Patients to be treated with the ZTA2 should fulfill the following anatomical requirements:

- Proximal and distal aortic neck lengths should be a minimum of 20 mm. Additional proximal aortic neck length may be gained by covering the left subclavian artery (with or without discretionary transposition, see Section 5.1, General Warnings) when necessary to optimize stent graft fixation and maximize aortic neck length. The distal aortic neck must be at least 20 mm proximal to the celiac axis.
- Aortic neck diameters measured outer-wall-to-outer-wall should be between 20-42 mm.
- Vascular anatomy suitable for endovascular repair, including:
 - radius of curvature greater than or equal to 20 mm along the entire length of the aorta intended to be treated
 - no localized angulation should be larger than 45°
 - iliofemoral access vessel size and anatomy (thrombus, calcification and/or tortuosity) should be compatible with vascular access techniques and accessories of the delivery profile of a 16 French (6 mm OD) to 20 French (7.7 mm OD) vascular introducer sheath. Arterial conduit technique may be required.

These sizing measurements are critical to the performance of the endovascular repair. Successful patient selection requires specific imaging and accurate measurements. Measurements to be taken during the pretreatment assessment are shown in Fig. 3.

Additional considerations for patient selection include, but are not limited to:

- Patient's age and life expectancy
- Comorbidities (e.g., cardiac, pulmonary, or renal insufficiency prior to surgery, morbid obesity)
- Patient's suitability for open surgical repair
- The risk of thoracic aneurysm or ulcer rupture compared to the risk of treatment with the ZTA2
- Ability to tolerate general, regional, or local anesthesia
- Ability to tolerate contrast media
- Ability and willingness to undergo and comply with the required follow-up

The final treatment decision is at the discretion of the physician and patient.

1.7 Intended User

The ZTA2 should be used only by physicians and teams trained in vascular interventional techniques (endovascular and surgical) and in the use of this device.

1.8 Contact with Body Tissue

The ZTA2 stent graft is categorized as an implantable medical device that is in direct contact with circulating blood in elements of the central circulatory system, that is the aorta, extending from the arch to the descending thoracic section. The contact duration is long-term exposure (>30 days).

The ZTA2 introduction system's primary type of body contact is short direct contact with circulating blood (some components have indirect contact to the bloodstream) and with the patient's skin on the thigh for iliac/femoral access into the iliac artery and the aorta. The introduction system is thus categorized as an externally communicating device with contact to circulating blood (limited contact duration, ≤24 hours).

1.9 Operating Principle

The ZTA2 is introduced into the aorta over a wire guide. Standard techniques for placement of vascular access sheaths, guiding catheters, angiographic catheters, and wire guides should be employed. If the patient has a difficult anatomy, brachio-femoral wire guide technique may be required. The stent graft is delivered in an introduction system and is exposed by pulling back the sheath when the introduction system is at the desired position.

Appropriate procedural imaging is required to position the stent graft accurately and successfully. Fluoroscopy and contrast media should be used during introduction and deployment to confirm proper placement of the introduction system, and proper placement of the stent graft.

2. INTENDED USE

The Zenith Alpha 2 Thoracic Endovascular Graft is intended to provide an intravascular conduit that excludes the thoracic aortic lesion from blood flow while maintaining the aortic blood flow distal to the lesion.

3. INDICATIONS FOR USE

The Zenith Alpha 2 Thoracic Endovascular Graft is indicated for the endovascular treatment of patients with aneurysms or ulcers of the descending thoracic aorta having vascular morphology suitable for endovascular repair (Fig. 3), including:

- Iliac/femoral anatomy that is suitable for access with the required introduction systems

- Nonaneurysmal aortic segments (fixation sites) proximal and distal to the thoracic aneurysm or ulcer:
- with a length of at least 20 mm, and
- with a diameter measured outer-wall-to-outer-wall of no greater than 42 mm and no less than 20 mm

4. CONTRAINDICATIONS

- Known allergic reactions to one of the materials in the device should always be considered a contraindication.
- Do not use this device on patients who have a systemic infection or a condition that threatens to infect the endovascular graft, as it may result in serious harm.

5. WARNINGS

5.1 General Warnings

- The ZTA2 should be used only by physicians and teams trained in vascular interventional techniques (catheter based and surgical) and in the use of this device.
- Always have a qualified surgical team available in the event that conversion to open surgical repair is necessary.
- Due to the imaging (e.g., x-ray, CT) required for successful placement and follow-up of endovascular devices, the risk of harms due to accumulated radiation exposure should be considered and discussed with the patient. Furthermore, the risk of radiation exposure to developing tissue should be discussed with women who are or suspect they are pregnant.
- Additional endovascular interventions or conversion to standard open surgical repair following initial endovascular repair should be considered for patients experiencing enlarging aneurysms or ulcers, unacceptable decrease in fixation length (vessel and component overlap), and/or endoleak. An increase in aneurysm or ulcer size and/or persistent endoleak or migration may lead to rupture of the aneurysm or ulcer.
- Patients experiencing leaks or reduced blood flow through the stent graft may be required to undergo secondary endovascular interventions or surgical procedures.
- A distal and/or proximal sealing zone of 20 mm is required. If a sealing zone of 20 mm is not achieved, this may result in endoleak, device migration, and/or aneurysm growth.
- In patients with a large proximal aortic vessel diameter and aneurysms on the inner curvature, there is a risk that the graft may deploy in an angulated position if the sealing zone is less than 20 mm.
- Land the proximal and the distal ends of the device in parallel aortic neck segments without acute angulation (>45°) or circumferential thrombus/calciification to ensure fixation and seal.
- Inadequate fixation of the ZTA2 stent graft may result in increased risk of migration of the stent graft. Incorrect deployment or migration of the stent graft may require surgical intervention.
- Inaccurate placement and/or incomplete sealing of the ZTA2 stent graft within the vessel may result in increased risk of endoleak, migration, or inadvertent occlusion of the left subclavian, left common carotid, and/or celiac artery.
- When using a distal component, take care to avoid landing the distal bare stent in tortuous anatomy (i.e., localized angulation >45°).
- Key anatomic elements that may affect successful exclusion of the thoracic aneurysm or ulcer include:
 - severe angulation (radius of curvature <20 mm and localized angulation >45°)
 - short proximal or distal fixation sites (<20 mm)
 - an inverted funnel shape at the proximal fixation site or a funnel shape at the distal fixation site (greater than a 10% change in diameter over 20 mm of fixation site length)
 - circumferential thrombus and/or calciification at the arterial fixation sites. Irregular calciification and/or plaque may compromise the attachment and sealing at the fixation sites.
- In the presence of anatomical limitations, a longer neck length may be required to obtain adequate sealing and fixation. Necks exhibiting these key anatomic elements may be more conducive to graft migration.
- Risk of in-graft thrombus has been observed when stent grafts have been used to treat blunt thoracic aortic injuries.
- The ZTA2 is not recommended for patients who cannot tolerate contrast media necessary for intraoperative and postoperative follow-up imaging, or who are unable to undergo, or will not be compliant with, the necessary preoperative and postoperative imaging guidelines as described in **Section 18.2, Follow-Up Information for the Patient.**
- Patients with a pre-existing renal insufficiency may have an increased risk of postoperative renal failure, due to the use of contrast media during the procedure.
- Unless medically indicated, do not deploy the ZTA2 stent graft in a location that will occlude arteries necessary to supply blood flow to organs or extremities. Do not cover significant arch or mesenteric arteries (an exception may be the left subclavian artery) with the device. Vessel occlusion may occur. If a left subclavian artery (LSA) is to be covered with the device, the clinician should be aware of the possibility of compromise to cerebral and upper limb circulation and collateral circulation to the spinal cord.
- If occlusion of the left subclavian artery ostium is required to obtain adequate neck length for fixation and sealing, transposition or bypass of the left subclavian artery should always be evaluated and planned when possible:
 - In elective TEVAR where coverage of LSA is necessary for adequate stent graft seal, TEVAR should always be preceded by a hemodynamic evaluation.
 - In patients where anatomy compromises blood flow to vital organs, routine preoperative LSA revascularization is recommended.
 - In emergent TEVAR where coverage of LSA is necessary for adequate stent graft seal, decision on revascularization should be individualized based on the patient's anatomy and urgency of the procedure.
- Graft implantation may cause paraplegia or paraparesis where graft exclusion covers the origins of dominant spinal cord or intercostal arteries.
- Catheterization of the iliofemoral access vessel may cause access site injury (e.g., hematoma, hemorrhage, and/or vessel injury).
- There is a risk of infection as the skin barrier is compromised by incision of the skin.

5.2 Sterile and Single Use

- Do not use the device if the sterile packaging is damaged or unintentionally opened before use, as it may cause a severe infection.
- This single-use device is not designed for reuse. If the device is reused it could pose risks of cross contamination with microbiological agents. Attempts to reprocess (sterilize) and/or re-use may lead to device failure and/or transmission of disease.

5.3 Malfunctions/Changes in Performance

- Minimize handling of the device during preparation and insertion to decrease the risk of stent graft contamination and infection.
- Failure to follow the deployment sequence as described in the IFU, may lead to difficulties during deployment, and require release by troubleshooting.

If troubleshooting cannot be completed, it may be necessary to convert to open repair.

- Fluoroscopy should always be used during introduction and deployment to confirm proper operation of the ZTA2 introduction system components, proper placement of the stent graft, and desired procedural outcome. Do not deploy the ZTA2 stent graft until the placement is visualized by fluoroscopic control.
- Do not continue advancement or removal of the wire guide or any portion of the ZTA2 introduction system if resistance is felt. Stop and assess the cause of resistance; excessive friction may cause damage to the vessel, catheter, or stent graft. Damage to the hydrophilic coating, may lead to coating particles in the bloodstream. A replacement of the device during the procedure may increase the risk of injuries to the access site and the vessels.
- Do not expose the proximal bare stent (out of the sheath) prior to or during advancement since this may cause vessel injury.
- Do not retract the device during sheath withdrawal, as it may cause aortic wall damage or perforation. At this stage the proximal bare stent and proximal covered stent with barbs are in contact with the vessel wall. It may be possible to advance the device.
- To avoid twisting the stent graft, never rotate the introduction system during the procedure. Allow the device to conform naturally to the curves and tortuosity of the vessels.

6. PRECAUTIONS

6.1 General Precautions

- The safety and effectiveness of the Zenith Alpha 2 Thoracic Endovascular Graft and ancillary components have not been evaluated in the following patient populations:
 - aortobronchial and aorto-esophageal fistulas
 - aortitis or inflammatory aneurysms
 - diagnosed or suspected genetic connective tissue disease (e.g., Marfans or Ehlers-Danlos Syndrome)
 - dissections
 - females who are pregnant, breastfeeding, or planning to become pregnant within 60 months
 - leaking, pending rupture or ruptured aneurysm
 - patients less than 18 years of age
 - mycotic aneurysms
 - pseudoaneurysms resulting from previous graft placement
 - systemic infection (e.g., sepsis)
 - access vessels that preclude safe insertion
 - inability to preserve the left common carotid artery and celiac artery
 - previous repair in the descending thoracic aorta
 - surgical or endovascular AAA repair within 30 days before or after TAA repair
 - bleeding diathesis, uncorrectable coagulopathy, or refuses blood transfusion
 - stroke within 3 months
 - untreatable reaction to contrast which cannot be adequately predicted
 - Graft length should be selected to cover the aneurysm or ulcer as measured along the greater curve of the aneurysm, plus a minimum of 20 mm of seal zone on the proximal and distal ends. Failure to adhere to this recommendation might result in graft migration or endoleak.
 - In patients with large aneurysms on the outer curvature close to the left subclavian, it may be difficult to track the device around the arch, and extra support may be needed using a brachio-femoral wire.
 - Ensure correct placement, full expansion, and complete sealing and fixation of the ZTA2 stent graft within the vessel.
 - If combining the ZTA2 stent graft with other ZTA2 components, ensure a minimum three-stent overlap to avoid separation between components.
 - Adequate iliac or femoral access is required to introduce the device into the vasculature. Careful evaluation of vessel size, anatomy, and disease state is required to ensure successful sheath introduction and subsequent withdrawal, as vessels that are significantly calcified, occlusive, tortuous, or thrombus lined may preclude introduction of the stent graft and/or increase the risk of embolization. A vascular conduit technique may be necessary to achieve access in some patients.
 - Ensure correct planning and sizing and confirm correct placement of the ZTA2 stent graft. If the ZTA2 stent graft obstructs the blood supply to the spinal cord or the intercostal arteries, organs, or extremities it may result in ischemia related complications, paraparesis/paralysis, or require additional intervention or an open repair.
 - Increased aortic wall thickness due to calciifications should be considered when choosing an appropriate size of stent graft, to ensure complete expansion of the stent graft and sufficient fixation and sealing.
 - Ensure correct planning and sizing to minimize the risk of reduced blood flow increasing the risk of in-graft thrombus.
 - Be sure to land the proximal and distal ends of the device in an aortic neck segment with a diameter that matches the initial sizing of the device. Landing in a segment that is different from the location used to size the device may potentially result in inadequate (<10%) or excessive (>25%) graft diameter oversizing and therefore migration, endoleak, thoracic aneurysm or ulcer growth, or increased risk of thrombosis.
- ##### 6.2 Malfunctions/Changes in Performance
- Device (stent graft or introduction system) modification or alteration is not recommended, as the safety and effectiveness of modified or altered devices have not been established.
 - Ensure that the ZTA2 has been flushed and primed with heparinized saline (or another appropriate flush solution) to remove air from the system.
 - Activate the hydrophilic coating on the tip and sheath, to avoid excessive friction during the procedure. Excessive friction may cause vessel injury, hemorrhage, and increase the procedural time.
 - It is important to monitor blood loss from the hemostatic valve throughout the procedure, but it is specifically relevant during and after manipulation of the gray positioner. If the gray positioner has been removed, and blood loss is excessive, consider placing an uninflated molding balloon or an introduction system dilator within the valve to restrict flow.
 - Maintain wire guide position during introduction system insertion.
 - Exercise caution during manipulation of instruments to avoid excessive pressure and damage to the vessel wall (e.g., increased risk of retrograde dissection in pre-disposed patients).
 - Exercise caution during advancement or removal of the ZTA2 introduction system, particularly in areas of stenosis, thrombotic fragments, or calcified or tortuous vessels.
 - Exercise caution during manipulation of catheters, wires, and sheaths within the thoracic aneurysm or ulcer. Significant disturbances may dislodge fragments of thrombus or plaque, which can cause distal or cerebral embolization or cause rupture of the thoracic aneurysm, ulcer, or aorta.
 - Exercise caution when manipulating the wire guide in close proximity to the heart to avoid arrhythmia. Arrhythmia may lead to formation of a thrombus that may cause thromboembolic events.
 - Exercise caution when manipulating interventional and angiographic devices in the region of the proximal bare stent and distal bare stent.

- As the sheath and/or wire guide is withdrawn, anatomy and graft position may change. Constantly monitor the graft position and perform angiography to check the position as necessary.
- Do not advance the sheath separately while the stent graft is still within it. Advancing the sheath at this stage may cause the barbs to perforate the introducer sheath.
- Do not attempt to re-sheath the stent graft after partial or complete deployment.
- Repositioning the stent graft distally after partial deployment of the covered proximal stent may result in damage to the stent graft, and/or vessel injury.
- In the final angiogram confirm that there are no endoleaks or kinks, that the proximal and distal gold radiopaque markers demonstrate that there is a minimum three-stent overlap between components, and that there is sufficient graft length to maintain over time a minimum of 20 mm in proximal and distal seal.
- If using a balloon, do not inflate the balloon in the aorta outside of the graft, as doing so may cause damage to the aorta. Use the molding balloon in accordance with its labeling.
- Use care when inflating the balloon within the graft in the presence of calcification, as excessive inflation may cause damage to the aorta.
- Confirm complete deflation of the balloon prior to repositioning.

6.3 Exposure from Surroundings

- Follow the MRI Safety Information to avoid excessive heating, torque, and/or deflection, which may cause injury to the vessel.

6.4 Interference

- Image artifacts may occur under MRI scanning, which may prolong diagnostic time and/or require additional imaging.

6.5 Allergic Reaction

- Possible allergic reactions to nitinol (nickel-titanium alloy) should be considered.
- Ensure that the patient does not have impaired tolerance to general, regional, or local anesthesia to avoid adverse reactions associated with the anesthetic procedure.
- Ensure that the patient is not allergic to contrast media since the use of contrast media during the procedure and/or during postoperative imaging may cause an allergic reaction, and/or other contrast-induced harms.
- If an accessory agent (e.g., heparin) required for the procedure is contraindicated, an alternative agent should be used.

6.6 Training Requirements for User

The recommended skill and knowledge requirements for physicians using the ZTA2 are outlined below:

7. MRI SAFETY INFORMATION

- Knowledge of the natural history of thoracic aneurysms/ulcers and comorbidities associated with thoracic aneurysm or ulcer repair.
- Knowledge of radiographic image interpretation, patient selection, device selection, planning, and sizing.

Training qualifications include a multidisciplinary team that has documented experience with endovascular procedures and open surgery according to local guidelines and specialist training e.g.:

- Femoral and brachial cutdown, arteriotomy, and repair or conduit technique
- Percutaneous access and closure techniques
- Nonselective and selective wire guide and catheter techniques
- Fluoroscopic and angiographic image interpretation
- Embolization
- Angioplasty
- Endovascular stent placement
- Snare techniques
- Appropriate use of radiographic contrast material
- Techniques to minimize radiation exposure
- Expertise in necessary patient follow-up modalities

CAUTION: Always have a qualified surgical team available in the event that conversion to open surgical repair is necessary.

6.7 Requirements for Facilities

The ZTA2 is intended for use in hospital operating rooms. Users must wear standard operating room personal protective equipment (PPE; gloves, face mask, sterile gown, etc.) and follow local guidelines for sterile procedures. PPE related to radiation protection is also required.

The introduction system allows for flushing with CO₂ prior to saline flushing to further reduce the residual air inside. In case CO₂ flushing method is applied, the operating room must have access to a medical grade CO₂ source which is equipped with a pressure regulator to allow for a pressure setting. The sterile connecting tube between the CO₂ source and the ZTA2 must include a microbiological filter.

Appropriate procedural imaging is required to successfully position the stent graft and ensure accurate apposition to the aortic wall. Fluoroscopy should be used during introduction and deployment to confirm proper operation of the ZTA2 introduction system, proper placement of the stent graft, and desired procedural outcome. A fluoroscope with digital angiography capabilities (C-arm or fixed unit) is required.

Follow-up should include imaging by an appropriate modality e.g., contrast and non-contrast CT examinations, or MRI.



MR Conditional

A patient with the Zenith Alpha 2 Thoracic Endovascular Graft may be safely scanned under the following conditions. Failure to follow these conditions may result in injury.

Parameter	Notes
¹ Item Name/Identification	Zenith Alpha 2 Thoracic Endovascular Graft
² Item Manufacturer	Cook Medical
³ Static Magnetic Field Strength [T]	1.5 T or 3.0 T
⁴ Maximum Spatial Field Gradient [T/m and gauss/cm]	25.00 T/m (2500 gauss/cm)
⁵ RF Excitation	Circularly Polarized (CP)
⁶ RF Transmit Coil Type	Whole body transmit coil, Head RF transmit-receive coil
⁷ RF Power	Normal Operating Mode
⁸ Maximum Whole Body SAR [W/kg]	2.0 W/kg
⁹ Scan Duration	2.0 W/kg whole body average SAR for 60 minutes of continuous RF (a sequence or back to back series/scan without breaks).
¹⁰ MR Image Artifact	The presence of this implant may produce an image artifact.
If information about a specific parameter is not included, there are no conditions associated with that parameter.	

It is recommended that patients register the conditions under which the implant can be safely scanned with the Medic Alert Foundation (medicalert.org) or an equivalent organization.

8. POTENTIAL ADVERSE EVENTS

Potential adverse events that may occur include the following:

- Allergic reaction (e.g., to contrast media, anti-coagulant, nitinol [nickel-titanium alloy])
- Amputation
- Anesthetic complications and subsequent attendant problems (e.g., aspiration)
- Aneurysm enlargement and aortic rupture
- Aortic damage, including perforation, (retrograde) dissection, bleeding, and rupture
- Aortic valve damage
- Arterial or venous thrombosis
- Bowel complications (e.g., ileus, transient ischemia, infarction, necrosis)
- Cardiac complications and subsequent attendant problems (e.g., arrhythmia, tamponade, myocardial infarction, acute heart failure, transient hypotension, transient hypertension, myocardial perforation)
- Cardiac/myocardial infarction
- Claudication (e.g., buttocks, lower limb)
- Coagulopathy
- Complications related to the stent graft:
 - Incomplete stent graft deployment
 - Improper stent graft placement
 - Stent graft migration and/or separation
- Suture break, stent fracture, stent corrosion, graft material wear, barb separation
- Occlusion
- Dilatation
- Erosion
- Puncture
- Perigraft flow

- Conversion to open repair
- Death
- Edema
- Embolism (e.g., air, blood clots, calcifications)
- Endoleak
- Femoral neuropathy
- Fever
- Fistula (e.g., aorto-bronchial, aorto-duodenal, aorto-esophageal, aorto-pulmonary)
- Gastrointestinal tract injury (e.g., esophagus necrosis)
- Genitourinary complications and subsequent attendant problems (e.g., ischemia, urinary incontinence, infection, temporary sexual dysfunction)
- Hematoma
- Hemorrhage
- Increased procedural time
- Infection (e.g., of the aneurysm, device, or access site, including abscess formation, transient fever, pain)
- Local or systemic neurologic complications and subsequent attendant problems (e.g., stroke, transient ischemic attack, spinal cord ischemia, paraparesis, paraplegia, paralysis)
- Lymphatic complications and subsequent attendant problems (e.g., lymph fistula, lymphocele)
- Post-implantation syndrome (fever and/or inflammation)
- Prenatal radiation exposure
- Pseudoaneurysm
- Pulmonary embolism
- Pulmonary/respiratory complications and subsequent attendant problems (e.g., pneumonia, respiratory failure, prolonged intubation)
- Radiation exposure
- Reintervention
- Renal complications and subsequent attendant problems (e.g., artery occlusion, contrast toxicity, insufficiency, failure)
- Upper extremity ischemia (only applicable for patients who have LSA-coverage as a proximal landing zone)

- Vascular access site complications (e.g., infection, pain, hematoma, pseudoaneurysm, arteriovenous fistula, dehiscence)
- Vascular injury
- Vascular spasm
- Vertebrobasilar insufficiency (only applicable for patients who have LSA-coverage as a proximal landing zone)
- Vessel obstruction (micro or macro) with transient or permanent ischemia or infarction due to device material (e.g., hydrophilic coating flaking off)

9. CLINICAL STUDIES

The Zenith Alpha 2 Thoracic Endovascular Graft implant is identical in design with the Zenith Alpha Thoracic Endovascular Graft implant, and the Zenith Alpha 2 Thoracic Endovascular Graft introduction system introduces the optional ability to flush with carbon dioxide (CO₂) in addition to saline prior to device introduction.

Nonclinical testing assessed the Zenith Alpha 2 Thoracic Endovascular Graft introduction system modifications to confirm that there is no impact to the device's safety and effectiveness; however, these modifications have not been clinically evaluated. Therefore, the clinical study data derived from the Zenith Alpha Thoracic Endovascular Graft, described herein, is representative of the

safety and effectiveness of the Zenith Alpha 2 Thoracic Endovascular Graft.

The Zenith Alpha Thoracic Endovascular Graft is indicated for the endovascular treatment of patients with aneurysms or ulcers of the descending thoracic aorta having vascular morphology suitable for endovascular repair.

The Zenith Alpha Thoracic Endovascular Graft has been the subject of several documented clinical evaluations, including two pivotal studies (one international) that evaluated the safety and effectiveness of the Zenith Alpha Thoracic Endovascular Graft in patients with thoracic aneurysm/ulcer and blunt thoracic aortic injury (BTAI), as summarized in **Table 2**. It should be noted that while the study to evaluate use of the device for the treatment of patients with BTAI initially supported approval for an indication inclusive of BTAI in September 2015, subsequent results from longer-term follow-up in combination with results from commercial use suggest an increased risk for in-graft thrombus with use of the device to treat patients with BTAI (refer to the Annual Clinical Update available at cookmedical.com for a complete summary of this information). Therefore, the indication for BTAI was removed in June 2017. Additional clinical evaluations include a continued access study for the aneurysm/ulcer indication (see **Section 9.2.1**) and a European post-market survey (see **Section 9.2.2**) to further confirm performance of a user interface modification to the introduction system (rotation handle).

Table 2 – Summary of Primary Pivotal Studies

Pivotal Study	Study Design	Objective	Number of Sites with Enrollment	Number of Patients
Aneurysm /Ulcer	Prospective, nonrandomized, single-arm, multinational (US, Japan, Germany, England, Sweden) study	To evaluate safety and effectiveness of the Zenith Alpha Thoracic Endovascular Graft for the treatment of patients with aneurysms/ulcers of the descending thoracic aorta	23	110
BTAI	Prospective, nonrandomized, noncomparative, single-arm, US multicenter study	To evaluate safety and effectiveness of the Zenith Alpha Thoracic Endovascular Graft for the treatment of BTAI	17	50

9.1 Clinical Study for the Aneurysm/Ulcer Indication (Through 2 Years)

The Zenith Alpha Thoracic Endovascular Graft clinical study was a prospective, nonrandomized, single-arm, multinational study that was conducted to evaluate the safety and effectiveness of the Zenith Alpha Thoracic Endovascular Graft for the treatment of patients with aneurysms/ulcers of the descending thoracic aorta. Patients were treated between March 17, 2010 (first US enrollment on October 1, 2010) and January 16, 2013. The data presented herein was collected on 110 patients through April 7, 2015. There were 23 investigational sites, including centers in the US (51 patients at 14 sites), Japan (43 patients at 3 sites), Germany (13 patients at 4 sites), Sweden (3 patients at 1 site), and England (1 patient at 1 site). The presenting anatomy, based on core laboratory analysis of pre-procedure imaging, was a thoracic aneurysm in 81.8% (90/110) of patients and a thoracic ulcer in 18.2% (20/110) of patients.

The pivotal study endpoints were established based on performance goals derived from the pivotal study of the previous device, the Zenith® TX2® TAA Endovascular Graft. Similar inclusion/exclusion criteria were used between the two studies. A post hoc analysis was performed comparing demographic, comorbid, and baseline anatomical characteristics between the present study and the previous Zenith TX2 TAA Endovascular Graft study used to derive the performance goals for hypothesis testing. Of the few variables that were found to be different between studies, none appeared to be relevant with respect to assessing the safety and effectiveness endpoints, thus confirming that comparing to performance goals derived from the previous study remained appropriate.

The primary safety endpoint was 30-day freedom from major adverse events (MAEs), and the performance goal was 80.6%. MAEs were defined as the following: all-cause death; Q-wave MI; cardiac event involving arrest, resuscitation, or balloon pump; ventilation >72 hours or reintubation; pulmonary

event requiring tracheostomy or chest tube; renal failure requiring permanent dialysis, hemofiltration, or kidney transplant in a patient with a normal pre-procedure serum creatinine level; bowel resection; stroke; paralysis; amputation involving more than the toes; aneurysm or vessel leak requiring reoperation; deep vein thrombosis requiring surgical or lytic therapy; pulmonary embolism involving hemodynamic instability or surgery; coagulopathy requiring surgery; or wound complication requiring return to the operating room.

The primary effectiveness endpoint was device success at 12-months. Device success at 12 months was defined as: Technical Success, with none of the following at 12 months:

- Type I or Type III endoleaks requiring re-intervention
- Aneurysm rupture or conversion to open surgical repair
- Aneurysm enlargement greater than 0.5 cm

Technical success was defined as successful access of the aneurysm site and deployment of the Zenith Alpha Thoracic Endovascular Graft in the intended location. The endovascular graft must be patent at the time of deployment completion as evidenced by intraoperative angiography. The effectiveness hypothesis of the study was that device success at 12 months met the performance goal of 80.7%.

An independent core laboratory analyzed all patient imaging. An independent clinical events committee (CEC) adjudicated all major adverse events (MAEs), including all patient deaths; additionally the CEC also adjudicated core laboratory reports of migration and device integrity loss. An independent data safety monitoring board (DSMB) monitored the clinical trial according to an established safety monitoring plan.

The study follow-up schedule (**Table 3**) consisted of both clinical and imaging (CT and X-ray) assessments at post-procedure (pre-discharge), 30 days, 6 months, 12 months, and yearly thereafter through 5 years.

Table 3 – Study Follow-Up Schedule

	Study Schedule						
	Pre-op	Intra-op	Post-Procedure	30-day	6-month	12-month	24-month ^d
Clinical exam	X		X	X	X	X	X
Blood tests	X		X	X	X	X	X
CT scan	X ^a			X ^c	X ^c	X ^c	X ^c
Thoracic x-ray				X	X	X	X
Angiography	X ^b	X					

^a It is recommended that imaging be performed within 6 months before the procedure.

^b Required only to resolve any uncertainties in anatomical measurements necessary for graft sizing.

^c MR imaging may be used for those patients experiencing renal failure or who are otherwise unable to undergo contrast-enhanced CT scan, with TEE being an additional option in the event of suboptimal MR imaging.

^d Yearly thereafter through 5 years.

At the time of the database lock for PMA (April 7, 2015), of 110 patients enrolled in the study, 90% (99/110) were eligible for follow-up at 12 months (**Table 4**). All patients were evaluable for the primary safety endpoint (freedom from MAE at 30 days). All patients were also evaluable for the primary effectiveness endpoint (12-month device success) based on a component of the composite measure having been assessed at the time of the procedure, consistent with the performance goal development. Two patients, although enrolled in the study, did not receive the device due to an inability to advance/gain access to the target treatment site. Although the primary safety and effectiveness endpoints were evaluated at 30 days and 12 months, respectively, patient data presented in this section include the final data through 2 years (730 days). **Table 4** reports the percent of follow-up data available through 2 years for the pivotal cohort.

Table 4 – Follow-Up Availability

Follow-Up Visit	Patients Eligible for Follow-Up	Percent of Data Available ^a			Adequate Imaging to Assess the Parameter ^b				Events Occurring Before Next Interval			
		Clinical Assessment	CT ^c	X-ray	Size Increase	Endleak	Migration	Fracture	Death	Conversion	LTF ^{**} /WTHD ^{***}	Not Due for Next Visit
Operative	110	100% (110/110)	NA*	NA*	NA*	NA*	NA*	NA*	0	0	0	0
30-day	110	96.4% (106/110)	105/108 (97.2%)	98/108 (90.7%)	105/108 (97.2%)	102/108 (94.4%)	NA*	105/108 (97.2%)	3	0	0	2 ^d
6-month	105	94.3% (99/105)	96/105 (91.4%)	92/105 (87.6%)	96/105 (91.4%)	91/105 (86.7%)	94/105 (89.5%)	98/105 (93.3%)	2	0	4	0
12-month	99	91.9% (91/99)	92/99 (92.9%)	84/99 (84.8%)	92/99 (92.9%)	83/99 (83.8%)	92/99 (92.9%)	92/99 (92.9%)	7	1	2	0
2-year	89	87.6% (78/89)	79/89 (88.8%)	75/89 (84.3%)	80/89 (89.9%)	76/89 (85.4%)	80/89 (89.9%)	80/89 (89.9%)	4	0	7	0

* NA: Not assessed.

** LTF^{**}/WTHD^{***}: Lost-to-follow-up and withdrawn.

^a Site-submitted data.

^b Based on core laboratory analysis.

^c Includes MRI or TEE imaging (which is allowed per protocol) when the patient is unable to receive contrast medium due to renal failure.

^d Two patients did not receive the device at the time of the implant procedure and therefore only 30-day clinical follow-up was applicable before the patients exited the study, with no further follow-up due thereafter.

Demographics and Patient Characteristics

The demographics and patient characteristics are presented in **Table 5**.

Table 5 – Demographics and Patient Characteristics

Demographic	Mean ± SD (n, range) or Percent Patients (number/total number)
Age (years)	All patients: 72.2 ± 9.8 (n=110, 42 – 92) Male: 70.7 ± 9.9 (n=64, 42 – 85) Female: 74.3 ± 9.4 (n=46, 44 – 92)
Gender	Male: 58.2% (64/110) Female: 41.8% (46/110)
Ethnicity	White: 53.6% (59/110) Hispanic or Latino: 0 Black or African American: 8.2% (9/110) American Indian or Alaska Native: 0 Asian: 38.2% (42/110) Native Hawaiian or other Pacific Islander: 0 Other: 0
Height (in)	65.3 ± 4.5 (n=110, 55.1 – 75.2)
Weight (lbs)	161.7 ± 44.3 (n=110, 79.2 – 330.0)
Body mass index	26.5 ± 6.0 (n=110, 16.4 – 50.0)

The medical history and comorbid medical conditions for the patient cohort are presented in **Table 6**.

Table 6 – Pre-Existing Comorbid Medical Conditions

Medical History		Percent Patients (number/total number)	
Cardiovascular	Myocardial infarction (MI)	12.7% (14/110)	
	Angioplasty/stent	10.0% (11/110)	
	Cardiac or thoracic surgery	16.4% (18/110)	
	Prior diagnosis of symptomatic congestive heart failure (CHF)	10.0% (11/110)	
	Angina	16.4% (18/110)	
	Prior diagnosis of arrhythmia	23.6% (26/110)	
	Hypertension	88.2% (97/110)	
	Coronary artery bypass graft	11.8% (13/110)	
	Vascular	Thromboembolic event	0.9% (1/110)
		Peripheral vascular disease	21.8% (24/110)
Symptomatic carotid disease warranting intervention		1.8% (2/110)	
Any aneurysm (other than the study lesion)		45.5% (50/110)	
Thoracic aortic aneurysm		2.7% (3/110)	
Abdominal aortic aneurysm		26.4% (29/110)	
Other aneurysm ^a		16.4% (18/110)	
Degenerative or atherosclerotic ulcer (other than the study lesion)		0.9% (1/110)	
Any dissection		9.1% (10/110) ^b	
Thoracic aortic dissection		6.4% (7/110) ^c	
Abdominal aortic dissection		0	
Other dissection ^d		2.7% (3/110)	
Thoracic trauma		3.6% (4/110) ^e	
Aortobronchial fistula		0.9% (1/110)	
Aortoesophageal fistula		0	
Bleeding diathesis or uncorrectable coagulopathy		0	
Endarterectomy		1.8% (2/110)	
Diagnosed or suspected congenital degenerative collagen disease		0	
Pulmonary		Chronic obstructive pulmonary disease (COPD)	25.5% (28/110)
		Home oxygen	1.8% (2/110)
Renal	Chronic renal failure	10.0% (11/110)	
	Hemodialysis	1.8% (2/110)	
	Chronic peritoneal dialysis	0	
Endocrine	Diabetes	19.1% (21/110)	
	Hypercholesterolemia	73.6% (81/110)	
Infectious disease	Systemic infection	0	
Gastrointestinal	Gastrointestinal disease	34.5% (38/110)	
Hepatobiliary	Liver disease	112.7% (14/110)	
Neoplasms	Cancer	24.5% (27/110)	
Neurologic	Stroke	10.9% (12/110)	
Substance use	Past or current smoker	71.8% (79/110)	
Allergies	Allergies	41.8% (46/110)	

^a The "other" aneurysm category includes patients with aneurysms in different locations (i.e., not descending thoracic or abdominal aorta) and patients with aneurysms in multiple locations.

^b All patients had a history of aortic dissection but at the time of enrollment had no radiographic evidence of aortic dissection.

^c The treated aneurysm/ulcer was located in the same aortic segment as the previously diagnosed dissection in four patients.

^d The "other" dissection category includes patients with dissection in different locations (i.e., not descending thoracic or abdominal aorta) and patients with dissections in multiple locations.

^e All patients had a history (>1 year) of traumatic thoracic injury.

Table 7 reports the ASA classification.

Table 7 – ASA Physical Status Classification

ASA Classification	Percent Patients (number/total number)
Healthy patient (1)	8.2% (9/110)
Mild systemic disease (2)	55.5% (61/110)
Severe systemic disease (3)	26.4% (29/110)
Incapacitating systemic disease (4)	10.0% (11/110)
Moribund patient (5)	0

Table 8 reports the SVS-ISCVS risk score.

Table 8 – SVS-ISCVS Risk Score Classification

SVS-ISCVS Category		Percent Patients (number/total number)
Diabetes risk score	0	82.7% (91/110)
	1	5.5% (6/110)
	2	10.0% (11/110)
	3	1.8% (2/110)
	4	0
Smoking risk score	0	47.3% (52/110)
	1	30.0% (33/110)
	2	13.6% (15/110)
	3	9.1% (10/110)
Hypertension risk score	0	11.8% (13/110)
	1	29.1% (32/110)
	2	31.8% (35/110)
	3	27.3% (30/110)
Hyperlipidemia risk score	0	26.4% (29/110)
	1	17.3% (19/110)
	2	1.8% (2/110)
	3	54.5% (60/110)
Cardiac status risk score	0	70.0% (77/110)
	1	18.2% (20/110)
	2	11.8% (13/110)
	3	0
Carotid disease risk score	0	84.5% (93/110)
	1	13.6% (15/110)
	2	0.9% (1/110)
	3	0.9% (1/110)
Renal status risk score	0	87.3% (96/110)
	1	10.9% (12/110)
	2	0
	3	1.8% (2/110)
Pulmonary status risk score	0	66.4% (73/110)
	1	26.4% (29/110)
	2	6.4% (7/110)
	3	0.9% (1/110)
Total SVS/ISCVS risk score		5.9 ± 2.6 (n=110, 1 – 14)

The majority of patients (81.8%) had fusiform aneurysms and the remaining 18.2% had penetrating atherosclerotic ulcers. Table 9 reports the presenting morphology.

Table 9 – Presenting Morphology Type per the Core Laboratory

Morphology	Percent Patients (number/total number)
Aneurysm	81.8% (90/110)
Ulcer	18.2% (20/110)

Table 10 reports presenting anatomical dimensions of the aneurysm/ulcer, the proximal and distal aortic necks, and the right and left iliac arteries.

Table 10 – Presenting Anatomical Dimensions Reported per the Core Laboratory

Measure	Mean ± SD (n, range)		
Aneurysm dimensions	Major diameter (mm)	60.9 ± 11.4 (n=90, 41 – 99)	
	Minor diameter (mm)	51.7 ± 11.1 (n=90, 30 – 92)	
	Length (mm)	113.5 ± 63.0 (n=90, 25.4 – 324.0)	
Ulcer dimensions	Ulcer depth (mm)	14.1 ± 3.7 (n=20, 8 – 25)	
	Length (mm)	34.8 ± 20.3 (n=20, 11.0 – 85.7)	
Proximal neck diameter	Left common carotid artery	Major (mm)	34.0 ± 3.0 (n=110, 24 – 42)
		Minor (mm)	31.1 ± 3.5 (n=110, 18 – 39)
20 mm distal to left common carotid artery		Major (mm)	33.3 ± 4.3 (n=110, 22 – 54)
		Minor (mm)	30.6 ± 4.3 (n=110, 20 – 49)
Distal neck diameter	20 mm proximal to celiac artery	Major (mm)	31.0 ± 5.1 (n=110, 20 – 48)
		Minor (mm)	28.9 ± 4.7 (n=110, 19 – 42)
Celiac artery		Major (mm)	29.5 ± 4.4 (n=110, 20 – 44)
		Minor (mm)	27.3 ± 3.8 (n=110, 19 – 38)
Proximal neck length	Left common carotid artery to distal part of neck (mm)	94.7 ± 57.8 (n=110, 14.4 – 276.7)	
Distal neck length	Celiac artery to proximal part of neck (mm)	105.2 ± 63.2 (n=110, 5.6 – 268.5)	
Right iliac artery diameter	Narrowest segment (mm)	6.7 ± 1.6 (n=105, 3 – 10) ^a	
Left iliac artery diameter	Narrowest segment (mm)	6.9 ± 1.8 (n=104, 0 – 11) ^a	

^a CT imaging was not always adequate for measurement of the iliac arteries.

Table 11 reports the distribution in aneurysm diameter/ulcer depth.

Table 11 – Distribution in Range of Maximum Aneurysm Diameter or Ulcer Depth per the Core Laboratory

Type	Size Range ^a	Percent Patients (number/total number)
Aneurysm	40 mm – <50 mm	8.9% (8/90)
	50 mm – <60 mm	40.0% (36/90)
	60 mm – <70 mm	36.7% (33/90)
	70 mm – <80 mm	6.7% (6/90)
	80 mm – <90 mm	4.4% (4/90)
	90 mm – <100 mm	3.3% (3/90)
Ulcer	<20 mm	95.0% (19/20)
	20 mm – <30 mm	5.0% (1/20)
	30 mm – <40 mm	0
	40 mm – <50 mm	0
	50 mm – <60 mm	0
	60 mm – <70 mm	0
	70 mm – <80 mm	0

^a Diameter for aneurysms and depth for ulcers.

Table 12 provides the distribution in location of the aneurysm/ulcer.

Table 12 – Location of the Primary Aneurysm/Ulcer as Determined by the Core Laboratory

Location	Percent Patients (number/total number)
Location in the thoracic aorta	
Proximal	30.0% (33/110)
Middle	50.0% (55/110)
Distal	20.0% (22/110)

Procedural Information

The majority (71.8%) of procedures were performed under general anesthesia, followed by local anesthesia in 21.8% of procedures. Vascular access was gained via femoral artery cutdown in 62.7% of patients, percutaneously in 36.4% of patients and by using a conduit in 0.9% of patients. The mean procedure time was 99.4 ± 53.6 minutes (range 31–362 minutes) and the mean procedural blood loss was 121.8 ± 137.7 ml. The mean anesthesia time was 162.6 ± 61.3 minutes and the mean fluoroscopy time was 20.0 ± 20.1 minutes.

Adjunctive procedures for spinal cord protection to prevent paraplegia were performed in 40.0% of patients (72.7% of the adjunctive procedures were cerebral spinal fluid (CSF) drainage), and induced hypotension to ease deployment was performed in 7.3% of patients. The left subclavian artery (LSA) was covered completely in 13% of patients. No LCCA to LSA bypass or LSA transposition was performed.

The access method used to insert the Zenith Alpha Thoracic Endovascular Graft is presented in Table 13. Three types of methods were used: percutaneous (direct needle puncture of the access vessel), cutdown (surgical exposure of the access vessel), and conduit (surgical technique used to bypass prohibitive access vessels). For the percutaneous access method, the procedure time was 88.8 ± 44.7 minutes, blood loss was 128.5 ± 136.4 cc, and incidence of access site complications was 7.3%. For the cutdown/conduit access method, the procedure time was 105.4 ± 57.6 minutes, blood loss was 118.0 ± 139.3 cc, and incidence of access site complications was 5.7%. These data support the use of either method of access for the device.

Table 13 – Access Method Used to Insert the Endovascular Graft

Type	Percent Patients (number/total number)		
	Aneurysm Patients	Ulcer Patients	All Patients
Percutaneous	31.1% (28/90)	60.0% (12/20)	36.4% (40/110)
Cutdown	67.8% (61/90)	40.0% (8/20)	62.7% (69/110)
Conduit	1.1% (1/90)	0	0.9% (1/110)

The location of the graft components relative to an identified site is provided as percent of patients in Table 14.

Table 14 – Graft Location per Core Laboratory

Location	Percent Patients (number/total number)		
	Aneurysm Patients	Ulcer Patients	All Patients
Proximal aspect of graft			
Above LCCA*	0	0	0
Below LCCA*, above LSA**	9.1% (8/88)	30.0% (6/20)	13.0% (14/108)
Below LSA**	83.0% (73/88)	60.0% (12/20)	78.7% (85/108)
Unable to assess ^a	8.0% (7/88)	10.0% (2/20)	8.3% (9/108)
Distal aspect of graft			
Above celiac artery	95.5% (84/88)	90.0% (18/20)	94.4% (102/108)
Below celiac artery	0	0	0
Unable to assess ^a	4.5% (4/88)	10.0% (2/20)	5.6% (6/108)

* LCCA = left common carotid artery; ** LSA = left subclavian artery.

^a All patients had post-procedure angiography but not all imaging was adequate for core laboratory review.

Two patients required axillary-axillary bypasses prior to the index procedure (both from a Japanese site). Additional procedures performed after graft deployment included use of a vessel closure device in 26 patients, LCCA stent placement in 1 patient, LSA stent in 1 patient, LSA coil embolization in 5 patients, femoral endarterectomy in 2 patients, thrombo-endarterectomy and

patch right femoral in 1 patient, iliac artery stents in 3 patients, and chimney stent to maintain blood flow to the LCCA and LSA coil embolization in one patient. Table 15 reports additional procedures performed either before or after graft implantation.

Table 15 – Additional Procedures

Procedure	Percent Patients (number/total number)	
	Before Graft Deployment	After Graft Deployment
Left carotid artery stent	0	0.9% (1/110)
Left subclavian artery stent	0	0.9% (1/110)
Iliac artery angioplasty	0.9% (1/110)	0
Iliac artery stent	0	2.7% (3/110)
Vessel closure device	0	23.6% (26/110)
Other	1.8% (2/110) ^a	8.2% (9/110) ^b

^a Two patients from Japan (1040051 and 1040069) underwent axillary-axillary bypass prior to the index procedure.

^b Two patients (1030005 and 1030044) underwent right femoral endarterectomy after the index procedure. One patient (0465997) underwent thromboendarterectomy and patch right femoral after the index procedure. Five patients (1040023, 1040033, 1040039, 1040051, and 1040069) underwent coil embolization of the left subclavian artery after the index procedure. One patient (1040080) had a chimney stent placed to maintain blood flow to the left common carotid artery and coil embolization of the left subclavian artery after the index procedure.

The device was successfully implanted in 98.2% of patients (2 patients did not receive the device due to the inability to insert/advance the introduction system) and all patients (100%) survived the endovascular procedure. Overall, the procedural results were as expected for the treatment of patients with aneurysms or ulcers of the descending thoracic aorta.

Clinical Utility Measures

The clinical utility results are presented in **Table 16**.

Table 16 – Clinical Utility Measures

Clinical Utility Measure	Mean ± SD (n, range) ^a		
	Aneurysm	Ulcer	All Patients
Duration of ICU stay (days)	2.6 ± 9.9 (n=88, 0 – 91)	0.8 ± 0.6 (n=20, 0 – 2)	2.3 ± 8.9 (n=108, 0 – 91)
Days to resumption of oral fluid intake	0.4 ± 0.6 (n=89, 0 – 3)	0.5 ± 0.8 (n=20, 0 – 3)	0.4 ± 0.6 (n=109, 0 – 3)
Days to resumption of regular diet	1.3 ± 1.1 (n=89, 0 – 6)	1.5 ± 3.1 (n=19, 0 – 14)	1.3 ± 1.6 (n=108, 0 – 14)
Days to resumption of bowel function	2.3 ± 1.5 (n=70, 0 – 8)	2.0 ± 2.1 (n=15, 0 – 8)	2.3 ± 1.6 (n=85, 0 – 8)
Days to ambulation	1.6 ± 1.3 (n=88, 0 – 9)	1.8 ± 2.2 (n=20, 0 – 10)	1.6 ± 1.5 (n=108, 0 – 10)
Days to hospital discharge	7.4 ± 19.6 (n=90, 1 – 185)	5.0 ± 5.3 (n=20, 1 – 19)	7.0 ± 17.8 (n=110, 1 – 185)

^a Not all clinical utility measures were assessed for all 110 patients.

Devices Implanted

Table 17 shows the percent of patients who received each type of Zenith Alpha Thoracic Endovascular Graft component (proximal, distal, or distal extension) during the initial implant procedure. Also included is the graft diameter range implanted for each component type.

Table 17 – Stent Graft Component Type Deployed

Type	Percent Patients (number/total number) ^a			Graft Diameter Range (All Patients)
	Aneurysm Patients	Ulcer Patients	All patients	
Proximal component (nontapered or tapered)	100% (88/88)	100% (20/20)	100% (108/108)	28 to 46 mm
Distal component	37.5% (33/88)	0	30.6% (33/108)	32 to 46 mm
Ancillary component	27.3% (24/88) ^b	5.0% (1/20)	23.1% (25/108)	28 to 46 mm
Additional proximal component	13.6% (12/88)	5.0% (1/20)	12.0% (13/108)	
Distal extension	14.8% (13/88) ^c	0	12.0% (13/108)	

^a Two aneurysm patients did not receive a device as the introduction system could not be successfully advanced; therefore, the denominator is 108, not 110.

^b One patient received both an additional proximal component and a distal extension.

^c Includes 12 patients who received 1 distal extension, and 1 patient who received 2 distal extensions.

Table 18 further summarizes the total number of components placed during the initial implant procedure.

Table 18 – Total Number of Components Placed During the Initial Implant Procedure

Main Body Design	Percent Patients (number/total number) ^a	Percent Patients (number/total number)			
		1	2	3	
One-piece (proximal only)	Aneurysm Patients	62.5% (55/88)	69.1% (38/55)	29.1% (16/55)	1.8% (1/55)
	Ulcer Patients	100% (20/20)	95.0% (19/20)	5.0% (1/20)	0
	All Patients	69.4% (75/108)	76.0% (57/75)	22.7% (17/75)	1.3% (1/75)
Two-piece (proximal and distal)	Aneurysm Patients	37.5% (33/88)	N/A	78.8% (26/33)	21.2% (7/33)
	Ulcer Patients	N/A	N/A	N/A	N/A
	All Patients	30.6% (33/108)	N/A	78.8% (26/33)	21.2% (7/33)

^a Two aneurysm patients did not receive a device as the introduction system could not be successfully advanced; therefore, the denominator is 108, not 110.

Table 19 reports the sizes (diameters and lengths) of the nontapered proximal components used during the initial implant procedure.

Table 19 – Diameters and Lengths of Nontapered Proximal Component (ZTLP-P) Sizes Used

Diameter (mm)	Length (mm)	n
28	132	2
	155	2
30	132	8
	155	2
32	132	7
	155	4
	201	5
34	137	3
	161	6
	209	2
	137	10
36	161	6
	209	1
	142	7
38	167	3
	217	6
	142	2
40	167	3
	217	1
42	121	3
	173	4
44	125	2
	233	1
46	179	4

Table 20 reports the sizes (diameters and lengths) of the tapered proximal components used during the initial implant procedure.

Table 20 – Diameters and Lengths of Tapered Proximal Component (ZTLP-PT) Sizes Used

Diameter (mm)	Length (mm)	n
34	161	4
	209	1
36	161	7
	209	4
38	167	1
	217	3
42	173	5
44	179	1
46	179	1

Table 23 – Results from Primary Safety Hypothesis Testing (MAE endpoint)

Performance Goal	30-day Freedom from MAE Rate	P-value	95% Confidence Interval	Performance Goal Met
80.6%	96.4% (106/110)	<0.001	(91%, 99%)	Yes

The 30-day freedom from MAE rate was 96.4% for the present study, which met the performance goal of 80.6% ($p < 0.001$). Four patients experienced MAEs: 1 patient had a stroke (1040045), 2 patients required ventilation >72 hours/reintubation (1030062, 1030041), and 1 patient had a stroke and required ventilation >72 hours/reintubation (1040069).

Death, Rupture, Conversion and MAE

Table 24 provides the results from Kaplan-Meier analysis for freedom from death (all-cause and TAA-related), rupture, conversion and MAEs through 2 years. Aneurysm-related mortality was defined as death occurring within 30 days of the initial implant procedure or a secondary intervention, or any death adjudicated to be aneurysm-related by the CEC. There has been one TAA-related death (1040069) that occurred at 253 days post-procedure due to aspiration pneumonia, which the CEC had indicated was likely related to the severely debilitating stroke that the patient had suffered on the same day as the procedure. There has been one conversion to open surgical repair (1040073), which occurred at 330 days post-procedure due to aorto-esophageal fistula and was adjudicated by the CEC as TAA-related.

Table 21 reports the sizes (diameters and lengths) of the distal components used during the initial implant procedure.

Table 21 – Diameters and Lengths of Distal Component (ZTLP-D) Sizes Used

Diameter (mm)	Length (mm)	n
32	160	4
	229	1
34	142	2
	190	1
36	142	3
	190	1
38	147	4
	197	5
40	147	1
42	152	6
44	157	3
46	157	2

Table 22 reports the sizes (diameters and lengths) of the ancillary components used during the initial implant procedure.

Table 22 – Diameters and Lengths of Ancillary Component Sizes Used

Diameter (mm)	Length (mm)	n
28	108	1
32	108	2
34	112	2
36	112	1
38	91	4
42	94	3
46	97	1

Safety Results

The analysis of safety was based on the 110 patients enrolled in the Zenith Alpha Thoracic Endovascular Graft pivotal study for the treatment of aneurysms/ulcers of the descending thoracic aorta. **Table 23** presents the results of hypothesis testing for the primary safety endpoint (30-day freedom from MAEs). MAEs were defined as the following: all-cause death; Q-wave myocardial infarction; cardiac event involving arrest, resuscitation, or balloon pump; ventilation >72 hours or reintubation; pulmonary event requiring tracheostomy or chest tube; renal failure requiring permanent dialysis, hemofiltration, or kidney transplant in a patient with a normal pre-procedure serum creatinine level; bowel resection; stroke; paralysis; amputation involving more than the toes; aneurysm or vessel leak requiring reoperation; deep vein thrombosis requiring surgical or lytic therapy; pulmonary embolism involving hemodynamic instability or surgery; coagulopathy requiring surgery; or wound complication requiring return to the operating room.

Table 24 – Kaplan-Meier Estimates Freedom from Death (All-Cause and TAA-Related), Rupture, Conversion, and MAEs (Through 730 Days)

Event	Parameter	30 Days			180 Days			365 Days			730 Days		
		Aneur	Ulcer	All	Aneur	Ulcer	All	Aneur	Ulcer	All	Aneur	Ulcer	All
All-cause mortality	Number at risk ^a	89	20	109	86	19	105	80	18	98	69	18	87
	Cumulative events ^b	0	0	0	2	1	3	4	1	5	11	1	12
	Cumulative censored ^c	1	0	1	2	0	2	6	1	7	10	1	11
	KM estimate ^d	1.000	1.000	1.000	0.977	0.950	0.972	0.954	0.950	0.953	0.869	0.950	0.884
	Standard error	0.000	0.000	0.000	0.016	0.049	0.016	0.023	0.049	0.021	0.037	0.049	0.032
TAA-related mortality	Number at risk ^a	89	20	109	86	19	105	80	18	98	69	18	87
	Cumulative events ^b	0	0	0	0	0	0	1 ^e	0	1	1	0	1
	Cumulative censored ^c	1	0	1	4	1	5	9	2	11	20	2	22
	KM estimate ^d	1.000	1.000	1.000	1.000	1.000	1.000	0.988	1.000	0.990	0.988	1.000	0.990
	Standard error	0.000	0.000	0.000	0.000	0.000	0.000	0.012	0.000	0.010	0.012	0.000	0.010
Rupture	Number at risk ^a	89	20	109	86	19	105	80	18	98	69	18	87
	Cumulative events ^b	0	0	0	0	0	0	0	0	0	0	0	0
	Cumulative censored ^c	1	0	1	4	1	5	10	2	12	21	2	23
	KM estimate ^d	1.000	1.000	1.000	1.000	1.000	1.000	1.000	1.000	1.000	1.000	1.000	1.000
	Standard error	0.000	0.000	0.000	0.000	0.000	0.000	0.000	0.000	0.000	0.000	0.000	0.000
Conversion	Number at risk ^a	89	20	109	86	19	105	80	18	98	69	18	87
	Cumulative events ^b	0	0	0	0	0	0	1 ^f	0	1	1	0	1
	Cumulative censored ^c	1	0	1	4	1	5	9	2	11	20	2	22
	KM estimate ^d	1.000	1.000	1.000	1.000	1.000	1.000	0.988	1.000	0.990	0.988	1.000	0.990
	Standard error	0.000	0.000	0.000	0.000	0.000	0.000	0.012	0.000	0.010	0.012	0.000	0.010
MAE ^g	Number at risk ^a	85	20	105	81	19	100	74	18	92	60	18	78
	Cumulative events ^b	4	0	4	7	1	8	12	1	13	24	1	25
	Cumulative censored ^c	1	0	1	2	0	2	4	1	5	6	1	7
	KM estimate ^d	0.956	1.000	0.964	0.922	0.950	0.927	0.864	0.950	0.879	0.722	0.950	0.763
	Standard error	0.022	0.000	0.018	0.029	0.049	0.025	0.037	0.049	0.032	0.049	0.049	0.042

^a Number of patients at risk at the beginning of the interval.^b Total events up to and including the specific interval represents all patients who have had the event. Note, only the first event is represented in the Kaplan-Meier estimate. A patient may have multiple events in each category.^c Total censored patients up to and including the specific interval represents all patients who have met a study exit criteria or for whom data are not available at the specific interval.^d At end of interval.^e Death due to aspiration pneumonia, which the CEC adjudicated as procedure-related due to the pneumonia having likely been related to a stroke that occurred the day of procedure (1040069).^f Conversion to open repair due to aortoesophageal fistula, which was adjudicated by the CEC as TAA-related (1040073).^g MAEs were defined as the following: all-cause death; Q-wave myocardial infarction; cardiac event involving arrest, resuscitation, or balloon pump; ventilation >72 hours or reintubation; pulmonary event requiring tracheostomy or chest tube; renal failure requiring permanent dialysis, hemofiltration, or kidney transplant in a patient with a normal pre-procedure serum creatinine level; bowel resection; stroke; paralysis; amputation involving more than the toes; aneurysm or vessel leak requiring reoperation; deep vein thrombosis requiring surgical or lytic therapy; pulmonary embolism involving hemodynamic instability or surgery; coagulopathy requiring surgery; or wound complication requiring return to the operating room.**All Adverse Events****Table 25** presents the percent of patients experiencing adverse events according to organ system category.**Table 25 – Percent of Patients Experiencing Adverse Events According to Organ System Category (Through 730 Days)**

Category	Percent of Patients Experiencing Event (n/N)											
	0-30 Days			31-180 Days			181-365 Days			366-730 Days		
	Aneur	Ulcer	All	Aneur	Ulcer	All	Aneur	Ulcer	All	Aneur	Ulcer	All
Access site/incision ^a	5.6% (5/90)	5.0% (1/20)	5.5% (6/110)	3.4% (3/89)	0	2.8% (3/109)	0	0	0	0	0	0
Cardiovascular ^b	5.6% (5/90)	0	4.5% (5/110)	0	0	0	2.3% (2/86)	0	1.9% (2/105)	1.3% (1/80)	0	1.0% (1/98)
Cerebrovascular/neurological ^c	3.3% (3/90)	0	2.7% (3/110)	1.1% (1/89)	0	0.9% (1/109)	2.3% (2/86)	0	1.9% (2/105)	0	0	0
Gastrointestinal ^d	1.1% (1/90)	5.0% (1/20)	1.8% (2/110)	4.5% (4/89)	5.0% (1/20)	4.6% (5/109)	1.2% (1/86)	0	1.0% (1/105)	2.5% (2/80)	5.6% (1/18)	3.1% (3/98)
Pulmonary ^e	4.4% (4/90)	0	3.6% (4/110)	1.1% (1/89)	0	0.9% (1/109)	1.2% (1/86)	0	1.0% (1/105)	3.8% (3/80)	0	3.1% (3/98)
Renal ^f	4.4% (4/90)	0	3.6% (4/110)	4.5% (4/89)	0	3.7% (4/109)	3.5% (3/86)	0	2.9% (3/105)	2.5% (2/80)	0	2.0% (2/98)
Vascular ^g	4.4% (4/90)	0	3.6% (4/110)	2.2% (2/89)	5.0% (1/20)	2.8% (3/109)	4.7% (4/86)	0	3.8% (4/105)	10.0% (8/80)	5.6% (1/18)	9.2% (9/98)
Miscellaneous/other ^h	31.1% (28/90)	35.0% (7/20)	31.8% (35/110)	29.2% (26/89)	20.0% (4/20)	27.5% (30/109)	25.6% (22/86)	15.8% (3/19)	23.8% (25/105)	32.5% (26/80)	27.8% (5/18)	31.6% (31/98)

^a Access site/incision events included: hematoma (n=5), hernia (n=1), infection (n=2), lymph fistula (n=0), pseudoaneurysm (n=0), seroma (n=1), and wound complication requiring return to operating room (n=0).^b Cardiovascular events included: cardiac arrhythmia (n=4), cardiac arrest (n=0), cardiac ischemia (n=1), congestive heart failure (n=1), myocardial infarction (n=3), and refractory hypertension (n=0).^c Cerebrovascular/neurological events included: paralysis (n=0), paraplegia (n=0), paraparesis >30 days (n=1), spinal cord shock (n=0), transient ischemic attack (n=0), and stroke (n=5).^d Gastrointestinal events included: bleeding (n=4), bowel ischemia (n=2), infection (n=4), mesenteric ischemia (n=1), and paralytic ileus >4 days (n=0).^e Pulmonary events included: COPD (n=1), hemothorax (n=0), pleural effusion (n=1), pneumonia (n=6), pneumothorax (n=0), pulmonary edema (n=0), pulmonary embolism (n=1), and pulmonary embolism involving hemodynamic instability or surgery (n=0).^f Renal events included: renal failure (n=4), UTI (n=7), serum creatinine rise >30% above baseline resulting in a persistent value >2.0 mg/dl (n=2).^g Vascular events included: aneurysm (n=11), aortobronchial fistula (n=1), aortoesophageal fistula (n=1), aortoenteric fistula (n=0), coagulopathy (n=1), deep vein thrombosis (n=0), dissection (n=3), embolism (n=2), hematoma (n=1), pseudoaneurysm (n=1), thrombosis (n=1), and vascular injury (n=5).^h Miscellaneous/other events included: hypersensitivity/allergic reaction (n=1), multi-organ failure (n=2), sepsis (n=2), and other (n=72).

Effectiveness Results

Table 26 presents the results of hypothesis testing for the primary effectiveness endpoint (12-month device success) for the Zenith Alpha Thoracic Endovascular Graft.

Table 26 – Results from Primary Effectiveness Hypothesis Testing (Device Success Endpoint)

Performance Goal	12-month Device Success Rate	P-value	95% Confidence Interval	Performance Goal Met
80.7%	92.7% (102/110) ^a	<0.001	(86.2%, 96.8%)	Yes

^a The performance goal was originally calculated with a 365-day cutoff for inclusion of events (e.g., secondary interventions) and the results in the present study were analyzed in the same fashion for consistency such that the 12-month device success rate was 95.5% (105/110) with a 95% confidence interval (89.7%, 98.5%). However, there were 3 additional patients in the present study who had an endoleak detected at the 12 month follow-up and subsequently underwent secondary intervention >365 days after the index procedure; therefore, a conservative analysis was performed that included these 3 additional patients as failures (as shown in the table).

The 12-month device success rate was 92.7% for the present study (using the conservative analysis shown in **Table 26**), which met the performance goal of 80.7% ($p < 0.001$). There were 5 patients who did not meet the effectiveness endpoint of 12 month device success (using the original 365-day cutoff for events), as follows. Two patients (1030014, 1030098) did not receive the device due to an inability to insert/advance the introduction system and were therefore technical failures. In patient 1030014 (87-year-old white female), the introduction system became lodged at the aortic bifurcation in the right common iliac artery despite attempts to increase the diameter of the iliac artery. In patient 1030098 (73-year-old white female), the index procedure was aborted due to difficulty inserting a dilator in the left limb of a previous aneurysm repair; the previous endovascular abdominal aortic aneurysm repair made the patient a poor candidate for a conduit. Three patients (1030017, 1030046, 1040073) experienced aneurysm growth greater than 5 mm at the 12-month follow-up, one of whom (1040073) also underwent conversion to open surgical repair 330 days post-procedure due to an aortoesophageal fistula. There were 3 additional patients who had endoleak detected at 12-month follow-up and subsequently underwent secondary intervention >365 days after the index procedure (1030047, 1030072, 1030095). Sensitivity to missing data, including a worst-case analysis, was performed, and met the performance goal.

Device Performance

Table 27 presents changes in aneurysm size, as observed from the 30-day (baseline) measurement to each follow-up exam through 2 years (based on core laboratory evaluation). A total of 11 patients experienced aneurysm growth (>5 mm) at one or more follow-up time points based on core laboratory analysis

through 2 years. Additional details for these patients are provided in the footnotes under **Table 27**, which also incorporated the details beyond 2 years to assist in explaining the early-term data (through 2 years) relative to the overall outcome through the course of the study.

Aneurysm growth was associated with endoleak that was noted within 2 years in six patients (1040073, 1030047, 1030051, 1030100, 1040044, and 1040045); all underwent secondary intervention for site-reported reason of endoleak. There was no detectable endoleak in the remaining five patients with aneurysm growth within 2 years, two of whom (1040060 and 1040041) had no change in aneurysm size (<5 mm change compared to baseline) as of the last available follow-up without the need for secondary intervention. Among the three other patients with growth and no detectable endoleak within 2 years, two required secondary intervention for site-reported reason of progression of disease (1030046, who was first noted to have a distal Type I endoleak by core laboratory subsequent to the secondary intervention) or aneurysm growth (1030017), and one (1030034) had growth.

Aneurysm growth was associated with an inadequate seal zone length (i.e., length <20 mm) and/or graft undersizing in eight of the 11 patients. Each of the 11 patients with growth at one or more follow-up time points up to 2 years was initially treated for an aneurysm, often using only a proximal component (n=9), underscoring the importance of adhering to the sizing guidelines in the Instructions for Use (IFU), both in terms of component diameter as well as component type and length, which includes the use of a two-component repair (proximal and distal component) when treating aneurysms.

Table 27 – Change in Aneurysm Diameter/Ulcer Depth Based on Results from Core Laboratory Analysis (Through 2 Years)

Item	Percent Patients (number/total number)								
	Aneurysm			Ulcer			All		
	6-month	12-month	2-year	6-month	12-month	2-year	6-month	12-month	2-year
Increase (>5 mm)	4.2% (3/72) ^{a,b,c}	4.2% (3/71) ^{a,b,c,d}	14.3% (9/63) ^{a,d,e,k}	0	0	0% (0/15)	3.3% (3/90)	3.4% (3/88)	11.5% (9/78)
Decrease (>5 mm)	19.4% (14/72)	31.0% (22/71)	27.0% (17/63)	33.3% (6/18)	52.9% (9/17)	66.7% (10/15)	22.2% (20/90)	35.2% (31/88)	34.6% (27/78)
No change (≤5 mm)	76.4% (55/72)	64.8% (46/71)	58.7% (37/63)	66.7% (12/18)	47.1% (8/17)	33.3% (5/15)	74.4% (67/90)	61.4% (54/88)	53.8% (42/78)

Note: the number of patients with adequate imaging to assess for size increase reflects the number of exams in which aneurysm diameter/ulcer depth was able to be assessed at each specified time point, whereas the denominators in this table also take into account the availability of a baseline exam to which to compare.

^a Patient 1030046 – The patient was treated at the time of the index procedure with a single proximal component. A distal Type I endoleak was first noted by the core laboratory at the 5-year follow-up (**Table 43**). The patient demonstrated an increase in aneurysm size (compared to baseline) from the 6-month through 5-year follow-ups (**Table 44**). The patient underwent a secondary intervention (proximal component and distal extension placement) 594 days post-procedure for the site-reported reason of progression of disease (**Table 32**). Review of core laboratory measurements at first follow-up (relative to the location of actual graft placement) suggests graft undersizing and a proximal seal length <20 mm. The patient has since exited the study.

^b Patient 1040060 – The patient was treated at the time of the index procedure with two proximal components and one distal component. Per core laboratory evaluation, no endoleaks have been identified in this patient. The patient did not require a secondary intervention. Aneurysm size was stable at 12 months (<5 mm increase). The patient has since exited the study.

^c Patient 1040073 – The patient was treated at the time of the index procedure with a single proximal component. The patient had a Type IIb endoleak noted at the 1 month and 6 month follow-ups. The patient demonstrated an increase in aneurysm size at the 6-month and 12-month follow-ups. The patient underwent a secondary intervention (NBCA embolization) 296 days post-procedure for the site-reported reason of Type II endoleak (**Table 32**). The patient underwent conversion to open repair 330 days post-procedure (**Table 24**) and exited the study 30 days later per the protocol.

^d Patient 1030017 – The patient was treated at the time of the index procedure with a single proximal component. The patient had no evidence of detectable endoleak. The patient demonstrated an increase in aneurysm size from the 12-month through 5-year follow-ups (**Table 44**). The patient underwent a secondary intervention (distal component placement) 922 days post-procedure for the site-reported reason of aneurysm growth (**Table 40**). Review of core laboratory measurements at first follow-up (relative to the location of actual graft placement) suggests graft undersizing and a distal seal length <20 mm. The patient has since exited the study.

^e Patient 1040034 – The patient was treated at the time of the index procedure with a proximal component and a distal component. The patient did not experience endoleak but demonstrated an increase in aneurysm size at the 2-year, 4-year, and 5-year follow-ups (**Table 44**). No secondary intervention has been performed. The patient has since exited the study.

^f Patient 1030047 – The patient was treated at the time of the index procedure with a single proximal component. A distal Type I endoleak was noted at the 12-month follow-up (and again at an unscheduled CT scan 596 days post-procedure) and the 2-year follow-up (**Table 28**). The patient demonstrated an increase in aneurysm size and CEC-confirmed migration first noted at an unscheduled visit between the 1-year and 2-year follow-up (**Table 29**). The patient underwent a secondary intervention (distal extension placement) 727 days post-procedure for the site-reported reasons of persistent distal Type I endoleak and device migration (**Table 32**). No growth was noted at 3 years. Review of core laboratory measurements at first follow-up (relative to the location of actual graft placement) suggests graft undersizing as well as a distal seal length <20 mm. The patient has since exited the study due to death.

^g Patient 1030051 – The patient was treated at the time of the index procedure with a single proximal component. A distal Type I endoleak (**Table 28**) and an increase in aneurysm size were noted at the 2 year follow-up. The patient underwent a secondary intervention (proximal and distal component placement) 753 days post-procedure for the site-reported reasons of distal Type I endoleak and device migration. Review of core laboratory measurements at first follow-up (relative to the location of actual graft placement) suggests a distal seal length <20 mm as well as graft undersizing. The patient has since exited the study.

^h Patient 1030100 – The patient was treated at the time of the index procedure with a single proximal component. A Type IIb endoleak was identified at the 1-month and 6-month follow-ups and a distal Type I endoleak was identified at the 2-year follow-up (**Table 28**). The patient demonstrated an increase in aneurysm size at the 2-year, 3-year, and 4-year follow-ups (**Table 44**). The patient underwent a secondary intervention (distal extension placement) 984 days post-procedure for the site-reported reason of distal Type I endoleak (**Table 40**). Review of core laboratory measurements at first follow-up (relative to the location of actual graft placement) suggests graft undersizing. The patient has since exited the study.

ⁱ Patient 1040041 – The patient was treated at the time of the index procedure with a single proximal component. The patient did not experience endoleak but did demonstrate an increase in aneurysm size at the 2-year follow-up. Review of core laboratory measurements at first follow-up (relative to the location of actual graft placement) suggests graft undersizing as well as a distal seal length <20 mm. The patient withdrew from the study 906 days post-procedure.

^j Patient 1040044 – The patient was treated at the time of the index procedure with a single proximal component. The patient had a distal Type I endoleak (**Table 28**), an increase in aneurysm size, and CEC-confirmed migration (**Table 29**) at the 2-year follow-up visit. The patient underwent a secondary intervention (distal extension placement) 798 days post-procedure for the site-reported reasons of distal Type I endoleak and device migration (**Table 40**). Review of core laboratory measurements at first follow-up (relative to the location of the actual graft placement) suggests graft undersizing. The patient has since exited the study.

^k Patient 1040045 – The patient was treated at the time of the index procedure with a single proximal component. A distal Type I endoleak was noted at the 1-month, 6-month, 12-month, 2-year, 4-year, and 5-year follow-ups (**Table 28** and **43**). A Type IIb endoleak was also identified at the 6-month and 12-month follow-ups. The patient demonstrated an increase in aneurysm size at the 2-year through 5-year follow-ups (**Table 44**). The patient underwent a secondary intervention (distal component placement) 1827 days post-procedure for the site-reported reason of distal Type I endoleak (**Table 40**). Review of core laboratory measurements at first follow-up (relative to the location of actual graft placement) suggests a distal seal length <20 mm. The patient has since exited the study.

Endoleaks classified by type, as assessed by the core laboratory at each exam period through 2 years, are reported in **Table 28**. In total, there were seven patients found to have a Type I (distal) endoleak and two patients found to have a Type III (nonjunctional) endoleak at one or more time points, two of whom (one with Type I and one with Type III) had no evidence of the same endoleak at last available follow-up and without the patients having undergone secondary intervention. Endoleak in the other seven patients (all subsequently required secondary intervention) was associated with an inadequate seal zone length (i.e., length <20 mm) and/or graft undersizing, which occurred following aneurysm treatment with only a proximal component in six of the patients, underscoring the importance of adhering to the sizing guidelines in the IFU, both in terms of component diameter as well as component type and length, including the use

of a two-component repair (proximal and distal components) when treating aneurysms. Additional details for these patients are provided in the footnotes under **Table 28**, which also incorporated the details beyond 2 years to assist in explaining the early-term data (through 2 years) relative to the overall outcome through the course of the study.

Table 28 – Endoleak Based on Results from Core Laboratory Analysis (Through 2 Years)

Type	Percent Patients (number/total number)											
	1-month			6-month			12-month			2-years		
	Aneur	Ulcer	All	Aneur	Ulcer	All	Aneur	Ulcer	All	Aneur	Ulcer	All
Any (new only)	8.5% (7/82)	10.0% (2/20)	8.8% (9/102)	4.1% (3/73)	5.6% (1/18)	4.4% (4/91)	4.5% (3/66)	0	3.6% (3/83)	8.2% (5/61)	0	6.6% (5/76)
Any (new and persistent)	8.5% (7/82)	10.0% (2/20)	8.8% (9/102)	11.0% (8/73)	11.1% (2/18)	11.0% (10/91)	10.6% (7/66)	0	8.4% (7/83)	16.4% (10/61)	0	13.2% (10/76)
Multiple	2.4% (2/82) ^a	0	2.0% (2/102)	2.7% (2/73) ^a	0	2.2% (2/91)	1.5% (1/66)	0	1.2% (1/83)	0	0	0
Proximal Type I	0	0	0	0	0	0	0	0	0	0	0	0
Distal Type I (new and persistent)	2.4% (2/82) _{ab}	0	2.0% (2/102)	4.1% (3/73) _{abd}	0	3.3% (3/91)	4.5% (3/66) _{bd,e}	0	3.6% (3/83)	8.2% (5/61) _{b,e,g,i}	0	6.6% (5/76)
Number new	2	0	2	1	0	1	1	0	1	3	0	3
Type II	7.3% (6/82) ^a	0	5.9% (6/102)	9.6% (7/73) _{ab}	5.6% (1/18)	8.8% (8/91)	6.1% (4/66) ^{bj}	0	4.8% (4/83)	6.6% (4/61) ^j	0	5.3% (4/76)
IIa	2	0	2	1	0	1	1	0	1	2	0	2
IIb	4	0	4	5	0	5	2	0	2	2	0	2
Unknown	0	0	0	1	1	2	1	0	1	0	0	0
Type IIIb (new and persistent)	0	5.0% (1/20) ^c	1.0% (1/102)	0	5.6% (1/18) ^c	1.1% (1/91)	1.5% (1/66) ^f	0	1.2% (1/83)	0	0	0
Number new	0	1	1	0	0	0	1	0	1	0	0	0
Type IV	0	0	0	0	0	0	0	0	0	0	0	0
Unknown	1.2% (1/82)	5.0% (1/20)	2.0% (2/102)	0	0	0	0	0	0	1.6% (1/61)	0	1.3% (1/76)

Note: Type IIa = flow from subclavian, celiac, and/or anomalous vertebral arteries; Type IIb = flow from bronchial and/or intercostal arteries.

^a Patient 0463776 – The patient was treated at the time of the index procedure with a proximal component and a distal component. Distal Type I and Type IIb endoleaks were noted at the 1- and 6-month follow-ups. The endoleak type was noted as unknown at last follow-up (unscheduled follow-up at day 300); a decrease in aneurysm size was also noted at last follow-up. No secondary interventions have been performed to date and the patient has since withdrawn from the study.

^b Patient 1040045 – The patient was treated at the time of the index procedure with a single proximal component. A distal Type I endoleak was noted at the 1-month, 6-month, 12-month, 2-year, 4-year, and 5-year follow-ups (Table 43). A Type IIb endoleak was also identified at the 6-month and 12-month follow-ups. The patient also had aneurysm growth at the 2-year through 5-year follow-ups (Table 27 and 44). The patient underwent a secondary intervention (distal component placement) 1827 days post-procedure for the site-reported reason of persistent distal Type I endoleak (Table 40). Review of core laboratory measurements at first follow-up (relative to the location of actual graft placement) suggests a distal seal length <20 mm. The patient has since exited the study.

^c Patient 1040051 – The patient was treated at the time of the index procedure with a single proximal component. The Type III (nonjunctional) endoleak noted at the 1-month and 6-month follow-ups was no longer present at the 12-month follow-up. The location of the endoleak coincided with an area of prominent calcification in the aorta. No secondary interventions have been performed to date and the patient has not demonstrated an increase in ulcer size.

^d Patient 1030072 – The patient was treated at the time of the index procedure with a proximal component, a distal component, and a distal extension. A distal Type I endoleak was noted at the 6-month and 12-month follow-ups. The patient has not experienced an increase in aneurysm size. The patient underwent a secondary intervention (additional distal extension placement and balloon angioplasty) 420 days post-procedure for the site-reported reason of distal Type I endoleak (Table 32). Review of core laboratory measurements at first follow-up (relative to the location of actual graft placement) suggests graft undersizing and a distal seal length <20 mm.

^e Patient 1030047 – The patient was treated at the time of the index procedure with a single proximal component. A distal Type I endoleak was first noted at the 12-month follow-up (and again at an unscheduled CT 596 days post-procedure) and the 2-year follow-up. The patient also had aneurysm growth (Table 27) and CEC-confirmed migration first noted at the 2-year follow-up (Table 29). The patient underwent a secondary intervention (distal extension placement) 727 days post-procedure for the site-reported reasons of distal Type I endoleak and device migration (Table 32). There was no endoleak detected at the 3-year follow-up. Review of core laboratory measurements at first follow-up (relative to the location of actual graft placement) suggests graft undersizing and a distal seal length <20 mm. The patient has since exited the study due to death.

^f Patient 1030095 – The patient was treated at the time of the index procedure with a single proximal component. A Type III (nonjunctional) endoleak was noted at the 12-month follow-up. The patient has not experienced an increase in aneurysm size. The patient underwent a secondary intervention (distal component placement) 534 days post-procedure for the site-reported reason of distal Type I endoleak (Table 32). Review of core laboratory measurements at first follow-up (relative to the location of actual graft placement) in combination with the site-reported reason of secondary intervention (distal Type I, not Type III, endoleak) suggest graft undersizing. The patient has subsequently withdrawn from the study 695 days post-procedure.

^g Patient 1030051 – The patient was treated at the time of the index procedure with a single proximal component. A distal Type I endoleak was noted at the 2-year follow-up. The patient also had aneurysm growth at the 2-year follow-up (Table 27). The patient underwent a secondary intervention (proximal and distal component placement) 753 days post-procedure for the site-reported reasons of distal Type I endoleak and device migration (Table 40). Review of core laboratory measurements at first follow-up (relative to the location of actual graft placement) suggests a distal seal length <20 mm as well as graft undersizing. The patient has since exited the study.

^h Patient 1030100 – The patient was treated at the time of the index procedure with a single proximal component. A Type II endoleak was identified at the 1-month and 6-month follow-ups. A distal Type I endoleak was identified at the 2-year follow-up. The patient demonstrated an increase in aneurysm size at the 2-year, 3-year, and 4-year follow-ups (Table 27 and 44). The patient underwent a secondary intervention (distal extension placement) 984 days post-procedure for the site-reported reason of distal Type I endoleak (Table 40). Review of core laboratory measurements at first follow-up (relative to the location of actual graft placement) suggests graft undersizing. The patient has since exited the study.

ⁱ Patient 1040044 – The patient was treated at the time of the index procedure with a single proximal component. A distal Type I endoleak was identified at the 2-year follow-up. The patient also had aneurysm growth (Table 27) and CEC-confirmed migration (Table 29) at the 2-year follow-up visit. The patient underwent a secondary intervention (distal extension placement) 798 days post-procedure for the site-reported reasons of distal Type I endoleak and device migration (Table 40). Review of core laboratory measurements at first follow-up (relative to the location of the actual graft placement) suggests graft undersizing. The patient has since exited the study.

^j Patient 1040036 – The patient was treated at the time of the index procedure with a single proximal component. A Type IIa endoleak was noted at the 12-month, 2-year, and 3-year follow-ups (Table 28 and 43). Lengthening of the distal aorta and an increase in aneurysm diameter from 59 mm at the 1-month follow-up to 63 mm at the 3-year follow-up was also noted, likely owing to the distal Type I endoleak (and aneurysm growth) subsequently noted at the 4-year and 5-year follow-ups (Table 44). This patient also underwent pre-planned endovascular treatment of an AAA 46 days post-procedure. The patient has since exited the study.

The results for migration through 2 years, as confirmed by the CEC, are provided in Table 29. There were three cases of CEC-confirmed migration (two also with aneurysm growth, distal Type I endoleak, and the need for secondary intervention), each of which was associated with an inadequate seal zone length (i.e., length <20 mm) and/or graft undersizing and occurred following aneurysm

treatment with only a proximal component, underscoring the importance of adhering to the sizing guidelines in the IFU, both in terms of component diameter as well as component type and length, including the use of a two-component repair (proximal and distal components) when treating aneurysms.

Table 29 – Percent of Patients (Aneurysm and Ulcer) with CEC-Confirmed Migration (Date of First Occurrence) (Through 2 Years)

Item	Percent Patients (number/total number)		
	6-month	12-month	2-year
Migration (>10 mm)	0% (0/98)	0% (0/92)	3.8% (3/80) ^{abc}

^a Patient 1030012 – The patient was treated at the time of the index procedure with a single proximal component. The patient had cranial migration of the distal end of the proximal component first confirmed by the CEC at 2 years. There was no evidence of endoleak, and the aneurysm size has continuously decreased from 61 mm at 1 month to 40 mm at 2 years and 38 mm at 3 years. Review of core laboratory measurements at first follow-up (relative to the location of actual graft placement) suggests graft undersizing. The patient has since exited the study.

^b Patient 1030047 – The patient was treated at the time of the index procedure with a single proximal component. The patient had cranial migration of the distal end of the proximal component first confirmed by the CEC at an unscheduled visit between the 1-year and 2-year follow-ups. The patient also had aneurysm growth (Table 27), distal Type I endoleak (Table 28), and underwent a secondary intervention (distal extension placement) 727 days post-procedure for the site-reported reasons of distal Type I endoleak and device migration (Table 32). Review of core laboratory measurements at first follow-up (relative to the location of actual graft placement) suggests graft undersizing and a distal seal length <20 mm. The patient has since exited the study due to death.

^c Patient 1040044 – The patient was treated at the time of the index procedure with a single proximal component. The patient had cranial migration of the distal end of the proximal component first confirmed by the CEC at 2 years. The patient also had aneurysm growth (Table 27), a distal Type I endoleak (Table 28), and underwent a secondary intervention (distal extension placement) 798 days post-procedure for the site-reported reasons of distal Type I endoleak and device migration (Table 40). Review of core laboratory measurements at first follow-up (relative to the location of the actual graft placement) suggests graft undersizing. The patient has since exited the study.

The results from core laboratory analysis for graft kink/compression through 2 years are summarized in **Table 30**.

Table 30 – Core Laboratory Reports of Graft Kink/Compression (Through 2 Years)

Item	30-day	6-month	12-month	2-year
Kink/compression	0	0	0	1.3% (1/80) ^a

^a Patient 0468761 – The patient had a kink in the proximal and distal components identified by the core laboratory on the 2-year CT scan. There were no clinical sequelae associated with the kink; at the 2-year follow-up, the aneurysm had decreased in size and the device was patent. The patient died prior to the next follow-up visit.

CEC-confirmed device integrity observations at each exam period through 2 years are summarized in **Table 31**.

Table 31 – CEC-Confirmed Loss of Device Integrity (Through 2 Years)

Finding	Percent Patients (number/total number)											
	30-day			6-month			12-month			2-years		
	Aneur	Ulcer	All	Aneur	Ulcer	All	Aneur	Ulcer	All	Aneur	Ulcer	All
Barb separation	0	0	0	0	0	0	0	0	0	0	0	0
Stent fracture	1.2% (1/85) ^a	0	1.0% (1/105)	1.3% (1/80) ^a	0	1.0% (1/98)	1.3% (1/75) ^a	0	1.1% (1/92)	1.5% (1/65) ^a	0	1.3% (1/80)
Component separation	0	0	0	0	0	0	0	0	0	0	0	0

^a Patient 1030069 – Patient had a report of a single stent fracture (of the second covered stent in the proximal device) seen on the 30-day, 6-month, 12-month and 2-year x-rays. Nothing uncharacteristic regarding the anatomy or deployment of the graft was observed. This patient has had no clinical sequelae from the stent fracture. The patient withdrew from the study 1153 days post-procedure.

Tables 32 and 33 summarize the site-reported reasons for secondary intervention and types of secondary intervention, respectively.

Table 32 – Site-Reported Reasons for Secondary Intervention (All Patients) (Through 730 Days)

Reason	0-30 Days	31-180 Days	181-365 Days	366-730 Days
Device migration	0	0	0	1 ^a
Endoleak				
Type I proximal	0	0	0	0
Type I distal	0	0	0	3 ^{d,g,h}
Type II	0	0	1 ^b	0
Type III (graft overlap joint)	0	0	0	0
Type III (hole/tear in graft)	0	0	0	0
Type IV (through graft body)	0	0	0	1 ⁱ
Unknown	0	0	0	0
Other	1 ^a	0	1 ^c	2 ^{e,f}

^a Patient 1040058 (ulcer) – Patient had pre-planned left subclavian artery embolization and right-to-left subclavian artery bypass 7 days after the index procedure.

^b Patient 1040073 (aneurysm) – Patient had two separate secondary interventions for Type II endoleak: unsuccessful attempt at placing embolization coils in the intercostal artery, followed by successful direct puncture of the aneurysm with delivery of N-butyl cyanoacrylate 296 days post-procedure.

^c Patient 1040037 (aneurysm) – Patient had additional component placed for aortic dissection proximal to the study device 324 days post-procedure.

^d Patient 1030072 (aneurysm) – Patient had a persistent Type I distal endoleak treated with additional distal extension placement and balloon angioplasty 420 days post-procedure.

^e Patient 0467042 (aneurysm) – Patient had a dissection distal to the most distal stent treated with distal extension placement 433 days post-procedure.

^f Patient 1030046 (aneurysm) – Patient had observed progression of disease treated with additional proximal and distal extension placement 594 days post-procedure.

^g Patient 1030047 (aneurysm) – Patient had distal Type I endoleak and device migration treated with distal extension placement 727 days post-procedure.

^h Patient 1030095 (aneurysm) – Patient had a persistent Type I distal endoleak treated with additional distal extension placement 534 days post-procedure.

ⁱ Patient 1040054 (aneurysm) – Patient had a persistent Type IV endoleak per site analysis (unknown type endoleak per core laboratory analysis) treated with extension placement 599 days post-procedure.

Table 33 – Types of Secondary Interventions (Through 730 Days)

Type*	0-30 Days	31-180 Days	181-365 Days	366-730 Days
Percutaneous				
Ancillary component placed	0	0	1 ^b	6 ^{d,i}
Balloon angioplasty	0	0	0	1 ^d
Coil embolization	0	0	0	0
Stent	0	0	0	0
Thrombectomy	0	0	0	0
Thrombolysis	0	0	0	0
Other	0	0	1 ^b	0
Surgical				
Conversion to open repair	0	0	0	0
Surgical bypass procedure	0	0	0	0
Other	1 ^a	0	0	0
Other	0	0	1 ^c	0

* A patient may have had more than one treatment type.

^{a-i} Refer to the footnotes in **Table 32** for additional details.

Gender Subset Analysis

There was nearly an equal proportion of males (n=64, 58.2%) and females (n=46, 41.8%) enrolled in this study, allowing for further analysis of outcomes by gender. There was no significant difference in age between male (70.7 ± 9.9 years; 42–85 years) and female (74.3 ± 9.4 years; 44–92 years) patients. Furthermore, the access method used (cutdown vs. percutaneous vs. conduit) was not significantly different between male (56.3% cutdown, 43.8% percutaneous, 0% conduit) and female (71.7% cutdown, 26.1% percutaneous, 2.2% conduit) patients.

No significant differences between males and females with respect to primary safety and effectiveness endpoints were found. For the primary safety endpoint, the 30-day freedom from MAE rate was 96.9% (62/64) for males and 95.7% (44/46) for females. For the primary effectiveness endpoint, the 12-month device success rate was 96.9% (62/64) for males and 93.5% (43/46) for females. Overall, males and females treated with the Zenith Alpha Thoracic Endovascular Graft had similar outcomes, indicating the device is likely to be equally safe and effective for both males and females.

Summary

All but 2 patients received at least one proximal component, and approximately one-third of patients also received a distal component (i.e., a two-piece system), as compared to approximately two-thirds of patients in the previous study who were treated with a two-piece system. Therefore, a two-component repair was less often used in this study compared to the previous study, despite similar percentages of patients from both studies having been treated for aneurysms. The IFU for the Zenith Alpha Thoracic Endovascular Graft was therefore updated to emphasize the importance of a two-component repair when treating aneurysms given that the reports of growth, migration, and distal Type I endoleak tended to occur in only aneurysm patients who were treated using a single proximal component.

Two patients did not receive a device in this study due to an inability to

advance/gain access to the target treatment site; 2 patients also did not receive a device in the previous study for similar reasons. In patients where access was gained (n=108), all devices were deployed successfully in the intended location and all vessels were patent at the time of deployment. An access conduit was necessary for graft delivery in 0.9% of patients, and percutaneous access was used in 36.4% of patients.

There were no deaths within 30 days of endovascular repair. There was one TAA-related death within 365 days, resulting in a 99% freedom from TAA-related mortality at 1 year. There were no ruptures reported at any follow-up time period. One patient underwent conversion to open repair 330 days post-procedure due to an aortoesophageal fistula; the CEC adjudicated the event as TAA-related. The patient survived the surgical repair and investigational device explant and has since exited the study. Patients experienced adverse events in each of the organ system categories.

A total of 11 patients experienced aneurysm growth (>5 mm) at one or more follow-up time points based on core laboratory analysis through 2 years. Aneurysm growth was associated with detectable endoleak in six patients, all of whom underwent secondary intervention. There was no detectable endoleak in the remaining five patients with aneurysm growth, two of whom had no change in aneurysm size (<5 mm change compared to baseline) as of the last available follow-up without the need for secondary intervention. Among the three other patients with growth and no detectable endoleak within 2 years, two required secondary intervention. The majority of patients with aneurysm growth at one or more time points within 2 years (n=9) initially received only a single proximal component, underscoring the importance of adhering to the sizing guidelines in the Instructions for Use (IFU), both in terms of component diameter as well as component type and length, which includes the use of a two-component repair (proximal and distal component) when treating aneurysms.

The majority of endoleaks detected were Type II, and there were no proximal Type I or Type IV endoleaks at 24 months. In total, there were seven patients found to have a Type I (distal) endoleak and two patients found to have a

Type III (nonjunctional) endoleak at one or more time points, two of which (one with Type I and one with Type III) had no evidence of the same endoleak at last available follow-up and without the patients having undergone secondary intervention. Endoleak in the other seven patients (all subsequently required secondary intervention) was associated with an inadequate seal zone length (i.e., length <20 mm) and/or graft undersizing.

There were three cases of CEC-confirmed migration (two also with aneurysm growth, distal Type I endoleak, and the need for secondary intervention), each of which was associated with an inadequate seal zone length (i.e., length <20 mm) and/or graft undersizing. There was one report of loss of device integrity (a single stent fracture) within 24 months, but with no adverse clinical sequelae.

In total, nine patients required a secondary intervention within 24 months for the site reported reasons of left subclavian artery embolization with bypass (n=1), Type II endoleak (n=1), distal Type I endoleak (n=2), distal Type I endoleak and migration (n=1), Type IV endoleak (n=1), disease progression (n=1), and aortic dissection (n=2).

Both the safety (30-day freedom from MAEs) and effectiveness (12-month device success) hypotheses were met. Overall, the results provide a reasonable assurance of the safety and effectiveness of the Zenith Alpha Thoracic Endovascular Graft.

9.2 Summary of Supplemental Clinical Information

9.2.1 Continued Access – Aneurysm/Ulcer Indication (Through 2 Years)

At the completion of enrollment in the pivotal study and prior to commercial availability, the Agency approved continued access to the Zenith Alpha Thoracic Endovascular Graft to investigators under a study expansion that followed the same inclusion/exclusion criteria, follow-up schedule, definitions, and data collection as for the pivotal study. A total of 18 patients were enrolled between April 19, 2013 and January 19, 2015 (12 patients were treated with devices that were packaged in the rotational handle introduction system). The continued access portion of the study was closed to further enrollment following PMA approval by the Agency on September 15, 2015. **Table 34** reports the percent of follow-up data available through 2 years for the continued access cohort.

Table 34 – Follow-Up Availability – Continued Access (Through 2 Years)

Follow-Up Visit	Patients Eligible for Follow-Up	Percent of Data Available ^a			Adequate Imaging to Assess the Parameter ^b				Events Occurring Before Next Interval			
		Clinical Assessment	CT ^c	X-ray	Size Increase	Endoleak	Migration	Fracture	Death	Conversion	LTF ^{**} /WTHD ^{***}	Not Due for Next Visit
Operative	18	100% (18/18)	NA*	NA*	NA*	NA*	NA*	NA*	0	0	0	0
30-day	18	100% (18/18)	94.4% (17/18)	72.2% (13/18)	NA*	94.4% (17/18)	NA*	100% (18/18)	0	0	0	0
6-month	18	100% (18/18)	100% (18/18)	83.3% (15/18)	100% (18/18)	94.4% (17/18)	94.4% (17/18)	100% (18/18)	0	0	0	0
12-month	18	83.3% (15/18)	72.2% (13/18)	72.2% (13/18)	66.7% (12/18)	66.7% (12/18)	72.2% (13/18)	72.2% (13/18)	3	0	1	0
2-year	14	85.7% (12/14)	71.4% (10/14)	64.3% (9/14)	57.1% (8/14)	71.4% (10/14)	71.4% (10/14)	71.4% (10/14)	0	0	0	0

* NA: Not assessed; ** LTF/***/WTHD: Lost-to-follow-up/withdrawn.

^a Site-submitted data.

^b Based on core laboratory analysis.

^c Includes MRI or TEE imaging, which is allowed per protocol when the patient is unable to receive contrast medium.

The following provides an overview of the safety and effectiveness results for the continued access cohort through 2 years.

Mortality: There were three total deaths through 2 years. Two deaths (1030130 and 1030137) were adjudicated as procedure-related by CEC and one (1030141) was unable to be adjudicated (cause of death unknown). Additional details regarding the two TAA-related deaths are as follows: one patient (1030130) died from hemorrhagic shock 351 days post-procedure and the second patient (1030137) died from intra-abdominal bleeding 411 days post-procedure.

Secondary Intervention: One patient (103130) underwent secondary intervention 108 days post-procedure to treat a new site-reported ulcer at the distal end of the proximal component. The patient was treated with an ancillary component and was subsequently noted to have aneurysm growth as well as Type I and Type III endoleaks based on core laboratory analysis of the 6-month follow-up exam without further intervention. The patient presented to the emergency department 350 days post-procedure with hemoptysis and hematemesis and died 351 days post-procedure due to hemorrhagic shock.

Conversion to Open Surgery: There were no conversions to open repair reported through 2 years.

Major Adverse Events (MAEs): There were 5 patients with MAEs through 2 years, including: one wound complication requiring return to operating room and death (1030141), one death (1030130), one stroke (1030142), one re-intubation and death (1030137), and one aneurysm or vessel leak requiring re-operation (1030143).

Aneurysm Growth: Core laboratory-reported increases in aneurysm size (>5 mm) occurred in three patients through 2 years, each with associated endoleak. One patient (1030130) experienced an increase in aneurysm size at 6 months. This patient also had core laboratory-reported proximal Type I and Type III endoleaks at 6 months, which was subsequent to earlier reintervention involving distal extension placement for the site-reported reason of new ulcer; the patient has since died. One patient (1030141) experienced an increase in aneurysm size at 12 months. The patient also had Type IIa and Type IIb

endoleaks. The patient did not undergo a secondary intervention, and has since died. Another patient (1030136) first experienced an increase in aneurysm size at 2 years and continued to experience the increase at 3 years and 4 years. The patient also had core laboratory-reported distal Type I endoleak on subsequent scheduled follow-up imaging and underwent a secondary intervention involving additional main body component placement for the site-reported reasons of migration and distal Type I endoleak 959 days post-procedure; this patient has since died.

Endoleak: There were four patients with core laboratory-reported endoleak through 2 years, including one patient with proximal Type I and Type IIb endoleak (1030130), two patients (1030141 and 1030149) with Type II endoleak (one with IIa and IIb, one IIb), and one patient with Type IIb and unknown type endoleak (1030124) at one or more scheduled follow-up timepoints within 2 years.

Device Migration: There were no reports of CEC-confirmed migration through 2 years.

Losses of Device Integrity: No CEC-confirmed device integrity observations (barb separation or stent fracture) was identified on the exams analyzed through 2 years.

Aortic Rupture: No ruptures have been reported through 2 years.

Graft Patency: No patients have experienced occlusion through 2 years.

9.2.2 European Post-Market Survey – Delivery System with Rotational Handle

A post-market survey was implemented in Europe to gather additional supportive information regarding clinical performance of the rotation handle introduction system. Physician users in Europe were surveyed on the procedural performance of the rotation handle system beginning March 31, 2014. A total of 38 surveys were completed as of June 30, 2014. **Table 35** summarizes the survey results.

Table 35 – Results of European Post-Market Survey

Survey Question	Response Percent (number/total number)	
Did the introduction system with the rotation handle successfully retract the release-wires without the use of the alternate sequence?	Yes	100% (38/38)
	No	0
Was the alternate sequence successful in retracting the release-wires?	Yes	Not applicable
	No	Not applicable
	Not applicable	100% (38/38)
Was the graft successfully deployed in the intended location?	Yes	97.4% (37/38)
	No	2.6% (1/38) ^a
Was the graft patent at the completion of the procedure?	Yes	100% (38/38)
	No	0

^a Slight distal migration of a tapered proximal component was reported.

All grafts were successfully deployed in the intended location using the primary release sequence, as described in the IFU, with the exception of one report of a slight distal migration during deployment. The alternate release sequence, which is also described in the IFU and is intended to be used in situations in which deployment difficulties involving the handle are encountered, was not used in any case. Furthermore, all grafts were patent at the completion of the procedure and no unique findings were observed as compared to the results from the pivotal clinical studies. These results in combination with the results

from the preclinical studies and uses of the introduction system with rotation handle during continued access provide a reasonable assurance of safety and effectiveness of the modifications that were made to the user interface since the time of enrollment completion in the pivotal clinical study.

9.3 Post-Approval Study

9.3.1 Summary of the Post-Approval Study Methods

Data Source

The post-approval study for the Zenith Alpha Thoracic Endovascular Graft involved continued follow-up (through 5 years) of patients enrolled in the premarket pivotal clinical study that was described in **Sections 9.1** (for the pivotal study) and **9.2.1** (for the continued access study).

Length of Follow-Up and Follow-Up Rates

Long-term follow-up (3-5 years) availability rates for the pivotal cohort and continued access cohort are reported in **Table 36** and **Table 37**, respectively.

Table 36 – Follow-Up Availability (3-5 Years) – Pivotal Study

Follow-Up Visit	Patients Eligible for Follow-Up	Percent of Data Available ^a			Adequate Imaging to Assess the Parameter ^b				Events Occurring Before Next Interval			
		Clinical Assessment	CT ^c	X-ray	Size Increase	Endoleak	Migration	Fracture	Death	Conversion	LTF ^e /WTHD ^{**}	Not Due for Next Visit
3-year	78	93.6% (73/78)	91.0% (71/78)	84.6% (66/78)	87.2% (68/78)	80.8% (63/78)	92.3% (72/78)	92.3% (72/78)	1	0	5	0
4-year	72	93.1% (67/72)	93.1% (67/72)	91.7% (66/72)	86.1% (62/72)	83.3% (60/72)	94.4% (68/72)	94.4% (68/72)	6	0	3	0
5-year	63	90.5% (57/63)	85.7% (54/63)	84.1% (53/63)	81.0% (51/63)	69.8% (44/63)	90.5% (57/63)	90.5% (57/63)	N/A ***d	N/A ***	N/A ****e	N/A ***

* LTF/** WTHD: Lost-to-follow-up/withdrawn; *** N/A: Not applicable.

^a Site-submitted data.

^b Based on core laboratory analysis.

^c Includes MRI or TEE imaging, which is allowed per protocol when the patient is unable to receive contrast medium.

^d Two patients died >1825 days after the index procedure.

^e Four patients were lost to follow-up or withdrew >1825 days after the index procedure.

Table 37 – Follow-Up Availability (3-5 Years) – Continued Access

Follow-Up Visit	Patients Eligible for Follow-Up	Percent of Data Available ^a			Adequate Imaging to Assess the Parameter ^b				Events Occurring Before Next Interval			
		Clinical Assessment	CT ^c	X-ray	Size Increase	Endoleak	Migration	Fracture	Death	Conversion	LTF ^e /WTHD ^{**}	Not Due for Next Visit
3-year	14	78.6% (11/14)	78.6% (11/14)	57.1% (8/14)	64.3% (9/14)	71.4% (10/14)	78.6% (11/14)	78.6% (11/14)	2	0	0	0
4-year	12	91.7% (11/12)	83.3% (10/12)	83.3% (10/12)	66.7% (8/12)	66.7% (8/12)	83.3% (10/12)	83.3% (10/12)	3	0	0	0
5-year	9	77.8% (7/9)	77.8% (7/9)	77.8% (7/9)	55.6% (5/9)	77.8% (7/9)	77.8% (7/9)	77.8% (7/9)	N/A ***d	N/A ***	N/A ***	N/A ***

* LTF/** WTHD: Lost-to-follow-up/withdrawn; *** N/A: Not applicable.

^a Site-submitted data.

^b Based on core laboratory analysis.

^c Includes MRI or TEE imaging, which is allowed per protocol when the patient is unable to receive contrast medium.

^d One patient died in the 5-year window and one patient died >1825 days after the index procedure.

9.3.2 Summary of the Post-Approval Study Results

9.3.2.1 Summary of Final Safety and Effectiveness Findings from the Post-Approval Study (Long-Term Results)

This section provides the long-term results for the following endpoints for both the pivotal and continued access cohorts, as identified in the PMA approval order: the rate of adverse events such as death (all-cause), aneurysm-related mortality, secondary interventions, conversion to open surgical repair, major adverse events, endoleak, aneurysm growth, device migration, losses of device integrity, aortic rupture, and graft patency. No formal hypothesis testing was performed for the longer-term follow-up.

All-cause Death

Pivotal

Table 38 reports survival from all-cause mortality in the aneurysm and ulcer groups between 3 years (1095 days) and 5 years (1825 days). The survival from all-cause mortality at 1825 days is 75.9% for the overall cohort, 71.3% for the aneurysm group, and 95.0% for the ulcer group. One (1) additional patient died from rupture after 5 years (>1825 days), which the CEC adjudicated as unrelated.

Table 38 – Kaplan-Meier All-Cause Mortality Survival Estimates – Pivotal (3–5 Years)

Event	Parameter	1095 Days			1460 Days			1825 Days		
		Aneur	Ulcer	All	Aneur	Ulcer	All	Aneur	Ulcer	All
All-cause mortality	Number at risk ^a	60	17	77	52	16	68	46	16	62
	Cumulative events ^b	15	1	16	19	1	20	22	1	23
	Cumulative censored ^c	15	2	17	19	3	22	22	3	25
	KM estimate ^d	0.816	0.950	0.841	0.759	0.950	0.795	0.713	0.950	0.759
	Standard error	0.045	0.049	0.038	0.052	0.049	0.044	0.056	0.049	0.047

^a Number of patients at risk at the beginning of the interval.

^b Total events up to and including the specific interval represents all patients who have had the event; includes 12 deaths (11 aneurysm, 1 ulcer) within 730 days.

^c Total censored patients up to and including the specific interval represents all patients who have met a study exit criterion or for whom data are not available at the specific interval.

^d At end of interval.

Continued Access

There were 7 all-cause deaths beyond 2 years (6 patients died between 3-year and 5-year follow-up window, and 1 patient died >1825 days after the index procedure).

Aneurysm-related Mortality

Pivotal

Table 39 summarizes survival from aneurysm-related mortality in the pivotal aneurysm/ulcer study between 3 years (1095 days) and 5 years (1825 days). The survival from aneurysm-related mortality at 1825 days is 99.0% for the overall cohort, 98.8% for the aneurysm group, and 100% for the ulcer group. There has been one TAA-related death reported to date within 5 years, which

occurred within 2 years, as previously reported in **Section 9.1, Clinical Study for the Aneurysm/Ulcer Indication (Through 2 Years)**. In addition, one patient died from rupture after 5 years (>1825 days); the CEC adjudicated this death as TAA-related, noting an enlarged aneurysm and no intervention. The patient (1030050) was treated at the time of the index procedure with a single proximal component. At 504 days post-procedure, the patient underwent endovascular AAA repair for a newly diagnosed infrarenal aortic aneurysm. At 1852 days post-procedure, the patient presented with back pain and shortness of breath. Findings from CT scan were most consistent with a ruptured thoracic aortic aneurysm. The patient died in transit to the operating room for treatment 1853 days post-procedure. The site-reported cause of death was cardiac arrest.

Table 39 – Kaplan-Meier Aneurysm-Related Mortality Survival Estimates (3-5 Years)

Event	Parameter	1095 Days			1460 Days			1825 Days		
		Aneur	Ulcer	All	Aneur	Ulcer	All	Aneur	Ulcer	All
TAA-related mortality	Number at risk ^a	60	17	77	52	16	68	46	16	62
	Cumulative events ^b	1	0	1	1	0	1	1	0	1
	Cumulative censored ^c	29	3	32	37	4	41	43	4	47
	KM estimate ^d	0.988	1.000	0.990	0.988	1.000	0.990	0.988	1.000	0.990
	Standard error	0.012	0.000	0.010	0.012	0.000	0.010	0.012	0.000	0.010

^a Number of patients at risk at the beginning of the interval.

^b Total events up to and including the specific interval represents all patients who have had the event; includes 1 TAA-related death within 730 days.

^c Total censored patients up to and including the specific interval represents all patients who have met a study exit criterion or for whom data are not available at the specific interval.

^d At end of interval.

Continued Access

There were no CEC-adjudicated aneurysm-related deaths in the continued access portion of the study between 3 years and 5 years, resulting in two CEC-adjudicated aneurysm-related deaths within 5 years in total, both of which occurred within 2 years, as previously reported in **Section 9.2.1, Continued Access – Aneurysm/Ulcer Indication (Through 2 Years)**.

Secondary Interventions

Pivotal

The site-reported reasons for reintervention for pivotal cohort are provided in **Table 40**. Ten new patients underwent secondary intervention between 3 years (1095 days) and 5 years (1825 days). In total, 19 patients have undergone a secondary intervention through 5 years; 11 secondary interventions occurred in patients with core laboratory-observed growth of the treated aneurysm.

Table 40 – Site-Reported Reasons for Secondary Intervention (3-5 Years)

Reason	731-1095 Days	1096-1460 Days	1461-1825 Days	>1825 Days
Device migration	2 ^{a,b}	0	0	0
Endoleak	Type I proximal	0	0	1 ^g
	Type I distal	4 ^{a-d}	1 ^f	0
	Type II	0	0	0
	Type IV (through graft body)	0	0	1 ^h
		0	0	0
Other	1 ^e	0	0	1 ⁱ

^a Patient 1030051 (aneurysm) – The patient had persistent distal Type I endoleak and device migration treated with proximal component and distal extension placement 753 days post-procedure.

^b Patient 1040044 (aneurysm) – The patient had persistent distal Type I endoleak and device migration (confirmed by the CEC) treated with distal extension placement 798 days post-procedure.

^c Patient 1030100 (aneurysm) – The patient had persistent distal Type I endoleak treated with additional distal extension placement 984 days post-procedure.

^d Patient 1030089 (aneurysm) – The patient had persistent distal Type I endoleak. (The core laboratory confirmed endoleak on an unscheduled visit after the 2-year visit. The core laboratory was unable to confirm endoleak on the 2-year visit due to a noncontrast CT scan being performed; however, due to enlarging TAA and lack of distal seal, the core laboratory suggested that a distal Type I endoleak was inferred at the 2-year visit). The patient was treated with additional distal extension placement 990 days post-procedure.

^e Patient 1030017 (aneurysm) – The patient had aneurysm growth without evidence of endoleak treated with distal extension placement 922 days post-procedure.

^f Patient 1040024 (aneurysm) – The patient had persistent distal Type I endoleak (identified by the site during a secondary intervention); the core laboratory was unable to determine presence or absence of Type I endoleak due to an incomplete imaging angiogram) treated with additional proximal component and distal extension placement 1212 days post-procedure.

^g Patient 0467909 (aneurysm) – The patient had proximal Type I endoleak (identified by the site; the core laboratory identified a Type IIa endoleak) treated with proximal and distal extension placement 1576 days post-procedure.

^h Patient 0460145 (aneurysm) – The patient had aneurysm growth at 4 years (8 mm by site, 9 mm by core laboratory) and 5 years (10 mm by site, 12 mm by core laboratory), which the site attributed to persistent Type IV endoleak (first noted by the site at 4 years). The core laboratory did not identify any endoleaks and could not identify a cause for aneurysm growth. The patient was treated with additional stent graft placement 1719 days post-procedure.

ⁱ Patient 1040045 (aneurysm) – The patient had persistent distal Type I endoleak and an increase in aneurysm size treated with distal extension placement 1827 days post-procedure.

^j Patient 1030052 (aneurysm) – The patient had distal Type I endoleak treated with additional component placement 1862 days post-procedure.

Continued Access

Three patients underwent secondary intervention between 3 years (1095 days) and 5 years (1825 days) as follows, resulting in four total patients who required a secondary intervention through the course of the study. Secondary intervention in patient 1030136 occurred at 959 days post-procedure for the site-reported reasons of distal Type I endoleak and device migration. The patient was treated with balloon angioplasty and an additional proximal component and distal extension. The patient died 1714 days post-procedure as a result of a fall. Secondary intervention in patient 1030143 occurred 1730 days post-procedure for the site-reported reasons of device separation and Type III endoleak. The core laboratory commented that the endoleak was caused by the loss of overlap between the two devices due to aortic elongation. The patient was treated with a distal extension (above the celiac artery) and balloon angioplasty. The patient

completed the study follow-up and exited the study. The secondary intervention in patient 1030144 occurred 1930 days post-procedure for the site-reported reason of persistent proximal and distal Type I endoleak. The patient was treated with an additional proximal component, left carotid to subclavian bypass, and coil embolization. The patient completed the study follow-up and exited the study.

Conversion to Open Surgical Repair

Pivotal

Table 41 summarizes the freedom from conversion to open surgical repair in the pivotal study between 3 years (1095 days) and 5 years (1825 days). There were no new reports of conversion to open surgical repair in the pivotal cohort beyond 2 years.

Table 41 – Kaplan-Meier Estimates for Freedom from Conversion (3-5 Years)

Event	Parameter	1095 Days			1460 Days			1825 Days		
		Aneur	Ulcer	All	Aneur	Ulcer	All	Aneur	Ulcer	All
Conversion	Number at risk ^a	60	17	77	52	16	68	46	16	62
	Cumulative events ^b	1	0	1	1	0	1	1	0	1
	Cumulative censored ^c	29	3	32	37	4	41	43	4	47
	KM estimate ^d	0.988	1.000	0.990	0.988	1.000	0.990	0.988	1.000	0.990
	Standard error	0.012	0.000	0.010	0.012	0.000	0.010	0.012	0.000	0.010

^a Number of patients at risk at the beginning of the interval.

^b Total events up to and including the specific interval represents all patients who have had the event; includes 1 conversion within 730 days.

^c Total censored patients up to and including the specific interval represents all patients who have met a study exit criterion or for whom data are not available at the specific interval.

^d At end of interval.

Continued Access

There were no conversions to open repair reported in the continued access cohort at any timepoint.

Major Adverse Events (MAEs)

Pivotal

Table 42 shows the Kaplan-Meier estimates for freedom from MAEs between 3 years (1095 days) and 5 years (1825 days), which were defined as follows: all-cause death; Q-wave myocardial infarction; cardiac event involving arrest,

resuscitation, or balloon pump; ventilation >72 hours or reintubation; pulmonary event requiring tracheostomy or chest tube; renal failure requiring permanent dialysis, hemofiltration, or kidney transplant in a patient with a normal pre-procedure serum creatinine level; bowel resection; stroke; paralysis; amputation involving more than the toes; aneurysm or vessel leak requiring reoperation; deep vein thrombosis requiring surgical or lytic therapy; pulmonary embolism involving hemodynamic instability or surgery; coagulopathy requiring surgery; or wound complication requiring return to the operating room.

Table 42 – Kaplan-Meier Estimates for Major Adverse Events – Pivotal (3-5 Years)

Event	Parameter	1095 Days			1460 Days			1825 Days		
		Aneur	Ulcer	All	Aneur	Ulcer	All	Aneur	Ulcer	All
MAE	Number at risk ^a	49	16	65	43	15	58	20	9	29
	Cumulative events ^b	31	2	33	35	2	37	43	3	46
	Cumulative censored ^c	10	2	12	12	3	15	27	8	35
	KM estimate ^d	0.634	0.894	0.681	0.581	0.894	0.638	0.470	0.835	0.537
	Standard error	0.054	0.073	0.047	0.057	0.073	0.050	0.058	0.091	0.052

^a Number of patients at risk at the beginning of the interval.

^b Total events up to and including the specific interval represents all patients who have had the event; includes 25 patients (24 aneurysm, 1 ulcer) with MAE within 730 days. Note, only the first event is represented in the Kaplan-Meier estimate. A patient may have multiple events.

^c Total censored patients up to and including the specific interval represents all patients who have met a study exit criterion or for whom data are not available at the specific interval.

^d At end of interval.

Continued Access

There were 6 new patients with MAEs between 3 years and 5 years, including 5 deaths (1 patient also with aneurysm or vessel leak requiring re-operation) and 1 patient with aneurysm or vessel leak requiring re-operation. In addition, there were 2 patients with MAEs beyond 5 years (>1825 days), including 1 death and 1 patient with persistent endoleak.

Endoleak

Pivotal

Table 43 reports the percentage of patients with endoleak (by type) based on the results from core laboratory analysis. Patients who underwent a secondary intervention for endoleak or who had associated aneurysm size increase are indicated by footnotes, as are any patients with Type I. There were 6 patients who were first noted to have a Type I endoleak between 3 years and 5 years.

In total, there were 13 patients with Type I endoleak through 5 years (all were distal Type I endoleaks, two of which were determined to be unknown endoleak types at subsequent follow-up, while nine were observed in aneurysm patients who did not receive a distal component, whereas it is recommended that aneurysm patients be treated with a proximal and distal component combination), six patients with Type IIa endoleak, eight patients with Type IIb endoleak, two patients with Type II (unknown) endoleak, two patients with Type III endoleak (both Type IIIb), and six patients with unknown endoleak type. While the focus of the post-approval study was longer-term follow-up (3-5 years), results from earlier timepoints are reproduced below in order to assist in evaluating endoleaks over time.

Table 43 – Endoleak Based on Results from Core Laboratory Analysis – Pivotal (Through 5 Years)

Type	Percent Patients (number/total number)																				
	30-day			6-month			12-month			2-year			3-year			4-year			5-year		
	Aneur	Ulcer	All	Aneur	Ulcer	All	Aneur	Ulcer	All	Aneur	Ulcer	All	Aneur	Ulcer	All	Aneur	Ulcer	All	Aneur	Ulcer	All
Any (new only)	8.5% (7/82)	10.0% (2/20)	8.8% (9/102)	4.1% (3/73)	5.6% (1/18)	4.4% (4/91)	4.5% (3/66)	0	0	3.6% (3/83)	8.2% (5/61)	6.6% (5/76)	2.0% (1/50)	0	1.6% (1/63)	8.7% (4/46)	0	6.7% (4/60)	11.8% (4/34)	10.0% (1/10)	11.4% (5/44)
Any (new and persistent)	8.5% (7/82)	10.0% (2/20)	8.8% (9/102)	11.0% (8/73)	11.1% (2/18)	11.0% (10/91)	10.6% (7/66)	0	0	8.4% (7/83)	16.4% (10/61)	13.2% (10/76)	10.0% (5/50)	0	7.9% (5/63)	19.6% (9/46)	0	15.0% (9/60)	26.5% (9/34)	10.0% (1/10)	22.7% (10/44)
Multiple	2.4% (2/82) ^a	0	2.0% (2/102)	2.7% (2/73) ^b	0	2.2% (2/91)	1.5% (1/66)	0	0	1.2% (1/83)	0	0	0	0	0	0	0	0	2.9% (1/34)	0	2.3% (1/44)
Proximal Type I	0	0	0	0	0	0	0	0	0	0	0	0	0	0	0	0	0	0	0	0	0
Distal Type I (new and persistent)	2.4% (2/82) ^{a,b}	0	2.0% (2/102)	4.1% (3/73) ^{a,b,d}	0	3.3% (3/91)	4.5% (3/66) ^{b,d,e}	0	0	3.6% (3/83)	8.2% (5/61) ^{b,e,g,h}	6.6% (5/76)	2.0% (1/50)	0	1.6% (1/63)	4.3% (2/46) ^{b,k}	0	3.3% (2/60)	17.6% (6/34) ^{b,l,m,n,o}	0	13.6% (6/44)
Number new	2	0	2	1	0	1	1	0	0	1	3	3	1	0	1	1	0	1	4	0	4
Type II	7.3% (6/82) ^a	0	5.9% (6/102)	9.6% (7/73) ^{a,b}	5.6% (1/18)	8.8% (8/91)	6.1% (4/66) ^{b,k}	0	0	4.8% (4/83)	6.6% (4/61) ^k	5.3% (4/76)	8.0% (4/50) ^k	0	6.3% (4/63)	8.7% (4/46)	0	6.7% (4/60)	8.8% (3/34)	0	6.8% (3/44)
IIa	2	0	2	1	0	1	1	0	0	1	2	2	3	0	3	1	0	3	2	0	1
IIb	4	0	4	5	0	5	2	0	0	2	0	0	0	0	1	3	0	0	1	0	2
Unknown	0	0	0	1	0	2	1	0	0	0	0	0	0	0	0	0	0	0	0	0	0
Type IIIb (new and persistent)	0	5.0% (1/20) ^c	1.0% (1/102)	0	5.6% (1/18) ^c	1.1% (1/91)	1.5% (1/66) ^f	0	0	1.2% (1/83)	0	0	0	0	0	0	0	0	0	0	0
Number new	0	1	1	0	0	0	1	0	1	0	0	0	0	0	0	0	0	0	0	0	0
Type IV	0	0	0	0	0	0	0	0	0	0	0	0	0	0	0	0	0	0	0	0	0
Unknown	1.2% (1/82)	5.0% (1/20)	2.0% (2/102)	0	0	0	0	0	0	1.6% (1/61)	0	1.3% (1/76)	0	0	0	6.5% (3/46) ^g	0	5.0% (3/60)	2.9% (1/34)	10.0% (1/10)	4.5% (2/44)

Note: Type IIa = flow from subclavian, celiac, and/or anomalous vertebral arteries; Type IIb = flow from bronchial and/or intercostal arteries.

^a Patient 0463776 – The patient was treated at the time of the index procedure with a proximal component and a distal component. Distal Type I and Type IIb endoleaks were noted at the 1-month and 6-month follow-ups. The endoleak type was noted as unknown at the last follow-up (unscheduled follow-up 300 days post-procedure); a decrease in aneurysm size was also noted at the last follow-up. No secondary interventions were performed, and the patient has since withdrawn from the study.

^b Patient 1040045 – The patient was treated at the time of the index procedure with a single proximal component. A distal Type I endoleak was noted at the 1-month, 6-month, 12 month, 2-year, 4-year, and 5-year follow-ups. A Type IIb endoleak was also identified at the 6-month and 12-month follow-ups. The patient also had aneurysm growth at the 2-year through 5-year follow-ups (Table 27 and 44). The patient underwent a secondary intervention (distal component placement) 1827 days post-procedure for the site-reported reason of persistent distal Type I endoleak (Table 40). Review of core laboratory measurements at first follow-up (relative to the location of actual graft placement) suggests a distal seal length <20 mm. The patient has since exited the study.

^c Patient 1040051 – The patient was treated at the time of the index procedure with a single proximal component. The Type III (nonjunctional) endoleak noted at the 1-month and 6-month follow-ups was no longer present at the 12-month follow-up. The location of the endoleak coincided with an area of prominent calcification in the aorta. No secondary interventions have been performed to date and the patient has not demonstrated an increase in ulcer size.

^d Patient 1030072 – The patient was treated at the time of the index procedure with a proximal component, a distal component, and a distal extension. A distal Type I endoleak was noted at the 6-month and 12-month follow-ups. The patient has not experienced an increase in aneurysm size. The patient underwent a secondary intervention (additional distal extension placement and balloon angioplasty) 420 days post-procedure for the site-reported reason of distal Type I endoleak (Table 32). Review of core laboratory measurements at first follow-up (relative to the location of actual graft placement) suggests graft undersizing and a distal seal length <20 mm.

^e Patient 1030047 – The patient was treated at the time of the index procedure with a single proximal component. A distal Type I endoleak was noted at the 12-month follow-up (and again at an unscheduled CT scan 596 days post-procedure) and the 2-year follow-up. The patient also had aneurysm growth (Table 27) and CEC-confirmed migration (Table 29) first noted at an unscheduled visit between the 1-year and 2-year follow-ups. The patient underwent a secondary intervention (distal extension placement) 727 days post-procedure for the site-reported reasons of distal Type I endoleak and device migration (Table 32). There was no endoleak detected at the 3-year follow-up. Review of core laboratory measurements at first follow-up (relative to the location of actual graft placement) suggests graft undersizing and a distal seal length <20 mm. The patient has since exited the study due to death.

^f Patient 1030095 – The patient was treated at the time of the index procedure with a single proximal component. A Type III (nonjunctional) endoleak was noted at the 12-month follow-up. The patient has not experienced an increase in aneurysm size. The patient underwent a secondary intervention (distal component placement) 534 days post-procedure for the site-reported reason of distal Type I endoleak (Table 32). Review of core laboratory measurements at first follow-up (relative to the location of actual graft placement) in combination with the site-reported reason for secondary intervention (distal Type I, not Type III, endoleak) suggest graft undersizing. The patient has subsequently withdrawn from the study 695 days post-procedure.

^g Patient 1030051 – The patient was treated at the time of the index procedure with a single proximal component. A distal Type I endoleak was noted at the 2-year follow-up. The patient also had aneurysm growth at the 2-year follow-up (Table 27). The patient underwent a secondary intervention (proximal and distal component placement) 753 days post-procedure for the site-reported reasons of distal Type I endoleak and device migration (Table 40). Review of core laboratory measurements at first follow-up (relative to the location of actual graft placement) suggests a distal seal length <20 mm as well as graft undersizing. The patient has since exited the study.

^h Patient 1030100 – The patient was treated at the time of the index procedure with a single proximal component. A Type IIb endoleak was identified at the 1-month and 6-month follow-ups. A distal Type I endoleak was identified at the 2-year follow-up. The patient also had aneurysm growth (Table 27). The patient underwent a secondary intervention (distal extension placement) 984 days post-procedure for the site-reported reason of distal Type I endoleak (Table 40). Review of core laboratory measurements at first follow-up (relative to the location of actual graft placement) suggests graft undersizing. The patient has since exited the study.

ⁱ Patient 1040044 – The patient was treated at the time of the index procedure with a single proximal component. A distal Type I endoleak was identified at the 2-year follow-up. The patient also had aneurysm growth (Table 27) and CEC-confirmed migration (Table 29). The patient underwent a secondary intervention (distal extension placement) 798 days post-procedure for the

site-reported reasons of distal Type I endoleak and device migration (Table 40). Review of core laboratory measurements at first follow-up (relative to the location of actual graft placement) suggests graft undersizing. The patient has since exited the study.

^l Patient 1030107 – The patient was treated at the time of the index procedure with a proximal component and a distal component. A distal Type I endoleak was noted on the procedural angiogram, but was not seen on the 1-month, 6-month, 12-month, or 2-year follow-up CT scans. A distal Type I endoleak was noted on the 3-year CT scan, and an unknown type endoleak was noted on the 4-year CT scan. Review of core laboratory measurements of graft location at first follow-up (relative to the location of actual graft placement) suggests potential graft undersizing.

^m Patient 1040036 – The patient was treated at the time of the index procedure with a single proximal component. A Type IIa endoleak was noted at the 12-month, 2-year, and 3-year follow-ups. Lengthening of the distal aorta and an increase in aneurysm diameter from 59 mm at the 1-month follow-up to 63 mm at the 3-year follow-up was also noted, likely owing to the distal Type I endoleak (and aneurysm growth) subsequently noted at the 4-year and 5-year follow-ups (Table 44). This patient also underwent pre-planned endovascular treatment of an AAA 46 days post-procedure. The patient has since exited the study.

ⁿ Patient 1030022 – The patient was treated at the time of the index procedure with a single proximal component. A distal Type I endoleak was first noted by the core laboratory at the 5-year follow-up. No secondary interventions were performed, and the patient did not demonstrate an increase in aneurysm size. Review of core laboratory measurements at first follow-up (relative to the location of actual graft placement) suggests a distal seal length <20 mm and potential graft undersizing. The patient has since exited the study.

^o Patient 1030046 – The patient was treated at the time of the index procedure with a single proximal component. A distal Type I endoleak was first noted by the core laboratory at the 5-year follow-up. The patient demonstrated an increase in aneurysm size (compared to baseline) from the 6-month through 5-year follow-ups (Table 44). The patient underwent a secondary intervention (proximal and distal component placement) 594 days post-procedure for the site-reported reason of progression of disease (Table 32). Following this secondary intervention, the core laboratory noted that the distal seal zone remained tenuous at the 2-year time point. Review of core laboratory measurements at first follow-up (relative to the location of actual graft placement) suggests graft undersizing and a proximal seal length <20 mm. The patient has since exited the study.

^p Patient 1030052 – The patient was treated at the time of the index procedure with a proximal component, distal component, and distal extension. A distal Type I endoleak was first noted by the core laboratory at the 5-year follow-up; the core laboratory reported the diameter at the most distal aspect of the graft was notable for an approximate 20 mm increase from 1 month to 5 years. The patient did not demonstrate an increase in aneurysm size during the study. The patient underwent a secondary intervention (distal component placement) 1862 days post-procedure for the site-reported reason of aneurysm growth in the descending thoracic aorta distal to the originally treated segment (Table 40). The patient died of aneurysm rupture two days after the intervention, which the CEC adjudicated as not related to the device or procedure.

^q Patient 1040062 – The patient was treated at the time of the index procedure with two proximal components. A Type IIb endoleak was first noted by the core laboratory at the 1-month follow-up and at each subsequent follow-up through the 5-year follow-up, at which time the core laboratory also noted a distal Type I endoleak. The patient had demonstrated an increase in aneurysm size (compared to baseline) from the 3-year through the 5-year follow-ups (Table 44). No secondary interventions were performed. Review of core laboratory measurements of graft location at first follow-up (relative to the location of actual graft placement) suggests a distal seal length <20 mm. The patient has since exited the study.

Continued Access

There were four new patients with endoleak first noted between 3 years and 5 years (1030143, 1030136, 1030144, and 1030158), resulting in eight patients with core laboratory-reported endoleak through the course of the study.

In total, there have been five patients (1030124, 1030130, 1030136, 1030144, 1030158) with Type I endoleak (two proximal, one proximal and distal, two distal), three patients (1030124, 1030141, 1030149) with Type II endoleak (one IIa and IIb, one IIb, one subtype unknown), three patients (1030124, 1030130, 1030143) with Type III endoleak (one IIIa, two IIIb), and two patients (1030124, 1030130) with unknown type endoleak at one or more scheduled or unscheduled follow-up timepoints through 5 years.

Aneurysm Growth

Pivotal

Table 44 reports the percentage of patients with an increase (>5 mm), decrease (>5 mm), or no change (≤5 mm) in aneurysm diameter (or ulcer depth) by core laboratory analysis at each follow-up time point subsequent to 1 month, which represents baseline. While the focus of the post-approval study was longer-term follow-up (3-5 years), the results from earlier timepoints (6-month, 1- and 2-years) are reproduced below in order to demonstrate that some patients with an increase in aneurysm diameter during longer-term follow-ups were the same patients who also had an increase in aneurysm diameter at earlier timepoints. There were 9 new patients who had aneurysm growth at one or more follow-up time points between 3 years and 5 years. The first occurrence of growth was observed at 3 years in two patients, at 4 years in four patients, and at 5 years in

three patients. Additional details for these patients are provided in the footnotes under Table 44. In total, there were 20 patients who experienced aneurysm growth through 5 years.

Secondary interventions for reasons such as growth, endoleak, and/or migration have been reported by the site in 10 patients (0460145, 1030017, 1030046, 1030047, 1030051, 1030100, 1040024, 1040044, 1040045, 1040073) with core laboratory-reported aneurysm growth (one of whom had continued aneurysm growth following reintervention without evidence of endoleak); an additional patient with aneurysm growth (0467042) underwent reintervention for the site-reported reason of distal dissection. The remaining 9 patients with growth had no secondary interventions prior to exiting the study.

All patients with growth at one or more follow-up time points (n=20) were treated for an aneurysm, often without use of a distal main body component (n=17). Additionally, while the percentage of aneurysm patients enrolled in this study (81.8%) was comparable to that from the previous study for the Zenith TX2 TAA Endovascular Graft (85.6%), a proximal and distal main body component pair was used in only 37.5% of the aneurysm patients in the present study compared to nearly 70.0% of the aneurysm patients in the previous study, in which 7.0% of patients had aneurysm growth at 5 years. Therefore, the labeling for the Zenith Alpha Thoracic Endovascular Graft was specifically updated subsequent to completion of enrollment in the present study to emphasize the use of a proximal main body component and distal main body component together when treating an aneurysm in order to best ensure adequate fixation and seal proximal and distal to the aneurysm.

Table 44 – Change in Aneurysm Diameter/Ulcer Depth Based on Results from Core Laboratory Analysis – Pivotal (Through 5 Years)

Item	Percent Patients (number/total number)					
	Aneurysm					
	6-month	12-month	2-year	3-year	4-year	5-year
Increase (>5 mm)	4.2% (3/72) ^{abc}	4.2% (3/71) ^{acd}	14.3% (9/63) ^{ade-k}	11.5% (6/52) ^{adh-k-m}	23.4% (11/47) ^{adeh-k-q}	33.3% (13/39) ^{ade-k}
Decrease (>5 mm)	19.4% (14/72)	31.0% (22/71)	27.0% (17/63)	26.9% (14/52)	25.5% (12/47)	17.9% (7/39)
No change (≤5 mm)	76.4% (55/72)	64.8% (46/71)	58.7% (37/63)	61.5% (32/52)	51.1% (24/47)	48.7% (19/39)

Item	Percent Patients (number/total number)					
	Ulcer					
	6-month	12-month	2-year	3-year	4-year	5-year
Increase (>5 mm)	0% (0/18)	0% (0/17)	0% (0/15)	0% (0/13)	0% (0/13)	0% (0/11)
Decrease (>5 mm)	33.3% (6/18)	52.9% (9/17)	66.7% (10/15)	46.2% (6/13)	53.8% (7/13)	45.5% (5/11)
No change (≤5 mm)	66.7% (12/18)	47.1% (8/17)	33.3% (5/15)	53.8% (7/13)	46.2% (6/13)	54.5% (6/11)

Item	Percent Patients (number/total number)					
	All					
	6-month	12-month	2-year	3-year	4-year	5-year
Increase (>5 mm)	3.3% (3/90)	3.4% (3/88)	11.5% (9/78)	9.2% (6/65)	18.3% (11/60)	26.0% (13/50)
Decrease (>5 mm)	22.2% (20/90)	35.2% (31/88)	34.6% (27/78)	30.8% (20/65)	31.7% (19/60)	24.0% (12/50)
No change (≤5 mm)	74.4% (67/90)	61.4% (54/88)	53.8% (42/78)	60.0% (39/65)	50.0% (30/60)	50.0% (25/50)

Note: The number of patients with adequate imaging to assess for size increase reflects the number of exams in which aneurysm diameter/ulcer depth was able to be assessed at each specified time point, whereas the denominators in this table also take into account the availability of a baseline exam to which to compare.

^a Patient 1030046 – The patient was treated at the time of the index procedure with a single proximal component. A distal Type I endoleak was first noted by the core laboratory at the 5-year follow-up (Table 43). The patient demonstrated an increase in aneurysm size (compared to baseline) from the 6-month through 5-year follow-ups. The patient underwent a secondary intervention (proximal component and distal extension placement) 594 days post-procedure for the site-reported reason of progression of disease (Table 32). Review of core laboratory measurements at first follow-up (relative to the location of actual graft placement) suggests graft undersizing and a proximal seal length <20 mm. The patient has since exited the study.

^b Patient 1040060 – The patient was treated at the time of the index procedure with two proximal components and one distal component. Per core laboratory evaluation, no endoleaks have been identified in this patient. Aneurysm size was stable at 12 months (<5 mm increase). The patient did not require a secondary intervention. The patient has since exited the study.

^c Patient 1040073 – The patient was treated at the time of the index procedure with a single proximal component. The patient had a Type IIb endoleak noted at the 1-month and 6-month follow-ups. The patient demonstrated an increase in aneurysm size at the 6-month and 12-month follow-ups (Table 27). The patient underwent a secondary intervention (NBCA embolization) 296 days post-procedure for the site-reported reason of Type II endoleak (Table 32). The patient underwent conversion to open repair 330 days post-procedure (Table 24) and exited the study 30 days later per the protocol.

^d Patient 1030017 – The patient was treated at the time of the index procedure with a single proximal component. The patient had no evidence of detectable endoleak. The patient demonstrated an increase in aneurysm size from the 12-month through 5-year follow-ups. The patient underwent a secondary intervention (distal extension placement) 922 days post-procedure for the site-reported reason of aneurysm growth (Table 40). Review of core laboratory measurements at first follow-up (relative to the location of actual graft placement) suggests graft undersizing and a distal seal length <20 mm. The patient has since exited the study.

^e Patient 1040034 – The patient was treated at the time of the index procedure with a proximal component and a distal component. The patient did not experience endoleak but demonstrated an increase in aneurysm size at the 2-year, 4-year, and 5-year follow-ups. No secondary intervention has been performed and the patient has since exited the study.

^f Patient 1030047 – The patient was treated at the time of the index procedure with a single proximal component. A distal Type I endoleak was noted at the 12-month follow-up (and again at an unscheduled CT scan 596 days post-procedure) and the 2-year follow-up (Table 28). The patient demonstrated an increase in aneurysm size and CEC-confirmed migration first noted at an unscheduled visit between the 1-year and 2-year follow-ups (Table 29). The patient underwent a secondary intervention (distal extension placement) 727 days post-procedure for the site-reported reasons of persistent distal Type I endoleak and device migration (Table 32). No growth was noted at the 3-year follow-up. Review of core laboratory measurements at first follow-up (relative to the location of actual graft placement) suggests graft undersizing as well as a distal seal length <20 mm. The patient has since exited the study due to death.

^g Patient 1030051 – The patient was treated at the time of the index procedure with a single proximal component. A distal Type I endoleak (Table 28) and an increase in aneurysm size were noted at the 2-year follow-up. The patient underwent a secondary intervention (proximal and distal component placement) 753 days post-procedure for the site-reported reasons of distal Type I endoleak and device migration (Table 40). Review of core laboratory measurements at first follow-up (relative to the location of actual graft placement) suggests a distal seal length <20 mm as well as graft undersizing. The patient has since exited the study.

^h Patient 1030100 – The patient was treated at the time of the index procedure with a single proximal component. A Type IIb endoleak was identified at the 1-month and 6-month follow-ups and a distal Type I endoleak was identified at the 2-year follow-up (Table 28). The patient demonstrated an increase in aneurysm size at the 2-year, 3-year, and 4-year follow-ups. The patient underwent a secondary intervention (distal extension placement) 984 days post-procedure for the site-reported reason of distal Type I endoleak (Table 40). Review of core laboratory measurements at first follow-up (relative to the location of actual graft placement) suggests graft undersizing. The patient has since exited the study.

ⁱ Patient 1040041 – The patient was treated at the time of the index procedure with a single proximal component. The patient did not experience endoleak but did demonstrate an increase in aneurysm size at the 2-year follow-up (Table 27). Review of core laboratory measurements at first follow-up (relative to the location of actual graft placement) suggests graft undersizing as well as a distal seal length <20 mm. The patient withdrew from the study 906 days post-procedure.

¹ Patient 1040044 – The patient was treated at the time of the index procedure with a single proximal component. The patient had a distal Type I endoleak (Table 28), an increase in aneurysm size, and CEC-confirmed migration (Table 29) at the 2-year follow-up visit. The patient underwent a secondary intervention (distal extension placement) 798 days post-procedure for the site-reported reasons of distal Type I endoleak and device migration (Table 40). Review of core laboratory measurements at first follow-up (relative to the location of actual graft placement) suggests graft undersizing. The patient has since exited the study.

⁶ Patient 1040045 – The patient was treated at the time of the index procedure with a single proximal component. A distal Type I endoleak was noted at the 1-month, 6-month, 12-month, 2-year, 4-year, and 5-year follow-ups (Table 43). A Type IIb endoleak was also identified at the 6-month and 12-month follow-ups (Table 28). The patient demonstrated an increase in aneurysm size at the 2-year through 5-year follow-ups. The patient underwent a secondary intervention (distal component placement) 1827 days post-procedure for the site-reported reason of distal Type I endoleak and an increase in aneurysm size (Table 40). Review of core laboratory measurements at first follow-up (relative to the location of actual graft placement) suggests a distal seal length <20 mm. The patient has since exited the study.

¹ Patient 1040024 – The patient was treated at the time of the index procedure with a single proximal component. No endoleaks or migration were noted at any follow-up time point. The patient demonstrated an increase in aneurysm size at the 3-year, 4-year, and 5-year follow-ups. At the 6-month follow-up, the core laboratory noted that the distal seal zone was extremely short and the patient was at risk for loss of distal seal. At the 3-year follow-up, the core laboratory noted that the device was in jeopardy of losing the distal seal completely. The patient underwent a secondary intervention (additional proximal component and distal extension (Gore TAG devices) placement) 1212 days post-procedure for the site-reported reason of distal Type I endoleak (Table 40). Review of core laboratory measurements at first follow-up (relative to the location of actual graft placement) suggests a distal seal length <20 mm. The patient has since exited the study.

^m Patient 1040062 – The patient was treated at the time of the index procedure with two proximal components. A Type IIb endoleak was noted at the 1-month through 5-year follow-ups, with a distal Type I endoleak also noted at the 5-year follow-up (Table 43). At the 3-year follow-up, growth of >5 mm was noted (maximum aneurysm diameter increased by 7 mm from 68 mm at 1 month to 75 mm at 3 years). Aneurysm growth continued to be noted by the core laboratory at the 4-year and 5-year follow-ups. No secondary interventions were performed. The patient has since exited the study.

ⁿ Patient 0460145 – The patient was treated at the time of the index procedure with a single proximal component. No endoleaks or migration were noted at any follow-up time point. The patient demonstrated an increase in aneurysm size at the 4-year follow-up (8 mm by site, 9 mm by core laboratory). The core laboratory could not identify a cause for aneurysm growth. The patient underwent a secondary intervention (additional stent graft placement) 1719 days post-procedure for the site-reported reason of Type IV endoleak (first noted at 4 years) (Table 40). Review of core laboratory measurements at first follow-up (relative to the location of actual graft placement) suggests graft undersizing. The patient has since exited the study.

^o Patient 1040017 – The patient was treated at the time of the index procedure with one proximal component and two distal extensions. No endoleak or migration has been noted at any time point. The patient demonstrated an increase in aneurysm size at the 4-year and 5-year follow-ups. Review of core laboratory measurements at first follow-up (relative to the location of actual graft placement) suggests graft undersizing. The patient has since exited the study.

^p Patient 1040036 – The patient was treated at the time of the index procedure with a single proximal component. A Type IIa endoleak was noted at the 12-month, 2-year, and 3-year follow-ups (Table 43). Lengthening of the distal aorta and an increase in aneurysm diameter from 59 mm at the 1-month follow-up to 63 mm at the 3-year follow-up was also noted, likely owing to the aneurysm growth (and distal Type I endoleak) subsequently noted at the 4-year and 5-year follow-ups. This patient also underwent pre-planned endovascular treatment of an AAA 46 days post-procedure. The patient has since exited the study.

^q Patient 1040079 – The patient was treated at the time of the index procedure with two proximal components. A Type II endoleak was noted at the 6-month and 12-month follow-ups, a Type IIb endoleak was noted at the 2-year, 4-year, and 5-year follow-ups, and a Type IIa endoleak was noted at the 3-year follow-up. The patient demonstrated an increase in aneurysm size at the 4-year and 5-year follow-ups. No secondary interventions were performed. The patient has since exited the study.

^r Patient 0467042 – The patient was treated at the time of the index procedure with a proximal component, distal component, and distal extension. A Type IIb endoleak was noted at the 4-year follow-up and a Type IIa endoleak was observed at the 5-year follow-up. Aneurysm growth was noted by the core laboratory at the 5-year follow-up. The patient underwent a secondary intervention (distal extension placement) 433 days post-procedure for the site-reported reason of distal dissection (Table 32). No secondary intervention for growth was reported. The patient has since exited the study.

^s Patient 1030102 – The patient was treated at the time of the index procedure with a proximal component and a distal extension. No endoleaks have been noted at any time point. The patient demonstrated an increase in aneurysm size at the 5-year follow-up. The patient did not have a secondary intervention. Review of core laboratory measurements at first follow-up (relative to the location of actual graft placement) suggests a distal seal length <20 mm and potential undersizing. Additionally, there was less than the minimum recommended amount of overlap between components initially. The patient has since exited the study.

^t Patient 1040046 – The patient was treated at the time of the index procedure with two proximal components. No endoleaks have been noted at any time point. The patient demonstrated an increase in aneurysm size at the 5-year follow-up. No secondary interventions have been performed. Review of core laboratory measurements at first follow-up (relative to the location of actual graft placement) suggests proximal and distal graft undersizing. The patient has since exited the study.

Continued Access

Core laboratory-reported increases in aneurysm size (>5 mm) have occurred in two new patients beyond 2 years as follows, thus providing five patients total with aneurysm growth at any time point during continued access.

One patient (1030143) experienced an increase in aneurysm size at 3 years, 4 years, and 5 years. The patient also had core laboratory-reported Type III endoleaks at 4 years and underwent a secondary intervention involving ancillary component placement and balloon angioplasty for the site-reported reasons of device separation and persistent endoleak; the patient completed the study follow-up and exited the study. Another patient (1030124) experienced an increase in aneurysm size at 3 years, 4 years, and 5 years. The patient also had

core laboratory-reported Type III endoleak at 1 month; unknown type endoleak at 6 months, 12 months, and 5 years; and proximal Type I endoleak at 3 years, 4 years, and 5 years. The patient did not undergo a secondary intervention; the patient completed the study follow-up and exited the study.

Device Migration

Pivotal

There were no new reports of CEC-confirmed migration between 3 years and 5 years, as shown in Table 45, which also reproduces results from the earlier timepoints for reference.

Table 45 – Percent of Patients (Aneurysm and Ulcer) with CEC-Confirmed Migration (Date of First Occurrence) – Pivotal (Through 5 Years)

Item	Percent Patients (number/total number)					
	6-month	12-month	2-year	3-year	4-year	5-year
Migration (>10 mm)	0% (0/98)	0% (0/92)	3.8% (3/80) ^{a,b,c}	0% (0/72)	0% (0/68)	0% (0/57)

^a Patient 1030012 – The patient was treated at the time of the index procedure with a single proximal component. The patient had cranial migration of the distal end of the proximal component first confirmed by the CEC at 2 years. There was no evidence of endoleak, and the aneurysm size has continuously decreased from 61 mm at 1 month to 40 mm at 2 years and 38 mm at 3 years. Review of core laboratory measurements at first follow-up (relative to the location of actual graft placement) suggests graft undersizing. The patient has since exited the study.

^b Patient 1030047 – The patient was treated at the time of the index procedure with a single proximal component. The patient had cranial migration of the distal end of the proximal component first confirmed by the CEC at an unscheduled visit between the 1-year and 2-year follow-ups. The patient also had distal Type I endoleak (Table 28), aneurysm growth (Table 27), and underwent a secondary intervention (distal extension placement) 727 days post-procedure for the site-reported reasons of distal Type I endoleak and device migration (Table 32).

Review of core laboratory measurements at first follow-up (relative to the location of actual graft placement) suggests graft undersizing and a distal seal length <20 mm. The patient has since exited the study due to death.

^c Patient 1040044 – The patient was treated at the time of the index procedure with a single proximal component. The patient had cranial migration of the distal end of the proximal component first confirmed by the CEC at 2 years. The patient also had a distal Type I endoleak (Table 28), aneurysm growth (Table 27), and underwent a secondary intervention (distal extension placement) 798 days post-procedure for the site-reported reasons of distal Type I endoleak and device migration (Table 39). Review of core laboratory measurements at first follow-up (relative to the location of actual graft placement) suggests graft undersizing. The patient has since exited the study.

Continued Access

There was one report of CEC-confirmed migration during continued access, which occurred between 3 years and 5 years. Patient 1030158 was treated with a single proximal component for a thoracic aortic ulcer, which had resolved by the 12-month visit per both the site and core laboratory. From the 3-year follow-up CT scan, the core laboratory noted growth in the aortic diameter just below the original ulcer site. From the 4-year follow-up CT scan, the core laboratory noted continued progression of the aortic diameter to a maximum diameter of 45.8 mm. From the 5-year CT scan, the core laboratory noted a distal Type I

endoleak. Proximal (cranial) migration of the distal end of a proximal component at the 5-year time point was confirmed by the CEC.

Losses of Device Integrity

Pivotal

Table 46 reports the CEC-confirmed device integrity observations at each exam period between 3 years and 5 years, noting the only new observation during this period was a single stent fracture in one patient.

Table 46 – CEC-Confirmed Loss of Device Integrity – Pivotal (3-5 Years)

Finding	Percent Patients (number/total number)								
	3-year			4-year			5-year		
	Aneur	Ulcer	All	Aneur	Ulcer	All	Aneur	Ulcer	All
Barb separation	0	0	0	0	0	0	0	0	0
Stent fracture	1.8% (1/57) ^a	0	1.4% (1/72)	1.9% (1/52) ^a	0	1.5% (1/68)	0	0	0
Component separation	0	0	0	0	0	0	0	0	0

^a Patient 1030028 – Per the core laboratory, a single fracture of the proximal bare stent of the device was noted on the 3-year and 4-year x-rays. Nothing uncharacteristic regarding the anatomy or deployment of the graft was observed. This patient has had no clinical sequelae from the stent fracture. No secondary interventions were performed, and the patient has since exited the study.

Continued Access

There were no reports of CEC-confirmed device integrity observations (barb separation or stent fracture) between 3 years and 5 years.

Aortic Rupture

Pivotal

No ruptures have been reported in the pivotal cohort within 5 years (1825 days). Two ruptures were reported after 5 years (1030050, 1030052). Details regarding patient 1030050 were described in the Aneurysm-Related Mortality Section. Details regarding patient 1030052 are as follows: this patient with prior open repair involving the ascending and descending thoracic aorta (secondary

to giant cell aortitis) was treated at the time of the index procedure with a proximal component, distal component, and distal extension. On post-operative day 1862, the patient underwent additional thoracic graft placement due to reported growth in the descending thoracic aorta distal to the originally treated segment. Two days later, the patient died from left hemothorax due to rupture. The CEC adjudicated the death as unrelated, noting there was aneurysm growth below the endograft.

Continued Access

No ruptures have been reported in the continued access cohort.

Graft Patency

Pivotal

No patients have experienced occlusion. Throughout follow-up, there have been four patients with confirmed presence of thrombus in the graft (three in the setting of excessive graft oversizing, one in the setting of preexisting aortic neck thrombus).

Continued Access

No patients have experienced occlusion. Throughout follow-up, there have been two patients with confirmed presence of thrombus in the graft (in the setting of preexisting aortic neck thrombus).

9.3.2.2 Study Strengths and Weaknesses

The pivotal clinical study was well controlled, having been conducted in accordance with ISO 14155, 21 CFR 812, JGCP, ICH GCP, and other applicable requirements as appropriate. Additionally, the study utilized an independent core laboratory to ensure uniform analysis of pre-procedure and follow-up imaging exams.

The continued access study followed the same inclusion/exclusion criteria, follow-up schedule, definitions, and data collection as that for the pivotal study, but was not powered to test any study hypotheses.

The comorbid medical conditions of the patient population, which often resulted in death for reasons unrelated to the study aneurysm/device, limited the number of enrolled patients with completed 5-year follow-up.

10. STERILIZATION

All devices are sterilized using ethylene oxide (EO) gas.

11. HOW SUPPLIED

The ZTA2 is preloaded into an introduction system and is supplied in peel-open packages. The device is loaded into a 16 French, 18 French, or 20 French Flexor introducer sheath.

This device is accompanied by an Implant Card, that should be given to the patient after it has been completed by the Healthcare Professional.

Keep the device dry and away from sunlight. Do not use after the expiration date printed on the label.

12. INSPECTION OF DEVICE

Inspect the device thoroughly including all levels of the packaging to verify that there is no damage prior to use. Inspect and confirm that the sterile barrier has not been compromised in any way. Inspect and confirm that the device corresponds to the label and the IFU.

Do not use the device if the sterile packaging is damaged or unintentionally opened before use.

13. DEVICE PREPARATION

13.1 Preprocedure Imaging and Measuring Guidelines

- Lack of non-contrast CT imaging may result in failure to identify iliac or aortic calcification that may preclude access or reliable device fixation and seal.
- Preprocedure imaging reconstruction thickness >1 mm may result in suboptimal device sizing or in failure to identify focal stenoses from CT.
- Clinical experience indicates that contrast-enhanced spiral computed tomographic angiography (CTA) with 3D reconstruction is the strongly recommended imaging modality to accurately assess patient anatomy prior to treatment with the ZTA2. If contrast-enhanced spiral CTA with 3D reconstruction is not available, the patient should be referred to a facility with these capabilities.
- Clinicians recommend positioning the x-ray C-arm during procedural angiography so that it is perpendicular to the aortic vessel neck proximal to the thoracic aneurysm or ulcer, typically 45-75° left anterior oblique (LAO) for the arch.

- Diameter:** A contrast-enhanced spiral CTA is strongly recommended for measuring aortic diameter. Diameter measurements should be determined from the outer-wall-to-outer-wall vessel diameter and not the lumen diameter. The spiral CTA scan must include the great vessels through the femoral heads at an axial slice thickness of 1 mm or less. Clinical experience has shown that temporary changes in aortic diameter during blood loss can lead to incorrect aortic measurement on preoperative CTA, inadequate sizing, and increased risks of graft complications, migration, and endoleak. If preoperative CTA is done during hemodynamic instability, repeat CTA when the patient is stable or use IVUS at the time of the procedure to confirm diameter measurements. If there is significant periaortic hematoma in the region of the subclavian artery the hematoma should not be counted in the diameter measurement, as there is a risk of oversizing the stent graft.

- Length:** Clinical experience indicates that 3D CTA reconstruction is the strongly recommended imaging modality to accurately assess proximal and distal neck lengths for the ZTA2 stent graft. These reconstructions should be performed in sagittal, coronal, and varying oblique views depending upon individual patient anatomy. Length measurements should be taken along the greater curvature of the aorta, including the aneurysm, if present.

NOTE: The greater curvature is the longest measurement following the curve of the aneurysm and may be on the outer or inner curvature of the aorta depending on the location of the aneurysm.

NOTE: Large aneurysms and difficult anatomy may require extra care in planning.

13.2 Device Selection

- Strict adherence to the ZTA2 sizing guide both in terms of stent graft diameter (**Tables 47 and 48** in the ZTA2 Stent Graft Diameter Sizing Guidelines) as well as stent graft type/length (as stated below in the ZTA2 Stent Graft Length Sizing Guidelines) is strongly recommended in order to mitigate the risk for events (e.g., migration, endoleak, aneurysm growth) that could result from selecting inappropriate device sizes.
- Tables 47 and 48** incorporate appropriate device oversizing. Sizing outside of the recommendations provided in **Tables 47 and 48**, including that which could result from a difference in location of graft deployment relative to the location used for graft sizing, can result in aneurysm growth, endoleak, migration, fracture, device infolding, or compression.
- Cook recommends that the ZTA2 stent graft diameters be selected as described in **Tables 47 and 48**. All lengths and diameters of the stent grafts necessary to complete the procedure should be available to the physician, especially when preoperative case planning measurements (treatment diameters and lengths) are not certain. This approach allows for greater intraoperative flexibility.

13.2.1 ZTA2 Stent Graft Diameter Sizing Guidelines

The choice of diameter should be determined from the outer-wall-to-outer-wall vessel diameter and not the lumen diameter. Undersizing or oversizing may result in incomplete sealing or compromised flow. To ensure accurate diameter measurements for the purpose of stent graft sizing, particularly when in curved segments of the aorta, measure the aortic diameter using 3D reconstructed views perpendicular to the aortic centerline of flow. The proximal diameter of the distal stent graft can be up to 8 mm larger than the distal diameter of the proximal stent graft. It is strongly recommended to ensure a minimum three-stent overlap between stent grafts.

For patients with a significant periaortic hematoma in the region of the subclavian artery the hematoma should not be counted in the diameter measurement, as there is a risk of oversizing the stent graft.

A proximal neck diameter that is 4 mm or more larger than the distal neck diameter requires the use of a proximal tapered stent graft.

Table 47 – Proximal, Distal, and Proximal Tapered Stent Graft (P, D, PT) Diameter Sizing Guide*

Intended Aortic Vessel Diameter ^{1,2} mm	Graft Diameter ³ mm	Overall Length of Proximal Stent Graft mm	Overall Length of Distal Stent Graft mm	Overall Length of Tapered Proximal Stent Graft mm	Introducer Sheath Inner Diameter (ID) Fr	Introducer Sheath Outer Diameter (OD) mm
20	24	105/127**	n/a	n/a	16	6.0
21	24	105/127**	n/a	n/a	16	6.0
22	26	105	n/a	n/a	16	6.0
23	26	105	n/a	n/a	16	6.0
24	28	109/132**/155/201	160	n/a	16	6.0
25	28	109/132**/155/201	160	n/a	16	6.0
26	30	109/132**/155/201	160	108	16	6.0
27	30	109/132**/155/201	160	108	16	6.0
28	32	109/132**/155/201	160/229**	178/201	18	7.1
29	32	109/132**/155/201	160/229**	178/201	18	7.1
30	34	113/137**/161/209	142/190	161/209	18	7.1
31	36	113/137**/161/209	142/190	161/209	18	7.1
32	36	113/137**/161/209	142/190	161/209	18	7.1
33	38	117/142**/167/217	147/197	167/217	18	7.1
34	38	117/142**/167/217	147/197	167/217	18	7.1
35	40	117/142**/167/217	147/197	167/217	20	7.7
36	40	117/142**/167/217	147/197	167/217	20	7.7
37	42	121/173/225	152**/204	173/225	20	7.7
38	42	121/173/225	152**/204	173/225	20	7.7
39	44	125/152**/179/233	157**/211	179/233	20	7.7
40	46	125/179/233	157**/211	179/233	20	7.7
41	46	125/179/233	157**/211	179/233	20	7.7
42	46	125/179/233	157**/211	179/233	20	7.7

¹ Maximum diameter along the fixation site, measured outer-wall-to-outer-wall.

² Round the measured aortic diameter to the nearest mm.

³ Additional considerations may affect the choice of diameter.

* All dimensions are nominal.

** Non-stock items.

Table 48 – Distal Extension (DE) Stent Graft Diameter Sizing Guide*

Intended Aortic Vessel Diameter ^{1,2} mm	Graft Diameter ³ mm	Overall Length of Stent Graft mm	Introducer Sheath Inner Diameter (ID) Fr	Introducer Sheath Outer Diameter (OD) mm
22	26	104	16	6.0
23	26	104	16	6.0
24	28	108**	16	6.0
25	28	108**	16	6.0
26	30	108	16	6.0
27	30	108	16	6.0
28	32	108**	18	7.1
29	32	108**	18	7.1
30	34	112	18	7.1
31	36	112**	18	7.1
32	36	112**	18	7.1
33	38	91	18	7.1
34	38	91	18	7.1
37	42	94	20	7.7
38	42	94	20	7.7
40	46	97	20	7.7
41	46	97	20	7.7
42	46	97	20	7.7

¹ Maximum diameter along the fixation site, measured outer-wall-to-outer-wall.

² Round the measured aortic diameter to the nearest mm.

³ Additional considerations may affect the choice of diameter.

* All dimensions are nominal.

** Non-stock items.

13.2.2 ZTA2 Stent Graft Length Sizing Guidelines

- Stent graft length should be selected to cover the aneurysm or ulcer measured along the greater curve of the aneurysm, plus a minimum of 20 mm of seal zone on the proximal and distal ends.
- To treat more focal aortic lesions, such as ulcers/saccular aneurysms, a proximal stent graft can be used alone.
- In aneurysms the stent graft may settle into the greater curve of the aneurysm over time. Accordingly, extra stent graft length needs to be planned:
 - A two-component repair (proximal and distal stent grafts) is recommended, as it provides the ability to adapt to the length change over time. A two-component repair (proximal and distal stent grafts) also provides active fixation at both the proximal and distal seal sites.
 - The minimum required amount of overlap between stent grafts is three stents. Less than a three-stent overlap may result in endoleak (with or without stent graft separation). However, no part of the distal stent graft should overlap the proximal sealing stent of the proximal stent graft, and no part of the proximal stent graft should overlap the distal sealing stent of the distal stent graft, as doing so may cause malapposition to the vessel wall. Device lengths should be selected accordingly.
 - If an acceptable two-component (proximal and distal stent grafts) treatment plan cannot be achieved (e.g., excessive aortic coverage, even with maximal overlap of shortest stent grafts), the proximal stent graft must be selected with enough length to achieve and maintain the minimum 20 mm sealing zones at both ends even when positioned in the greater curve of the aneurysm. Clinical experience shows that failure to do so could result in migration, endoleak, and aneurysm growth.

13.2.3 Proximal and Distal Stent Graft Overlap

A minimum overlap of three stents is recommended; however, the proximal sealing stent of the proximal stent graft or distal sealing stent of the distal stent graft should not be overlapped.

13.3 Preprocedure Preparation

- Verify from preimplant planning that the correct device has been selected. Determinants include:
 - Femoral artery selection for introduction of the introduction system(s)
 - Angulation of aorta, aneurysm, and iliac arteries
 - Quality of the proximal and distal fixation sites
 - Diameters of proximal and distal fixation sites and distal iliac arteries
 - Length of proximal and distal fixation sites
- All lengths and diameters of the ZTA2 necessary to complete the procedure should be available to the physician, especially when preoperative case planning measurements (treatment diameters/lengths) are not certain. This approach allows for greater intraoperative flexibility to achieve optimal procedural outcomes.
- Clinicians recommend positioning the x-ray C-arm during procedural angiography so that it is perpendicular to the aortic vessel neck proximal to the thoracic aneurysm or ulcer, typically 45-75° left anterior oblique (LAO) for the arch.

14. INSTRUCTIONS FOR USE

14.1 Patient Preparation

- Systemic anticoagulation should be used during the implantation procedure based on hospital- and physician-preferred protocol.
- Administration of intravascular contrast media is required during the implantation procedure. Care should be taken to limit the amount of contrast media used during the procedure, and to observe preventive methods of treatment to decrease renal compromise (e.g., adequate hydration).
- If an accessory agent (e.g., heparin) required for the procedure is contraindicated an alternative agent should be used.
- Refer to institutional protocols relating to anesthesia, anticoagulation, and monitoring of vital signs.
- Position the patient on the imaging table to allow fluoroscopic visualization from the aortic arch to the femoral bifurcations.
- X-ray imaging is required for the implantation procedure and follow-up. Care should be taken to limit the radiation used during the procedure and follow-up.
- Expose the femoral artery using standard surgical technique.
- Establish adequate proximal and distal vascular control of the femoral artery.

14.2 Step-by-Step Guide

Prior to use of the ZTA2, review the **Instructions for Use** booklet. The following instructions are intended to help guide the physician and do not take the place of physician judgment.

14.2.1 Proximal and Distal Stent Graft Preparation and Flush

The introduction system of the proximal and distal components is flushed through the stopcock on the Captor hemostatic valve to remove air inside. The device must be flushed by Method A OR Method B:

Method A: CO₂ + Saline Flushing

1. Remove the yellow-hubbed inner stylet from the dilator tip. Verify that the Captor sleeve is within the Captor hemostatic valve; but do not remove the Captor sleeve. Upon delivery the stopcock on the connecting tube is open. (**Fig. 4**) When not in use the stopcock shall be closed.
2. Use a sterile connecting tube with a microbiological filter to connect a medical grade CO₂ source to the stopcock on the Captor hemostatic valve setup. (**Fig. 5**)
3. Open the stopcock and flush through the hemostatic valve for a minimum duration of 3 minutes. Preset the CO₂ source at a pressure of 1-1.5 bar/15-22 psi.
 - NOTE:** If the CO₂ source is equipped with a flow regulator, it must be preset to supply the maximum flow.
4. While flushing with CO₂, verify that gas is flowing out of the dilator tip by applying saline on the tip groove and observing gas bubbles.
 - NOTE:** Saline can be applied on the tip by immersing it in a beaker containing saline solution. (**Fig. 6**)
5. Once the minimum flushing time of 3 minutes has been reached, close the stopcock on the connecting tube and disconnect the CO₂ source.
6. Elevate the distal tip of the system and flush through the hemostatic valve with flushing solution until fluid exits from the groove on the dilator tip. Continue to inject a full 60 mL of flushing solution through the device. Discontinue injection and close the stopcock on the connecting tube. (**Fig. 7**)
 - NOTE:** Stent graft flushing solution of heparinized saline is often used.
7. Attach a syringe with flushing solution to the hub on the blue rotation handle. Flush until fluid exits the dilator tip. (**Fig. 8**)
8. Soak sterile gauze pads in saline solution and use them to wipe the Flexor introducer sheath to activate the hydrophilic coating. Hydrate both sheath and dilator tip liberally.

Method B: Saline Flushing

1. Remove the yellow-hubbed inner stylet from the dilator tip. Verify that the Captor sleeve is within the Captor hemostatic valve; but do not remove the Captor sleeve. Upon delivery the stopcock on the connecting tube is open. (**Fig. 4**) When not in use the stopcock shall be closed.
2. Open the stopcock on the connecting tube, elevate the distal tip of the system and flush through the hemostatic valve with flushing solution until fluid exits from the groove on the dilator tip. Continue to inject a full 60 mL of flushing solution through the device. Discontinue injection and close the stopcock on the connecting tube. (**Fig. 7**)
 - NOTE:** Stent graft flushing solution of heparinized saline is often used.
3. Attach a syringe with flushing solution to the hub on the blue rotation handle. Flush until fluid exits the dilator tip. (**Fig. 8**)
4. Soak sterile gauze pads in saline solution and use them to wipe the Flexor introducer sheath to activate the hydrophilic coating. Hydrate both sheath and dilator tip liberally.

14.2.2 Placement of Proximal Stent Graft

1. Puncture the selected artery using standard technique with an access needle. Upon vessel entry, insert:
 - Wire guide (standard 0.035 inch, 260/300 cm, 15 mm J tip or Bentson)
 - Appropriate size sheath (e.g., 5 French)
 - Pigtail flush catheter (often radiopaque-banded sizing catheters, e.g., Cook Aurous® Centimeter Vessel Sizing Catheter)
2. Perform angiography at the appropriate level. If using radiopaque markers, adjust position of the catheter as necessary and repeat angiography.
3. Ensure the device has been flushed and primed with flushing solution.
4. Give systemic heparin/anticoagulant. Flush all catheters and wet all wire guides with flushing solution. Reflush catheters and rewet wire guides after each exchange.

- Replace the standard wire guide with an extra stiff 0.035 inch, 260/300 cm, LESDC wire guide and advance through the catheter and up to the aortic arch.
NOTE: If the anatomy is difficult, consider using a brachio-femoral approach instead.
 - Remove the pigtail flush catheter and sheath.
NOTE: At this stage, the second femoral artery can be accessed for angiographic catheter placement. Alternatively, consider using a brachial approach.
 - Introduce the freshly hydrated introduction system over the wire guide and advance it until the desired stent graft position is reached.
CAUTION: To avoid inadvertent displacement of the stent graft during withdrawal of the sheath, it may be appropriate to momentarily decrease the patient's mean arterial pressure to approximately 80 mmHg (at the discretion of the physician).
CAUTION: To avoid twisting the stent graft, never rotate the introduction system when you introduce it. Allow the stent graft to conform naturally to the curves and tortuosity of the vessels.
NOTE: The dilator tip will soften at body temperature.
 - Verify wire guide position in the aortic arch. Ensure correct stent graft position.
CAUTION: Care should be taken not to advance the sheath while the stent graft is still within it. Advancing the sheath at this stage may cause the barbs to perforate the introducer sheath.
 - Ensure that the Captor hemostatic valve on the Flexor introducer sheath is turned to the open position. (Fig. 9)
 - Stabilize the gray positioner (introduction system shaft) and withdraw the sheath until the stent graft is fully expanded and the valve assembly with the Captor sleeve docks with the black gripper. (Fig. 10)
CAUTION: As the sheath is withdrawn, anatomy and graft position may change. Prior to complete unsheathing of the stent graft, check distal gold markers to make sure visceral arteries will not be covered. Constantly monitor stent graft position and perform angiography to check position as necessary.
CAUTION: During sheath withdrawal, the proximal barbs are exposed and are in contact with the vessel wall. At this stage it may be possible to advance the introduction system, but retraction may cause aortic wall damage.
NOTE: If extreme difficulty is encountered when attempting to withdraw the sheath, place the introduction system in a less tortuous position that enables the sheath to be retracted. Very carefully withdraw the sheath until it just begins to retract and stop. Move back to original position and continue deployment.
 - Verify stent graft position and, if necessary, adjust it forward. Recheck stent graft position with angiography.
NOTE: If an angiographic catheter is placed parallel to the stent graft, use the catheter to perform position angiography.
 - While holding the black gripper, turn the black safety-lock knob in the direction of the arrows until a slight click is felt, indicating that the blue rotation handle is engaged. (Fig. 11) Ensure the black safety-lock knob is in the unlocked position.
 - Under fluoroscopy, turn the blue rotation handle in the direction of the arrow until a stop is felt. (Fig. 12) This indicates that the proximal bare stent and proximal end of the stent graft have opened, and that the distal attachment to the introducer has been released.
NOTE: If the blue rotation handle stops before completing the rotation (so that the proximal end of the stent graft is not released from the introduction system), verify the position of the black safety-lock knob and, if necessary, turn it counterclockwise to the unlocked position.
NOTE: If the black safety-lock knob is removed from the introduction system after it has been turned counterclockwise to the unlocked position, the blue rotation handle will remain engaged. Continue with the procedure.
NOTE: If it is still difficult to rotate the blue rotation handle, refer to **Section 14.4, Release Troubleshooting** for instructions on how to disassemble the blue rotation handle.
 - If the Flexor introducer sheath is intended to be used as a conduit, ensure that the Captor sleeve is inside the hemostatic valve and remove the inner introduction system by pulling the gray positioner. (Fig. 13)
 - Remove the introduction system, leaving the wire guide in the stent graft.
NOTE: Inaccuracies in device size selection or placement, changes or anomalies in patient anatomy, or procedural complications may require placement of additional stent grafts and stent graft extensions to achieve the minimum length of proximal and distal seal and length of overlap between stent grafts.
- ### 14.2.3 Placement of Distal Stent Graft
- If an angiographic catheter is placed in the femoral artery, it should be repositioned to demonstrate the aortic anatomy where the distal stent graft is to be deployed.
 - Introduce the freshly hydrated introduction system over the wire guide until the desired stent graft position is reached, with at minimum a three-stent overlap (75 mm) with the proximal stent graft. No part of the distal stent graft should overlap the proximal sealing stent of the proximal stent graft, and no part of the proximal stent graft should overlap the distal sealing stent of the distal stent graft, as doing so may cause malapposition to the vessel wall.
NOTE: The dilator tip softens at body temperature.
 - Check the stent graft position by angiography and adjust if necessary.
 - Ensure that the Captor hemostatic valve on the Flexor introducer sheath is turned to the open position. (Fig. 9)
 - Stabilize the gray positioner (introduction system shaft) and withdraw the sheath until the Captor hemostatic valve with the Captor sleeve docks with the black telescoping gripper and the stent graft is fully expanded. (Fig. 14)
CAUTION: As the sheath is withdrawn, anatomy and graft position may change. Constantly monitor stent graft position and perform angiography to check position as necessary.
NOTE: If extreme difficulty is encountered when attempting to withdraw the sheath, place the introduction system in a less tortuous position that enables the sheath to be retracted. Very carefully withdraw the sheath until it just begins to retract and stop. Move back to original position and continue deployment.
 - To release the distal attachment, hold the black telescoping gripper and turn the black safety-lock knob in the direction of the arrows until a slight click is felt, indicating that the blue rotation handle is engaged. (Fig. 15) Ensure the black safety-lock knob is in the unlocked position. Turn the blue rotation handle in the direction of the arrow indicated by label 1 until a stop is felt. (Fig. 16)
NOTE: If the blue rotation handle stops before completing the rotation, verify the position of the black safety-lock knob and, if necessary, turn it counterclockwise to the unlocked position.
NOTE: If the black safety-lock knob is removed from the introduction system after it has been turned counterclockwise to the unlocked position, the blue rotation handle will remain engaged. Continue with the procedure.
 - Turn the gray safety-lock knob indicated by label 2 on the black telescoping gripper in the direction of the arrows until a slight click is felt, indicating that the black telescoping gripper is engaged. (Fig. 17)
NOTE: Care should be taken to avoid landing the distal bare stent in regions of localized angulation >45°. If the distal bare stent is landed in localized angulations >45°, it may be difficult to release the bottom cap. Using a brachio-femoral wire guide technique can increase support of the system and ease the release of the bottom cap.
 - To release the distal bare stent, stabilize the introduction system and slide the sheath together with the black telescoping gripper (by holding the Captor hemostatic valve) in a distal direction until it locks automatically into position next to the blue rotation handle. (Fig. 18) The release window on the blue rotation handle next to label 3 will turn green. (Fig. 19) If the window has not turned green, slide the black telescoping gripper until it locks with the blue rotation handle.
 - Turn the blue rotation handle in the direction of the arrow next to label 3 until a stop is felt, and the proximal end of the stent graft opens. (Fig. 19) If difficulty is encountered rotating the blue rotation handle, refer to **Section 14.4, Release Troubleshooting** for instructions on how to disassemble the blue rotation handle.
 - Remove the inner introduction system entirely, leaving the sheath and wire guide in place.
 - Close the Captor hemostatic valve on the Flexor introducer sheath by turning it to the closed position.
- ### 14.2.4 Molding Balloon Insertion – Optional
- Pure the molding balloon as follows and/or per the manufacturer's instructions:
 - Flush the wire lumen with flushing solution.
 - Remove all air from the balloon.
 - In preparation for insertion of the molding balloon, open the Captor hemostatic valve by turning it to the open position. (Fig. 9)
 - Advance the molding balloon over the wire guide and through the Captor hemostatic valve of the main body introduction system to the level of the proximal fixation seal site. Maintain proper sheath positioning.
 - Tighten the Captor hemostatic valve around the molding balloon with gentle pressure by turning it to the closed position.
CAUTION: Do not inflate the balloon in the aorta outside of the stent graft.
 - Expand the molding balloon with diluted contrast media (as directed by the manufacturer) in the area of the proximal covered stent, starting proximally and working in the distal direction.
CAUTION: Confirm complete deflation of the balloon prior to repositioning.
 - If applicable, withdraw the molding balloon to the proximal stent graft/distal stent graft overlap and expand.
 - Withdraw the molding balloon to the distal fixation site and expand.
 - Open the Captor hemostatic valve, remove the molding balloon, and replace it with an angiographic catheter to perform completion angiography.
 - Tighten the Captor hemostatic valve around the angiographic catheter with gentle pressure by turning it clockwise.
 - Remove or replace all stiff wire guides to allow the aorta to resume its natural position.
- ### 14.2.5 Final Angiogram
- Position an angiographic catheter just above the level of the stent graft. Perform angiography to verify correct positioning of the stent graft. Verify patency of arch vessels and celiac trunk.
 - In the final angiogram confirm that there are no endoleaks or kinks, that the proximal and distal gold radiopaque markers are positioned to provide adequate overlap between stent grafts, and that there is sufficient stent graft length to maintain over time a minimum of 20 mm in proximal and distal seal.
NOTE: If endoleaks or other problems are observed (e.g., inadequate seal length or overlap length), refer to **Section 14.3, Ancillary Devices: Distal Extension**.
 - Remove the sheaths, wires, and catheters.
 - Repair access vessels and close in standard surgical fashion.
- ### 14.3 Ancillary Devices: Distal Extension
- #### 14.3.1 General Use Information
- ##### 14.3.1.1 Inaccuracies in device size selection or placement, changes or anomalies in patient anatomy, or procedural complications can require placement of additional endovascular grafts and extensions. Regardless of the device placed, the basic procedure(s) will be similar to the maneuvers required and described previously in this document. It is vital to maintain wire guide access.
- #### 14.3.2 Distal Extension Preparation and Flush
- The introduction system of the distal extension component is flushed through the stopcock on the Captor hemostatic valve to remove air inside. The device must be flushed by Method A OR Method B:
- ##### Method A: CO₂ + Saline Flushing
- Remove the yellow-hubbed inner stylet from the dilator tip. Verify that the Captor sleeve is within the Captor hemostatic valve; but do not remove the Captor sleeve. Upon delivery the stopcock on the connecting tube is open. (Fig. 4) When not in use the stopcock shall be closed.
 - Use a sterile connecting tube with a microbiological filter to connect a medical grade CO₂ source to the stopcock on the Captor hemostatic valve setup. (Fig. 5)
 - Open the stopcock and flush through the hemostatic valve for a minimum duration of 3 minutes. Preset the CO₂ source at a pressure of 1-1.5 bar/15-22 psi.
NOTE: If the CO₂ source is equipped with a flow regulator, it must be preset to supply the maximum flow.
 - While flushing with CO₂, verify that gas is flowing out from the dilator tip by applying saline on the tip groove and observing gas bubbles.
NOTE: Saline can be applied on the tip by immersing it in a beaker containing saline solution. (Fig. 6)
 - Once the flushing time of minimum 3 minutes has been reached, close the stopcock on the connecting tube and disconnect the CO₂ source.
 - Elevate the distal tip of the system and flush through the hemostatic valve with flushing solution until fluid exits from the groove on the dilator tip. Continue to inject a full 60 mL of flushing solution through the device. Discontinue injection and close the stopcock on the connecting tube. (Fig. 7)
NOTE: Stent graft flushing solution of heparinized saline is often used.
 - Attach a syringe with flushing solution to the hub on the blue rotation handle. Flush until fluid exits the dilator tip. (Fig. 8)
 - Soak sterile gauze pads in saline solution and use them to wipe the Flexor introducer sheath to activate the hydrophilic coating. Hydrate both sheath and dilator tip liberally.

Method B: Saline Flushing

- Remove the yellow-hubbed inner stylet from the dilator tip. Verify that the Captor sleeve is within the Captor hemostatic valve; but do not remove the Captor sleeve. Upon delivery the stopcock on the connecting tube is open. (Fig. 4) When not in use the stopcock shall be closed.
- Elevate the distal tip of the system and flush through the hemostatic valve with flushing solution until fluid exits from the groove on the dilator tip. Continue to inject a full 60 mL of flushing solution through the device. Discontinue injection and close the stopcock on the connecting tube. (Fig. 7)
- NOTE:** Stent graft flushing solution of heparinized saline is often used.
- Attach a syringe with flushing solution to the hub on the blue rotation handle. Flush until fluid exits the dilator tip. (Fig. 8)
- Soak sterile gauze pads in saline solution and use them to wipe the Flexor introducer sheath to activate the hydrophilic coating. Hydrate both sheath and dilator tip liberally.

14.3.3 Placement of Distal Extension

- Puncture the selected artery using standard technique with an access needle. Alternatively, use the in situ wire guide that was used previously for introduction system/stent graft insertions. Upon vessel entry, insert:
 - Wire guide (standard 0.035 inch, 260/300 cm, 15 mm J tip or Bentson)
 - Appropriate size sheath (e.g., 5 French)
 - Pigtail flush catheter (often radiopaque-banded sizing catheters, e.g., Cook Aorous Centimeter Vessel Sizing Catheter)
- Perform angiography at the appropriate level. If using radiopaque markers, adjust position as necessary and repeat angiography.
- Ensure the introduction system has been primed with flushing solution, and all air has been removed.
- Give systemic heparin. Flush all catheters and wire guides with heparinized saline. Reflush catheters and rewet wire guides after each exchange.
- Replace the standard wire guide with a stiff 0.035 inch, 260/300 cm, LESDC wire guide, and advance it through the catheter and up to the aortic arch.
- Remove the pigtail flush catheter and sheath.

- NOTE:** At this stage, the second femoral artery can be accessed for flush catheter placement. Alternatively, consider using a brachial approach.
- Introduce the freshly hydrated introduction system over the wire guide and advance until the desired stent graft position is reached. Ensure that the distal extension overlaps the distal stent graft by a minimum of three stents (plus the distal bare stent).

CAUTION: To avoid twisting the stent graft, never rotate the device introduction system when introducing it. Allow the device to conform naturally to the curves and tortuosity of the vessels.

NOTE: The dilator tip softens at body temperature.

- NOTE:** To facilitate introduction of the wire guide into the introduction system, it may be necessary to slightly straighten the introduction system dilator tip.
- Verify wire guide position in the aortic arch. Ensure correct stent graft position.
- Ensure that the Captor hemostatic valve on the Flexor introducer sheath is turned counterclockwise to the open position. (Fig. 9)
- Stabilize the gray positioner (introduction system shaft) and withdraw the sheath until the stent graft is fully expanded and the valve assembly with the Captor sleeve docks with the black gripper. (Fig. 10)
- CAUTION: As the sheath or wire guide is withdrawn, anatomy and stent graft position may change. Constantly monitor stent graft position and perform angiography to check the position as necessary.**
- NOTE:** If extreme difficulty is encountered when attempting to withdraw the sheath, place the introduction system in a less tortuous position that enables the sheath to be retracted. Very carefully withdraw the sheath until it just begins to retract and stop. Move back to original position and continue deployment.
- Verify stent graft position and, if necessary, adjust it forward. Recheck stent graft position with angiography.
- While holding the black gripper, turn the black safety-lock knob in the direction of the arrow until a slight click is felt, indicating that the blue rotation handle is engaged. (Fig. 11) Ensure the black safety-lock knob is in the unlocked position.
- Under fluoroscopy, turn the blue rotation handle in the direction of the arrow until a stop is felt. (Fig. 12) This indicates that the proximal end of the stent graft has opened, and that the distal attachment to the introducer has been released.
- NOTE:** If the blue rotation handle stops before completing the rotation, verify the position of the black safety-lock knob and, if necessary, turn it counterclockwise to the unlocked position.

NOTE: If the black safety-lock knob is removed from the introduction system after it has been turned counterclockwise to the unlocked position, the blue rotation handle will remain engaged. Continue with the procedure.

NOTE: If difficulty is still encountered during rotating the blue rotation handle, refer to **Section 14.4, Release Troubleshooting** for instructions on how to disassemble the blue rotation handle.

- If the Flexor introducer sheath is intended to be used as a conduit, ensure that the Captor sleeve is inside the hemostatic valve and remove the inner introduction system by pulling the gray positioner. (Fig. 13)
- Close the Captor hemostatic valve on the Flexor introducer sheath by turning it in a clockwise direction until it stops.
- Remove the introduction system, leaving the wire guide in the stent graft.
- If necessary, use a molding balloon. See **Section 14.2.4, Molding Balloon Insertion – Optional**.
- Perform final angiogram. See **Section 14.2.5, Final Angiogram**.

14.4 Release Troubleshooting

NOTE: Technical assistance from a Cook product specialist may be obtained by contacting your local Cook representative.

NOTE: The ZTA troubleshooting methods, previously described in the 'Distal Stent - Bare Stent Deployment' section is no longer applicable for ZTA2 due to device changes.

14.4.1 Difficulty Removing Release Wires

Turning the blue rotation handle pulls the release wire back, releasing the stent graft attachment to the introducer. If the stent graft is not completely released, it is possible to disassemble the blue rotation handle by following the steps below:

- Use surgical forceps to pull the back-end clips out (Fig. 20 and 21) and remove the back-end cap. (Fig. 22)
- Stabilize the gray positioner and slide the blue rotation handle backward to pull the release wires until the stent graft is released. Do not pull the release wires completely out of the blue rotation handle. (Fig. 23 and 24)
- If leakage through the valve occurs, remove the inner introduction system entirely, leaving the sheath and wire guide in place.
- Close the Captor hemostatic valve on the Flexor introducer sheath by turning it to the closed position.
- NOTE:** If extreme force is needed, wind the release wires around the surgical forceps. (Fig. 25)

14.5 Imaging Guidelines and Postoperative Follow-Up

- All patients should be monitored closely and checked periodically for change in their aortic disease and the integrity of the stent graft.
- Additional surveillance and possible treatment are recommended for:
 - Endoleak
 - Aneurysm or ulcer enlargement, ≥ 5 mm/year of maximum aneurysm diameter or ulcer depth (regardless of endoleak status)
 - Migration
 - Inadequate seal length
 - Graft thrombosis or occlusion
 - Loss of device integrity:
 - Barb separation
 - Stent fracture
 - Relative component migration
- Consideration for reintervention or conversion to open repair should include the attending physician's assessment of an individual patient's comorbidities, life expectancy, and the patient's personal choices.
- The recommended imaging schedule is presented in **Table 49**. This schedule continues to be the minimum requirement for patient follow-up and should be maintained even in the absence of clinical symptoms (e.g., pain, numbness, weakness). Patients with specific clinical findings (e.g., endoleaks, enlarging aneurysms or ulcers, or changes in the structure or position of the stent graft) should receive follow-up at more frequent intervals.
- Annual imaging follow-up should include both contrast and non-contrast CT examinations. If renal complications or other factors preclude the use of image contrast media, non-contrast CT may be used in combination with transesophageal echocardiography for assessment of endoleak.
- The combination of contrast and non-contrast CT imaging provides information on stent graft migration, aneurysm diameter or ulcer depth change, endoleak, patency, tortuosity, progressive disease, fixation length, and other morphological changes.

Table 49 lists the minimum requirements for imaging follow-up for patients with the ZTA2 stent graft. Patients requiring more frequent follow-up should have interim evaluations.

Table 49 – Recommended Imaging Schedule for Endograft Patients

	Angiogram	CT (Contrast and Non-Contrast)
Preprocedure		X ¹
Procedural	X	
1 month		X ²
6 months		X ²
12 months (annually thereafter)		X ²

¹ Imaging should be performed within 6 months before the procedure.

² MR imaging may be used for those patients experiencing renal failure or who are otherwise unable to undergo contrast-enhanced CT, with transesophageal echocardiography being an additional option in the event of suboptimal MR imaging. For Type I or III endoleak, prompt intervention and additional follow-up post-intervention is recommended.

14.5.1 Contrast and Non-Contrast CT

- Image sets should include all sequential images at lowest possible slice thickness (≤ 1 mm). Slice thickness > 1 mm and/or omission of consecutive CT image set can prevent precise anatomical and stent graft comparisons over time. The same scan parameters (i.e., spacing, thickness, and FOV) should be used at each follow-up. Do not change the scan table x- or y- coordinates while scanning.
- Sequences must have corresponding table positions. It is important to follow acceptable imaging protocols during the CT exam.

15. REQUIRED EQUIPMENT AND ACCESSORIES

15.1 Materials Required

(Not included in the endovascular graft system)

- A selection of Zenith Alpha 2 Thoracic Endovascular Graft distal ancillary stent grafts in diameters compatible with the proximal and distal stent grafts
- Fluoroscope with digital angiography capabilities (C-arm or fixed unit)
- Contrast media
- Power injector
- Syringe
- Heparinized saline solution or another chosen anticoagulant
- Sterile gauze pads
- If CO₂ flushing is utilized: medical graded CO₂ with pressure regulator
- Microbiological filter to be included on the connecting tube between the CO₂ source and the device

15.2 Materials Recommended

The following products are recommended for implantation of any stent graft in the Zenith product line. For information on the use of these products, refer to the individual product's Instructions for Use:

- 0.035 inch (0.89 mm) extra stiff wire guide, 260/300 cm:
 - Cook Lunderquist® Extra Stiff Wire Guides (LESDC)
 - Cook Amplatz Ultra Stiff Wire Guides (AUS)
- 0.035 inch (0.89 mm) standard wire guide:
 - Cook 0.035 (0.89 mm) inch wire guides
 - Cook 0.035 (0.89 mm) inch Bentson Wire Guide
 - Cook Nimble® Wire Guides
- Molding balloons:
 - Cook Coda® Balloon Catheters
- Introducer sets:
 - Cook Check-Flo® Introducer Sets

- Sizing catheter:
 - Cook Aurous® Centimeter Vessel Sizing Catheter
- Angiographic radiopaque marker catheters:
 - Cook Beacon® Tip Angiographic Catheters
 - Cook Beacon® Tip Royal Flush Catheters, 125 cm
- Entry needles:
 - Cook single-wall entry needles
- Endovascular dilators:
 - Cook endovascular dilator sets

16. DISPOSAL OF DEVICE

After the procedure, this device may be contaminated with potentially infectious substances of human origin and should be disposed of in accordance with institutional guidelines.

17. REFERENCES

These instructions for use are based on experience from physicians and/or their published literature. Refer to your local Cook Medical sales representative for information on available literature.

18. PATIENT COUNSELING

Please inform the patient as necessary of the relevant warnings, precautions, contraindications, measures to be taken and limitations of use that the patient should be aware of.

The physician and patient (and/or family members) should review the risks and benefits when discussing this endovascular device and procedure, including:

- Risks and benefits for endovascular repair vs. medical treatment and open surgical repair
- The possibility that subsequent interventional or open surgical repair of the thoracic aneurysm or ulcer may be required after initial endovascular repair

The patient should be informed that successful endovascular treatment does not cure the underlying disease necessitating the procedure. It may thus still be possible to experience aneurysm growth despite correct treatment.

In addition to the risks and benefits of an endovascular repair, the physician should assess the patient's commitment to and compliance with postoperative follow-up as necessary to ensure continuing safe and effective results.

The physician must advise the patient of the potential complications/adverse events related to the use of this device.

The physician must complete the implant card(s) for the patient. The patient should always carry it with them and refer to the card any time they visit additional healthcare practitioners, particularly for any additional diagnostic procedures (e.g., MRI).

18.1 Symptoms

Physicians must advise patients that it is important to seek prompt medical attention if they experience signs of compromised blood flow through the graft, thoracic aneurysm or ulcer enlargement or rupture, or in case of concern.

Signs of compromised blood flow include, but may not be limited to:

- Pulseless legs
- Ischemia of intestines (abdominal pain)
- Cold extremities

Thoracic aneurysm or ulcer enlargement or rupture may be asymptomatic, but usually presents as:

- Back or chest pain
- Persistent cough
- Dizziness
- Fainting
- Rapid heartbeat
- Sudden weakness

Further, patients should be instructed to also seek medical attention if they experience any changes in their health or if new symptoms emerge including fever.

18.2 Follow-Up Information for the Patient

- The patients should be counselled that subsequent reinterventions, including endovascular and open surgical conversion, are possible following endograft placement.
- The long-term performance of endovascular grafts has not yet been established. All patients should be advised that endovascular treatment requires life-long, regular follow-up to assess their health and the performance of their endovascular graft. The recommended minimum follow-up schedule is imaging at 1, 6, and 12 months after the procedure and yearly thereafter. Patients with specific clinical findings (e.g., endoleaks, enlarging aneurysms or ulcers, or changes in the structure or position of the stent graft) should receive enhanced follow-up. Patients should be counselled on the importance of adhering to the follow-up schedule, both during the first year and at yearly intervals thereafter. Patients should be told that regular and consistent follow-up is a critical part of ensuring the ongoing safety and effectiveness of endovascular treatment of thoracic aneurysm or ulcer.
- The long-term performance of endovascular grafts has not yet been established in young patients and patients performing extreme sports.
- After endovascular graft placement, patients should be regularly monitored for endoleak, thoracic aneurysm or ulcer growth, or changes in the structure or position of the endovascular graft.

19. SERIOUS INCIDENT REPORTING

If any serious incident has occurred in relation to the device, this should be reported to Cook Medical, and the competent authority and/or regulatory authority of the country where the device was used.



Wire guide compatibility



William Cook Europe ApS

Sandet 6
4632 Bjaeverskov
Denmark
Phone: +4556868686

2024-10
I-ZTA2-457-01
cookmedical.com
© COOK 2024