

**Zenith® Fenestrated AAA Endovascular Graft**  
Instructions for Use



**TABLE OF CONTENTS**

Illustrations ..... 4-14

**1. DEVICE DESCRIPTION ..... 15**

    1.1 Proximal Body Graft ..... 15

    1.2 Proximal Body Graft Delivery System ..... 15

    1.3 Distal Bifurcated Body Graft ..... 15

    1.4 Distal Bifurcated Body Graft Delivery System ..... 15

    1.5 Iliac Leg Graft and Delivery System ..... 15

    1.6 Ancillary Components and Delivery System ..... 15

    1.7 Adjunctive Zenith Alignment Stent and Delivery System ..... 15

**2. INTENDED USE ..... 15**

**3. CONTRAINDICATIONS ..... 15**

**4. WARNINGS AND PRECAUTIONS ..... 15**

    4.1 General use information ..... 15

    4.2 Patient selection, treatment and follow-up ..... 16

    4.3 Implant procedure ..... 16

    4.4 Molding balloon use ..... 16

    4.5 MRI safety and compatibility ..... 16

**5. ADVERSE EVENTS ..... 16**

**6. SUMMARY OF CLINICAL STUDIES ..... 17**

**7. PATIENT SELECTION AND TREATMENT ..... 32**

    7.1 Individualization of treatment ..... 32

**8. PATIENT COUNSELING INFORMATION ..... 32**

**9. HOW SUPPLIED ..... 32**

**10. CLINICAL USE INFORMATION ..... 32**

    10.1 Physician training ..... 32

    10.2 Inspection prior to use ..... 32

    10.3 Materials required ..... 32

    10.4 Materials recommended ..... 32

    10.5 Device diameter sizing guidelines ..... 32

    10.6 Device length sizing guidelines ..... 33

    10.7 Graft fenestration/scallop guidelines ..... 33

**11. INSTRUCTIONS FOR USE ..... 33**

    11.1 General use information ..... 33

    11.2 Pre-implant determinants ..... 33

    11.3 Patient preparation ..... 33

    11.4 Fenestrated system ..... 33

**12. IMAGING GUIDELINES AND POST-OPERATIVE FOLLOW-UP ..... 35**

    12.1 General ..... 35

    12.2 Angiography ..... 35

    12.3 Computed tomography (CT) ..... 35

    12.4 Device x-ray ..... 35

    12.5 Renal duplex ultrasound ..... 35

    12.6 MRI safety and compatibility ..... 35

    12.7 Supplemental imaging ..... 35

**13. TRIGGER-WIRE RELEASE TROUBLESHOOTING ..... 35**

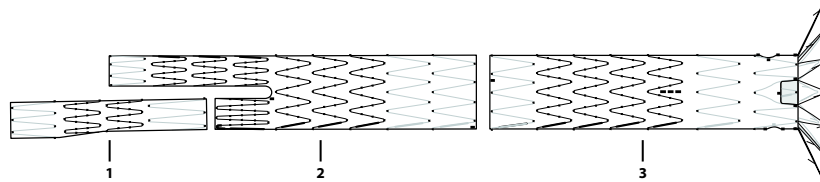
    13.1 Alternate proximal body deployment ..... 35

    13.2 Docking of top cap ..... 36

**14. SUPRARENAL STENT DEPLOYMENT TROUBLESHOOTING ..... 36**

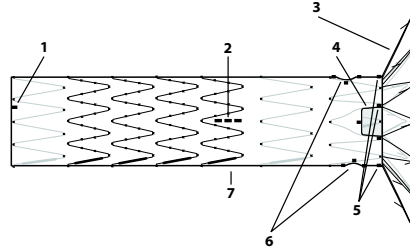
    14.1 Proximal body placement with distal attachment ..... 36

    14.2 Proximal body placement without distal attachment ..... 36



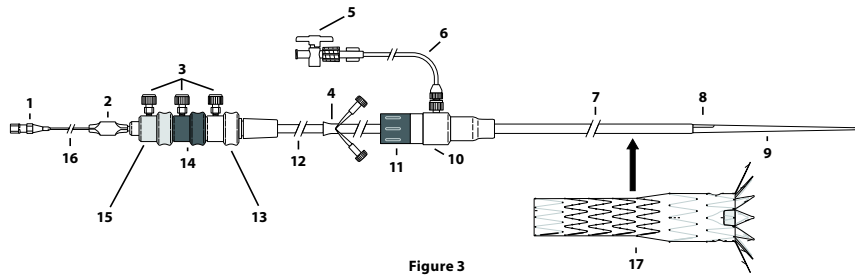
**Figure 1**

- 1. Iliac Leg
- 2. Distal Bifurcated Body
- 3. Proximal Body



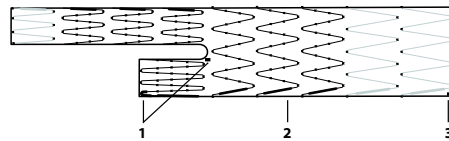
**Figure 2**

- 1. Gold Radiopaque Marker
- 2. Vertical Gold Markers
- 3. Suprarenal Stent
- 4. Scallop
- 5. Gold Radiopaque Markers (4)
- 6. Fenestration(s)
- 7. Proximal Body



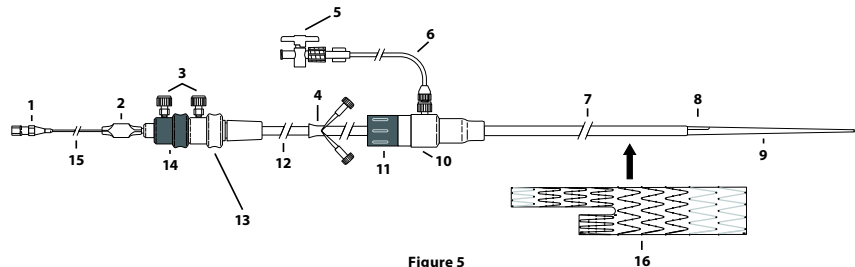
**Figure 3**

- 1. Hub
- 2. Pin Vise
- 3. Safety Locks
- 4. Peel-Away® Sheath
- 5. Stopcock
- 6. Connecting Tube
- 7. Sheath
- 8. Flushing Groove
- 9. Dilator Tip
- 10. Hemostatic Valve
- 11. Captor® Hemostatic Valve
- 12. Grey Positioner
- 13. White Trigger-Wire Release Mechanism
- 14. Black Trigger-Wire Release Mechanism
- 15. Gold Trigger-Wire Release Mechanism
- 16. Top Cap Inner Cannula
- 17. Proximal Body Graft



**Figure 4**

- 1. Gold Radiopaque Markers
- 2. Distal Bifurcated Body
- 3. Gold Radiopaque Marker



**Figure 5**

- 1. Hub
- 2. Pin Vise
- 3. Safety Locks
- 4. Peel-Away® Sheath
- 5. Stopcock
- 6. Connecting Tube
- 7. Sheath
- 8. Flushing Groove
- 9. Dilator Tip
- 10. Hemostatic Valve
- 11. Captor® Hemostatic Valve
- 12. Grey Positioner
- 13. White Trigger-Wire Release Mechanism
- 14. Black Trigger-Wire Release Mechanism
- 15. Top Cap Inner Cannula
- 16. Distal Bifurcated Body Graft

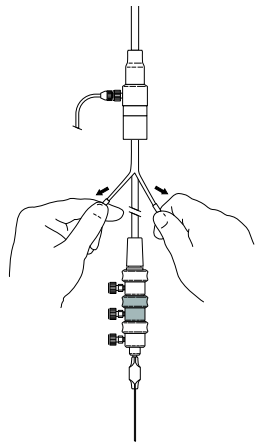


Figure 6

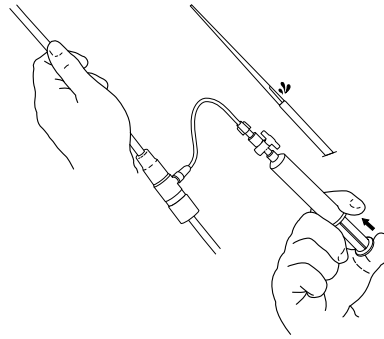


Figure 7

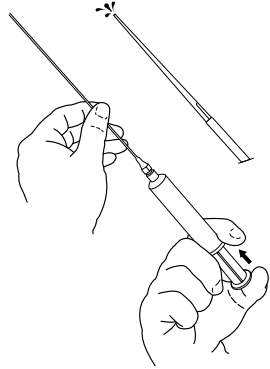


Figure 8

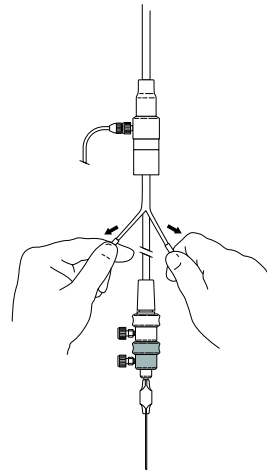


Figure 9

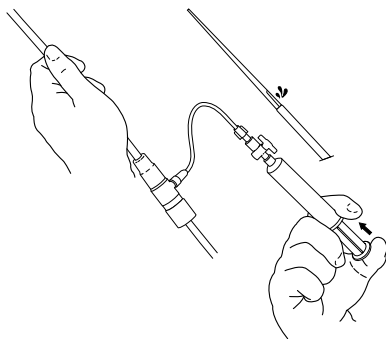


Figure 10

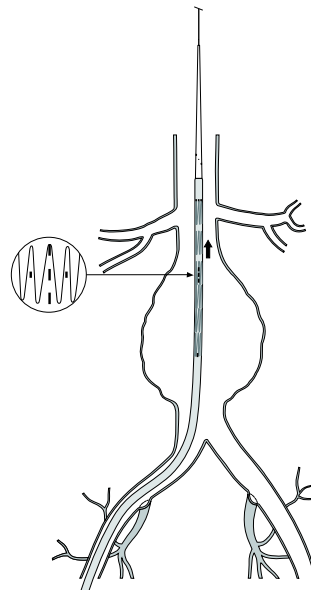


Figure 11

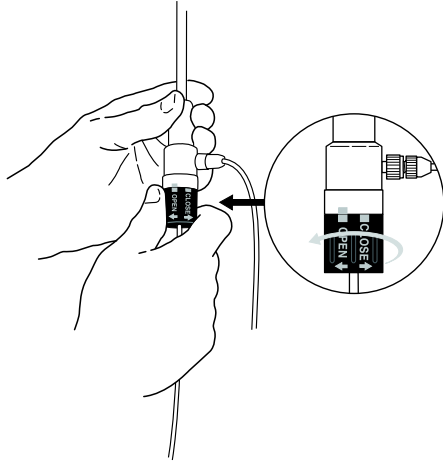


Figure 12

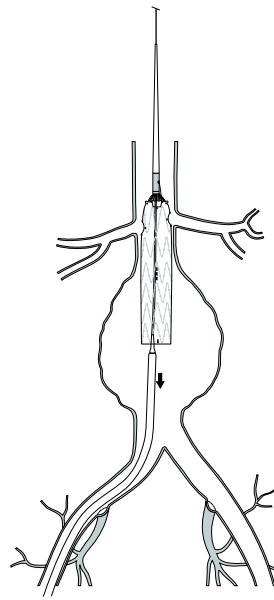


Figure 13

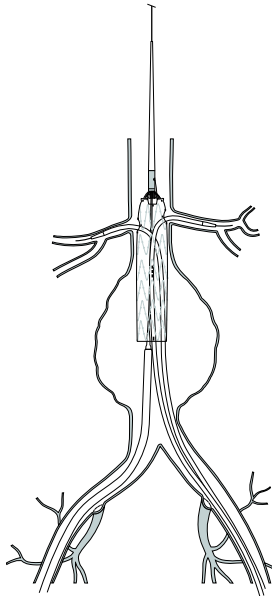


Figure 14

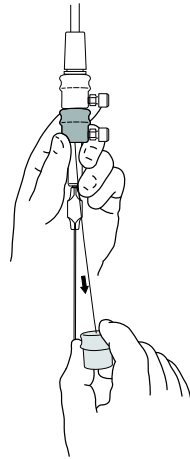


Figure 15

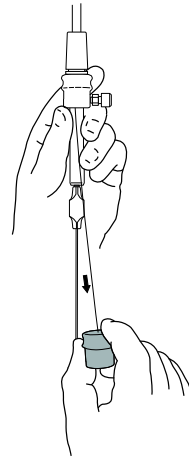


Figure 16

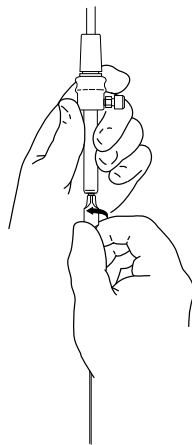


Figure 17

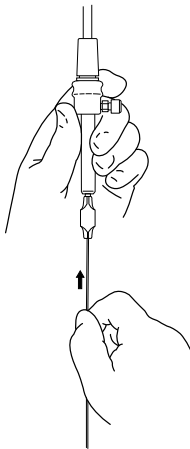


Figure 18a

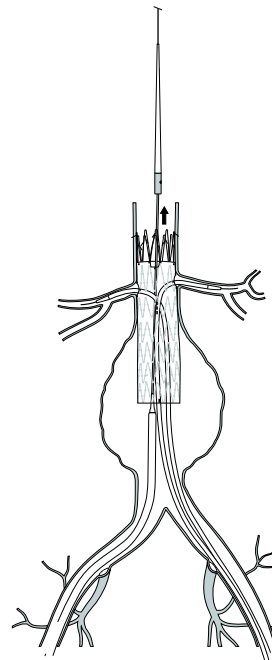


Figure 18b

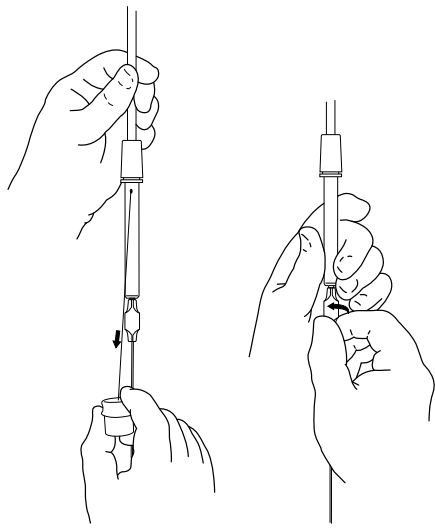


Figure 19

Figure 20

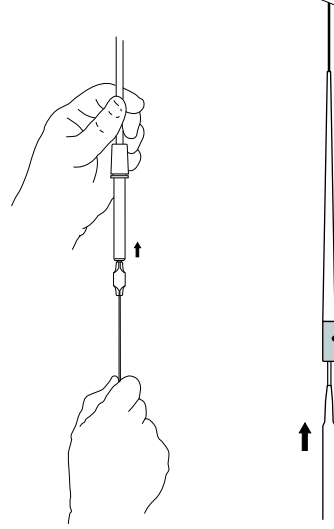


Figure 21a

Figure 21b

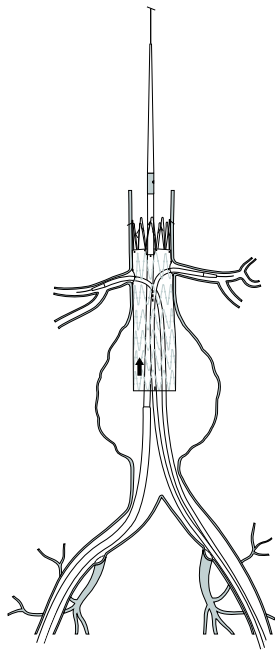


Figure 21c

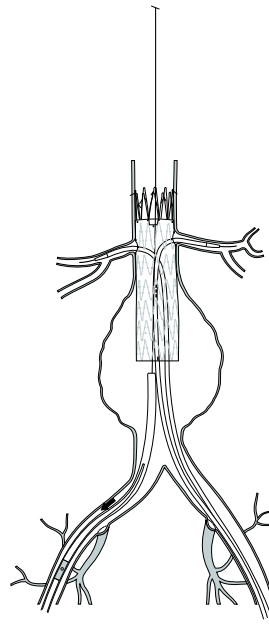


Figure 22

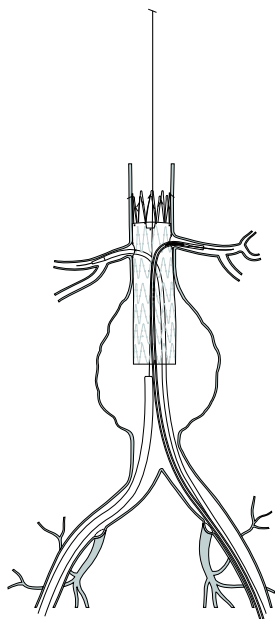


Figure 23

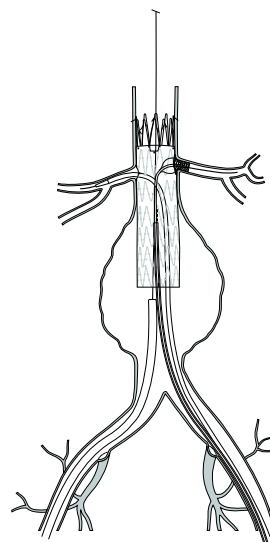


Figure 24

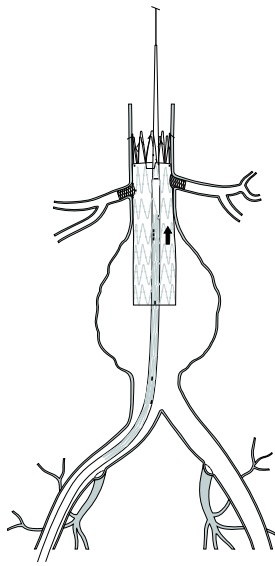


Figure 25

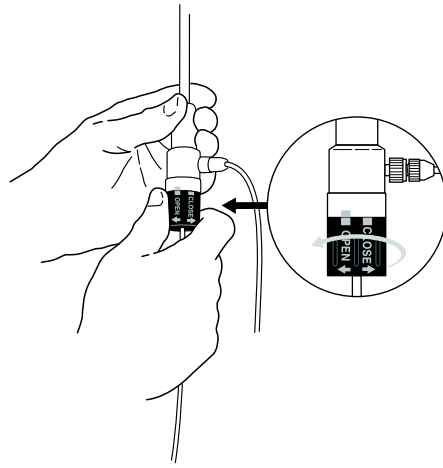


Figure 26

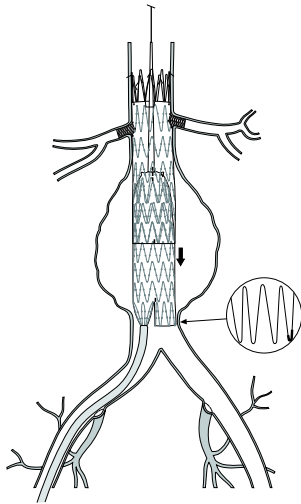


Figure 27

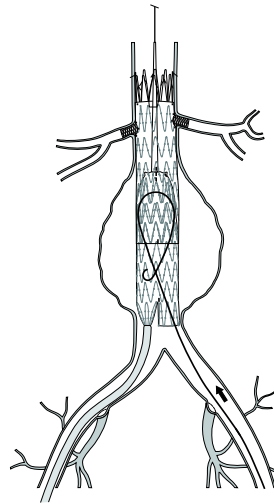


Figure 28

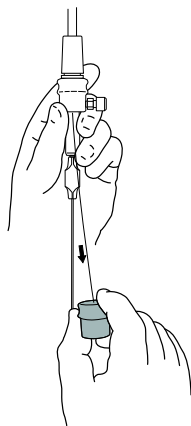


Figure 29

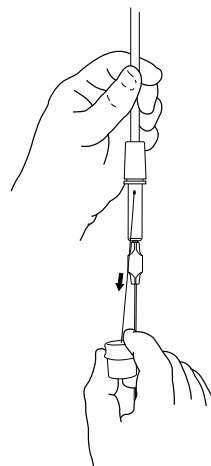


Figure 30



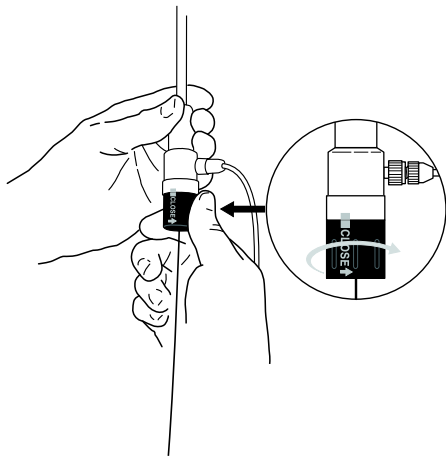


Figure 31

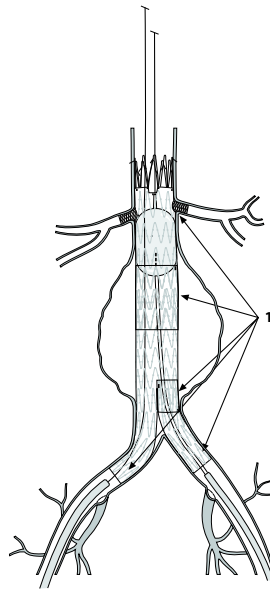


Figure 32

1. Balloon Expansion/Graft Sealing Sites

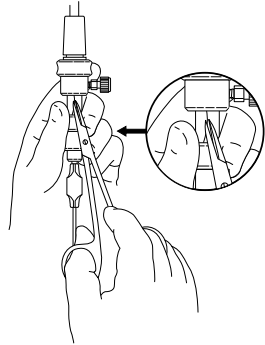


Figure 33

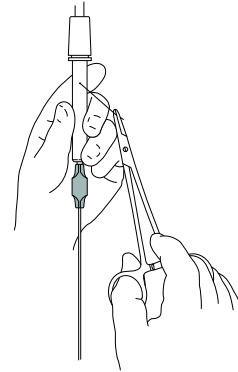


Figure 34

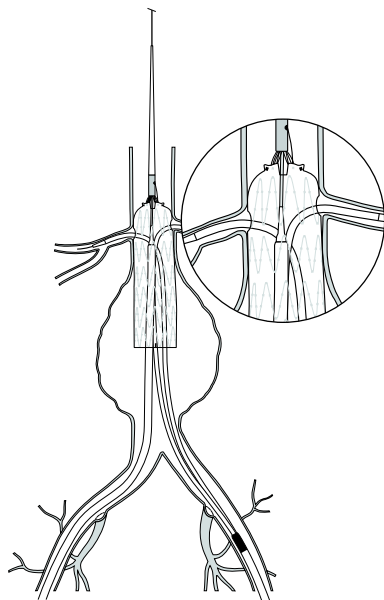


Figure 35

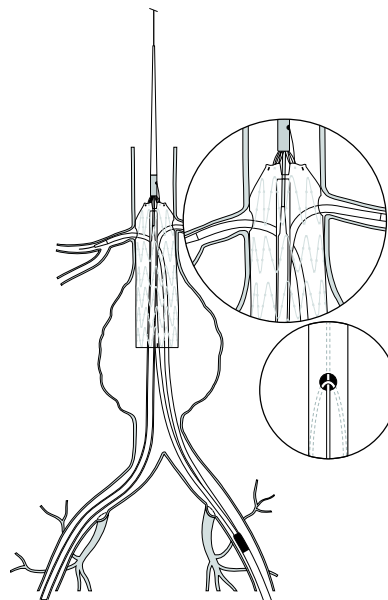


Figure 36

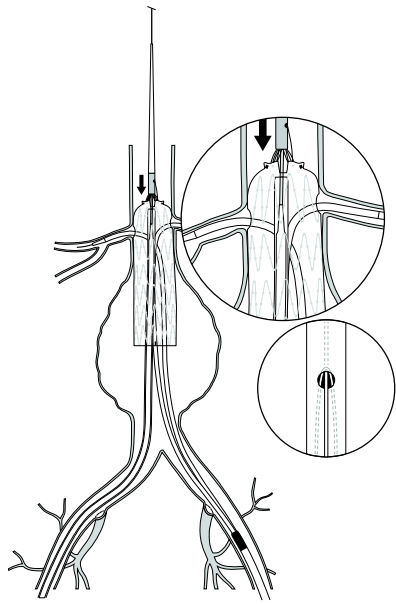


Figure 37

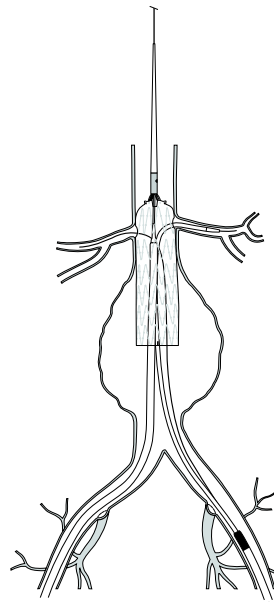


Figure 38

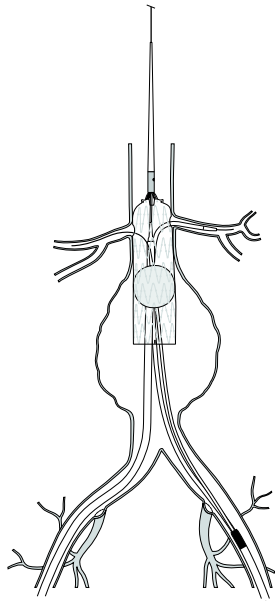


Figure 39

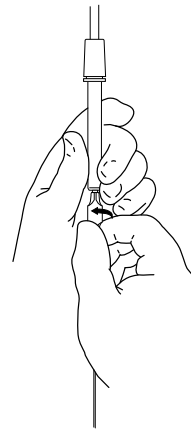


Figure 40

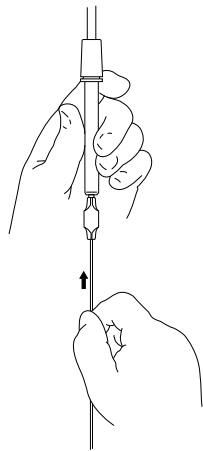


Figure 41

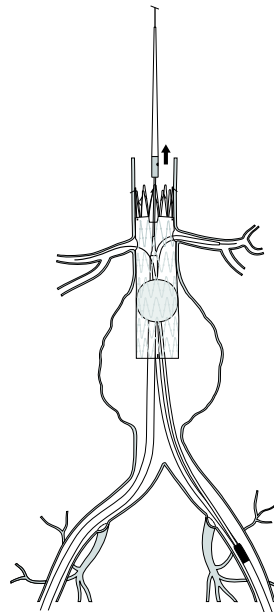


Figure 42

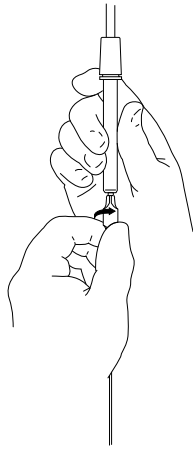


Figure 43

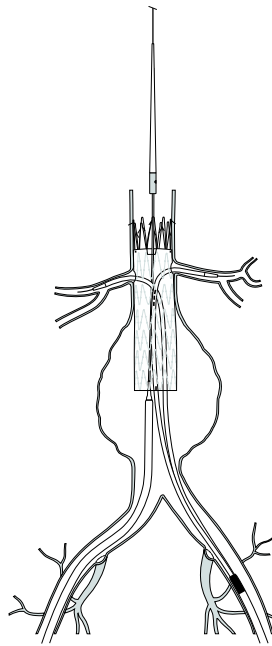


Figure 44

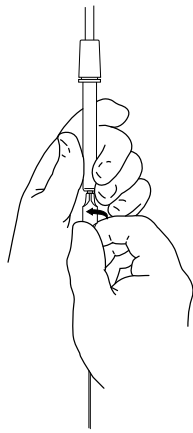


Figure 45

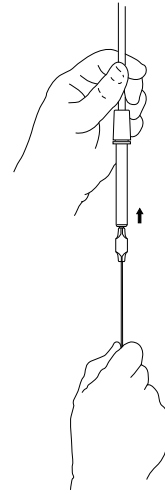


Figure 46



Figure 47

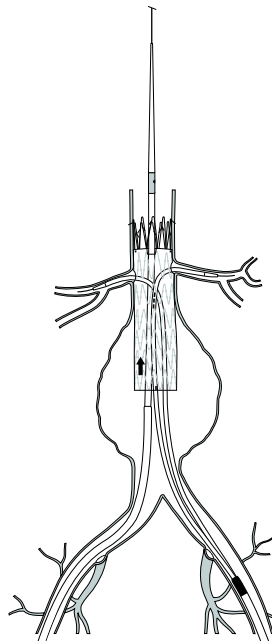


Figure 48

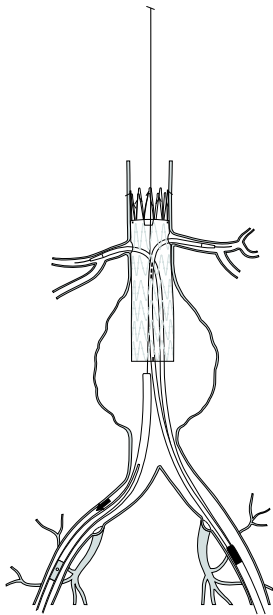


Figure 49

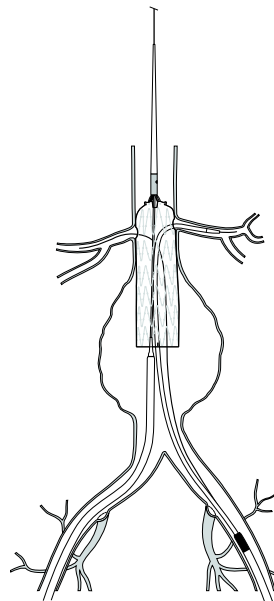


Figure 50

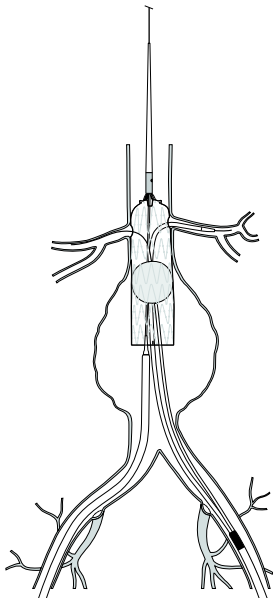


Figure 51

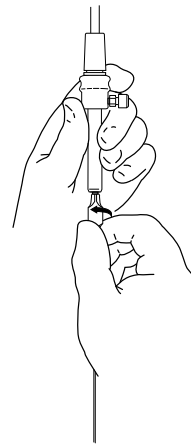


Figure 52

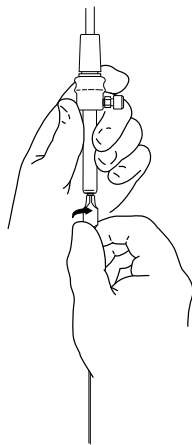


Figure 53

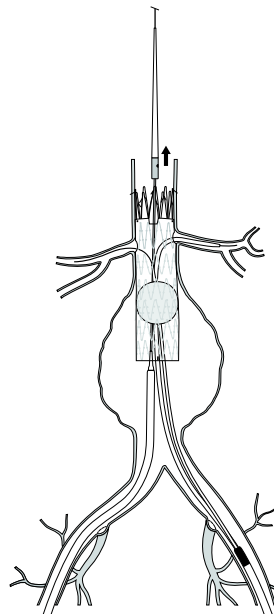


Figure 54

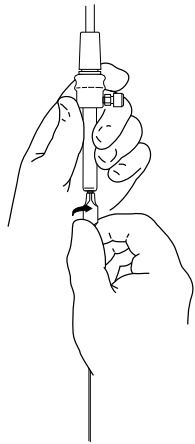


Figure 55

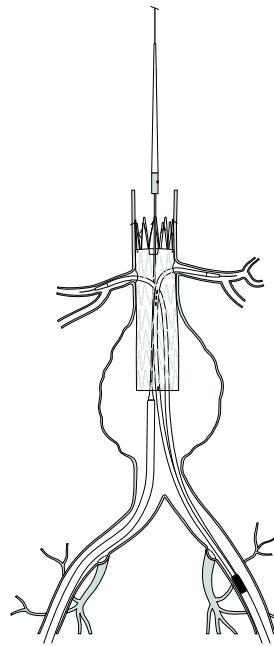


Figure 56

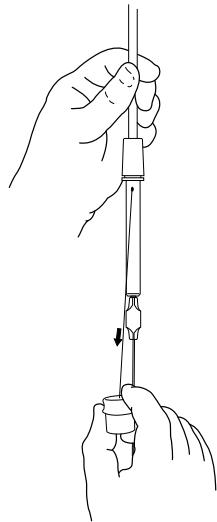


Figure 57

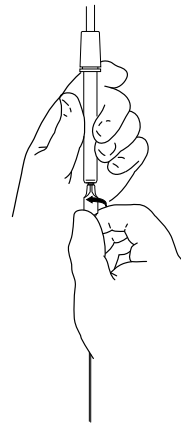


Figure 58

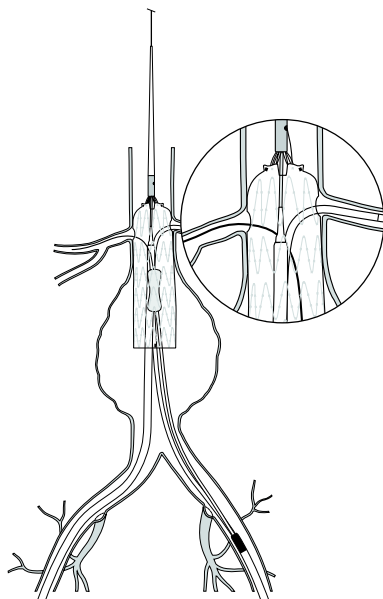


Figure 59

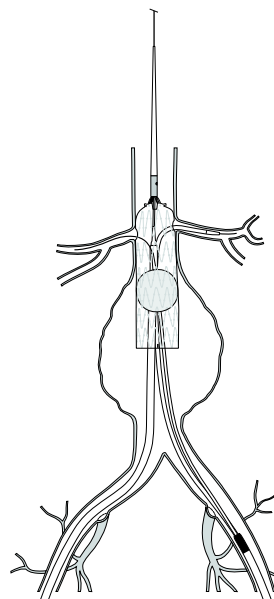


Figure 60

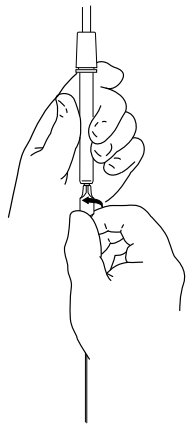


Figure 61

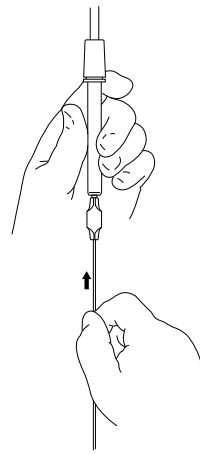


Figure 62

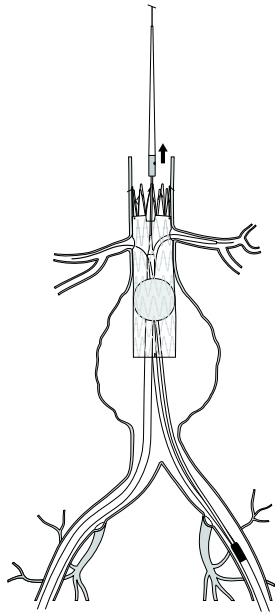


Figure 63

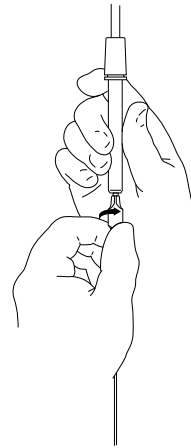


Figure 64

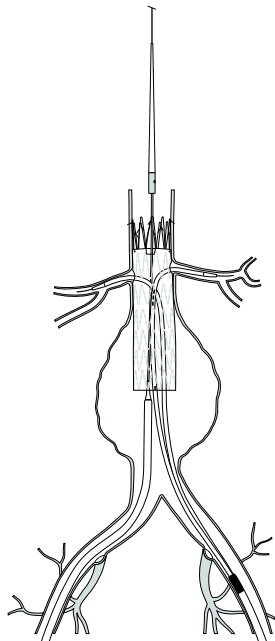


Figure 65

# ZENITH® FENESTRATED AAA ENDOVASCULAR GRAFT WITH THE H&L-B ONE-SHOT™ INTRODUCTION SYSTEM

Read all instructions carefully. Failure to properly follow the instructions, warnings, and precautions may lead to serious consequences or injury to the patient.

**CAUTION: U.S. federal law restricts this device to sale by or on the order of a physician.**

## 1. DEVICE DESCRIPTION

The Zenith Fenestrated AAA Endovascular Graft is a modular system consisting of three components, a proximal body graft, a distal bifurcated body graft and one iliac leg. (Figure 1) The graft modules are constructed of full-thickness woven polyester fabric sewn to self-expanding stainless steel Cook-Z® stents with braided polyester and monofilament polypropylene suture. The modules are fully stented to provide stability and the expansile force necessary to open the lumen of the graft during deployment. Additionally, the Cook-Z stents provide the necessary attachment and seal of the graft to the vessel wall. Ancillary devices such as main body extensions, iliac leg extensions, converters, and iliac plugs may also be required. Each individual device has its own separate delivery system. Each component comes in a range of lengths and diameters which allows the physician to tailor the device to individual patient anatomies and select the best proximal and distal fixation sites.

### 1.1 Proximal Body Graft

The bare suprarenal stent at the proximal end of the proximal body graft contains barbs that are placed at 3 mm increments for additional fixation of the device. This graft contains up to three precisely located holes (fenestration(s)), and cut-outs from the proximal margin (scallop(s)) of the graft material. (Figure 2) The fenestrations are either small (fit entirely between struts of the seal stent) or large (cross struts of the seal stent). The purpose of these scallops and fenestrations is to allow the proximal margin of the device to sit higher than standard AAA devices and allow uninterrupted blood flow to branch vessels of the aorta such as the renal and superior mesenteric arteries. It is recommended that all vessels accommodated by a small fenestration be stented in order to secure positive alignment of the graft fenestration with the vessel origin. Stenting is optional for vessels accommodated by a scallop and not recommended for vessels accommodated by a large fenestration. To facilitate fluoroscopic visualization of the stent graft, gold radiopaque markers are positioned as follows; one on the lateral aspect of the most distal stent and four in a circumferential orientation within 1 mm of the most superior aspect of the graft material. The proximal body graft also has vertically-aligned gold markers on the anterior side (at the 12:00 o'clock position) that should form a cross (+) with the horizontally-aligned gold markers on the posterior side (180 degrees opposite the vertical markers) when the device is properly oriented.

### 1.2 Proximal Body Graft Delivery System

The Zenith Fenestrated AAA Endovascular Proximal Body Graft is shipped preloaded onto the H&L-B One-Shot Introduction System. (Figure 3) It has a sequential deployment method with built-in features to provide continuous control of the graft throughout the deployment procedure. The graft is reduced in diameter by an independent wire tied to diameter reducing ties, which allows the graft to be manipulated within the aorta to allow accurate positioning of the graft, which enables the fenestration(s) to line up with the desired arteries. The bare suprarenal stent is constrained within a top cap and held by a trigger-wire. The distal end of the graft is also attached to the delivery system and held by an independent wire. The H&L-B One-Shot Introduction System enables precise positioning and allows readjustment of the final graft position before deployment of the bare barbed suprarenal stent. The delivery system uses a 6.7 mm I.D. (20 French) or 7.3 mm I.D. (22 French) H&L-B One-Shot Introduction System. All Systems are compatible with a .035 inch wire guide. For added hemostasis, the Captor™ Hemostatic Valve can be loosened or tightened for the introduction and/or removal of accessory/ancillary devices into and out of the sheath. The proximal body graft delivery system features a Flexor® introducer sheath which resists kinking and is hydrophilically coated. Both features are intended to enhance trackability in the iliac arteries and abdominal aorta.

### 1.3 Distal Bifurcated Body Graft

The Zenith Fenestrated AAA Endovascular Distal Bifurcated Body Graft has one long ipsilateral iliac limb and one short contralateral limb. To facilitate fluoroscopic visualization of the stent graft, there is a radiopaque marker at the graft bifurcation, at the distal end of the contralateral limb, and at the proximal end (contralateral side) of the graft. (Figure 4)

### 1.4 Distal Bifurcated Body Graft Delivery System

The Zenith Fenestrated AAA Endovascular Distal Bifurcated Body Graft is shipped preloaded onto the H&L-B One-Shot Introduction System. (Figure 5) It has a sequential deployment method with built-in features to provide continuous control of the graft throughout the deployment procedure. Both the proximal and distal segments of the graft are attached to the delivery system and held by independent wires. The H&L-B One Shot Introduction System enables precise positioning and allows readjustment of the graft position before deployment of the graft. The delivery system uses a 6.7 mm I.D. (20 French) H&L-B One-Shot Introduction System. All systems are compatible with a .035 inch wire guide. For added hemostasis, the Captor Hemostatic Valve can be loosened or tightened for the introduction and/or removal of accessory/ancillary devices into and out of the sheath. The distal body graft delivery system features a Flexor introducer sheath which resists kinking and is hydrophilically coated. Both features are intended to enhance trackability in the iliac arteries and abdominal aorta.

### 1.5 Iliac Leg Graft and Delivery System

The Zenith Fenestrated AAA Endovascular Graft utilizes the same iliac leg graft as is available for the standard Zenith Flex AAA Endovascular Graft. Zenith iliac leg grafts are constructed from polyester fabric, self-expanding stainless steel and nitinol Z-stents, and polypropylene suture. Refer to the iliac leg graft Instructions for Use enclosed in device packaging for more information.

### 1.6 Ancillary Components and Delivery System

The Zenith Fenestrated AAA Endovascular Graft utilizes the same ancillary components (main body extensions, iliac leg extensions,

converters, and iliac plugs) as are available for the standard Zenith Flex AAA Endovascular Graft.

Zenith ancillary components are constructed from the same polyester fabric, self-expanding stainless steel Z-stents, and polypropylene suture. Refer to the ancillary component Instructions for Use enclosed in device packaging for more information.

## 1.7 Adjunctive Zenith Alignment Stent and Delivery System

It is recommended that all vessels accommodated by a small fenestration be stented in order to secure positive alignment of the graft fenestration with the vessel origin (stenting optional for scallops and not recommended for large fenestrations). The Zenith Alignment Stent is available for this purpose. The Zenith Alignment Stent is a balloon-expandable stent that can be deployed through scallops or fenestrations in a Zenith Fenestrated AAA Endovascular Graft into branch vessels of the aorta. Refer to the Zenith Alignment Stent Instructions for Use for more information.

## 2. INTENDED USE

The Zenith Fenestrated AAA Endovascular Graft with the H&L-B One-Shot Introduction System is indicated for the endovascular treatment of patients with abdominal aortic or aorto-iliac aneurysms having morphology suitable for endovascular repair, including:

- Adequate iliac/femoral access compatible with the required introduction systems,
- Non-aneurysmal infrarenal aortic segment (neck) proximal to the aneurysm:
  - with a length that is at least 4 mm and unsuitable for a non-fenestrated graft,
  - with a diameter measured outer wall to outer wall of no greater than 31 mm and no less than 19 mm,
  - with an angle less than 45 degrees relative to the long axis of the aneurysm, and
  - with an angle less than 45 degrees relative to the axis of the suprarenal aorta.
- Ipsilateral iliac artery distal fixation site greater than 30 mm in length and 9-21 mm in diameter (measured outer wall to outer wall).
- Contralateral Iliac artery distal fixation site greater than 30 mm in length and 7-21 mm in diameter (measured outer wall to outer wall).

## 3. CONTRAINDICATIONS

The Zenith Fenestrated AAA Endovascular Graft with the H&L-B One-Shot Introduction System is contraindicated in the following:

- Patients with known sensitivities or allergies to stainless steel, polyester, nitinol, solder (tin, silver), polypropylene or gold
- Patients with systemic or local infection that may increase the risk of endovascular graft infection.

## 4. WARNINGS AND PRECAUTIONS

### 4.1 General use information

- Read all instructions carefully. Failure to properly follow the instructions, warnings and precautions may lead to serious consequences or injury to the patient.
- Fenestrated grafts are made to a customized design to a specification requested by the responsible Physician, and are tailored to a specific patient's anatomy.
- The Zenith Fenestrated AAA Endovascular Graft with the H&L-B One-Shot Introduction System should only be used by physicians and teams trained in vascular interventional techniques and in the use of this device, which requires precise planning/sizing as well as accurate longitudinal positioning and rotational orientation during placement.
- Lack of non-contrast CT imaging may result in failure to appreciate iliac or aortic calcification, which may preclude access or reliable device fixation and seal.
- Preprocedure imaging reconstruction thickness > 3 mm may result in sub-optimal device sizing, or in failure to appreciate focal stenosis from CT.
- Implantation of the Zenith Fenestrated AAA Endovascular Graft with the H&L-B One-Shot Introduction System requires high quality imaging. Some types of mobile image intensifiers may not provide adequate imaging quality.
- **The long-term performance of fenestrated endovascular grafts, including the stents placed in fenestrations/scallops, has not yet been established.** All patients should be advised that endovascular treatment requires life-long, regular follow-up to assess their health and the performance of their endovascular graft. Patients with specific clinical findings (e.g., endoleaks, enlarging aneurysms, changes in the structure or position of the endovascular graft, or stenosis/occlusion of vessels accommodated by fenestrations) should receive enhanced follow-up. Specific follow-up guidelines are described in **Section 12**.
- After endovascular graft placement, patients should be regularly monitored for perigraft flow, aneurysm growth, patency of vessels accommodated by a fenestration/scallop, or changes in the structure or position of the endovascular graft. At a minimum, annual imaging is recommended, including: 1) abdominal radiographs to examine device integrity (separation between components, stent fracture or barb separation) and 2) contrast and non-contrast CT to examine aneurysm changes, perigraft flow, patency, tortuosity and progressive disease. If renal complications or other factors preclude the use of image contrast media, abdominal radiographs and duplex ultrasound may provide similar information.
- The Zenith Fenestrated AAA Endovascular Graft with the H&L-B One-Shot Introduction System is not recommended in patients unable to undergo, or who will not be compliant with the necessary preoperative and post-operative imaging and implantation studies as described in **Section 12, Imaging guidelines and post-operative follow-up**.
- Intervention or conversion to standard open surgical repair following initial endovascular repair should be considered for patients experiencing enlarging aneurysms, unacceptable decrease in fixation length (vessel and component overlap) and/or endoleak. An increase in aneurysm size and/or persistent endoleak may lead to aneurysm rupture.
- Patients experiencing reduced blood flow through the graft limb/fenestration and/or leaks may be required to undergo secondary interventions or surgical procedures.

- Always have a vascular surgery team available during implantation or reintervention procedures in the event that conversion to open surgical repair is necessary.
- Endovascular stent grafting is a surgical procedure, and blood loss from various causes may occur, infrequently requiring intervention (including transfusion) to prevent adverse outcomes. It is important to monitor blood loss from the hemostatic valve throughout the procedure, but is specifically relevant during and after manipulation of the gray positioner. After the gray positioner has been removed, if blood loss is excessive, consider placing an uninflated molding balloon or an introduction system dilator within the valve, restricting flow.

#### 4.2 Patient selection, treatment and follow-up

- Inappropriate patient selection may result in poor performance of the Zenith Fenestrated AAA Endovascular Graft with the H&L-B One-Shot Introduction System.
- Access vessel diameter (measured inner wall to inner wall) and morphology (minimal tortuosity, occlusive disease, and/or calcification) should be compatible with vascular access techniques and delivery systems of the profile of a 14 French to 22 French vascular introducer sheath. Iliac conduits may be used to ensure the safe insertion of the introduction system. Vessels that are significantly calcified, occlusive, tortuous or thrombus-lined may preclude placement of the endovascular graft and/or may increase the risk of embolization/trauma.
- Key anatomic elements that may affect successful exclusion of the aneurysm include severe proximal neck angulation (> 45 degrees for infrarenal neck to axis of AAA or > 45 degrees for suprarenal neck relative to the immediate infrarenal neck); short proximal aortic neck (<4 mm); greater than 10% increase in diameter over 15 mm of proximal aortic neck length; and circumferential thrombus and/or calcification at the arterial implantation sites, specifically the proximal aortic neck and distal iliac artery interface. Irregular calcification and/or plaque may compromise the fixation and sealing of the implantation sites. Necks exhibiting these key anatomic elements may be more conducive to graft migration.
- The Zenith Fenestrated AAA Endovascular Graft with the H&L-B One-Shot Introduction System is not recommended in patients who cannot tolerate contrast agents necessary for intra-operative and post-operative follow-up imaging.
- The use of this device requires administration of radiographic agents. Patients with pre-existing renal insufficiency may have an increased risk of post-operative renal failure.
- The Zenith Fenestrated AAA Endovascular Graft with the H&L-B One-Shot Introduction System is not recommended in patients of excessive weight and/or size that would limit, compromise, or prevent the necessary imaging requirements.
- Inability to maintain patency of at least one internal iliac artery or occlusion of an indispensable inferior mesenteric artery may increase the risk of pelvic/bowel ischemia.
- Multiple large, patent lumbar arteries, mural thrombus and a patent inferior mesenteric artery may all predispose a patient to Type II endoleaks. Patients with uncorrectable coagulopathy may also have an increased risk of Type II endoleak or bleeding complications.
- Patients with recurrent aortic aneurysmal disease or with disease above the renal arteries may be prone to further aortic dilation in the renal/visceral segment, which could compromise device integrity/fixation.
- The Zenith Fenestrated AAA Endovascular Graft has not been evaluated in the following patient populations:
  - Less than 18 years of age
  - Females who are pregnant or breast-feeding
  - Leaking/ruptured or symptomatic aneurysms
  - Patients with connective tissue disorders
  - Patients with previous stent placement in vessels to be accommodated by fenestrations

#### 4.3 Implant procedure

- Systemic anticoagulation should be used during the implantation procedure based on hospital and physician preferred protocol. If heparin is contraindicated, an alternative anticoagulant should be considered.
- Minimize handling of the constrained endoprosthesis during preparation and insertion to decrease the risk of endoprosthesis contamination and infection.
- To activate the hydrophilic coating on the outside of the Flexor introducer sheath, the surface must be wiped with 4X4 gauze pads soaked in saline solution. Always keep the sheath hydrated for optimal performance.
- Maintain wire guide position during delivery system insertion.
- Do not bend or kink the delivery system. Doing so may cause damage to the delivery system and the Zenith Fenestrated AAA Endovascular Graft.
- Fluoroscopy should be used during introduction and deployment to confirm proper operation of the delivery system components, proper placement of the graft, and desired procedural outcome.
- The use of the Zenith Fenestrated AAA Endovascular Graft with the H&L-B One-Shot Introduction System requires administration of intravascular contrast. Patients with pre-existing renal insufficiency may have an increased risk of renal failure post-operatively. Care should be taken to limit the amount of contrast media used during the procedure.
- To avoid any twist in the endovascular graft, during any rotation of the delivery system, be careful to rotate all of the components of the system together (from outer sheath to inner cannula).
- Inaccurate placement and/or incomplete sealing of the Zenith Fenestrated AAA Endovascular Graft within the vessel may result in increased risk of endoleak, migration or inadvertent occlusion of the renal or internal iliac arteries. Renal artery patency must be maintained to prevent/reduce the risk of renal failure and subsequent complications. It is recommended that all vessels accommodated by a small fenestration be stented in order to secure positive alignment of the graft fenestration with the vessel origin.
- Inadequate fixation of the Zenith Fenestrated AAA Endovascular Graft may result in increased risk of migration of the stent graft. Incorrect deployment or migration of the endoprosthesis may require surgical intervention.
- The Zenith Fenestrated AAA Endovascular Graft incorporates a suprarenal stent with fixation bars. Exercise extreme caution when manipulating interventional devices in the region of the suprarenal stent.

- Do not continue advancing any portion of the delivery system if resistance is felt during advancement of the wire guide or delivery system. Stop and assess the cause of resistance. Vessel or catheter damage may occur. Exercise particular care in areas of stenosis, intravascular thrombosis or in calcified or tortuous vessels.
- Unless medically indicated, do not deploy the Zenith Fenestrated AAA Endovascular Graft in a location that will occlude arteries necessary to supply blood flow to organs or extremities. Do not cover significant renal or mesenteric arteries (exception is the inferior mesenteric artery) with the endoprosthesis.
- Take care during manipulation of catheters, wires and sheaths within an aneurysm. Significant disturbances may dislodge fragments of thrombus, which can cause distal embolization.
- Care should be taken not to damage the graft or disturb graft positioning after graft placement in the event reinstrumentation of the graft is necessary.

#### 4.4 Molding balloon use

- Prior to molding in the vicinity of any fenestration stent(s) confirm that the aortic section of the stent has been flared.
- Confirm complete deflation of balloon prior to repositioning.
- Do not inflate balloon in the vessel outside of graft, as doing so could result in damage to the vessel (e.g., rupture).

#### 4.5 MRI safety and compatibility

Non-clinical testing has demonstrated that the Zenith Fenestrated AAA Endovascular Graft is MR Conditional. A patient with this endovascular graft in place for at least 6 months can be scanned safely under the following conditions:

- Static magnetic field of 3.0 Tesla or 1.5 Tesla
- Maximum spatial magnetic gradient of 720 Gauss/cm or less
- Maximum MR system reported, whole-body-averaged specific absorption rate (SAR) of 2.0 W/kg for 15 minutes of scanning or less (i.e., per scanning sequence)
- Normal operating mode.

#### Static magnetic field

The static magnetic field for comparison to the above limits is the static magnetic field pertinent to the patient (i.e., outside of scanner covering, accessible to a patient or individual).

#### MRI-related heating

##### 1.5 Tesla systems:

In non-clinical testing, the Zenith AAA Endovascular Graft (similar construction as the Zenith Fenestrated AAA Endovascular Graft) produced a temperature rise of less than or equal to 1.4 °C at a maximum whole-body-averaged specific absorption rate (SAR) of 2.8 W/kg, for 15 minutes of MR scanning in a 1.5 Tesla Magnetom, Siemens Medical Magnetom, Numaris/4 Software, Version Syngo MR 2002B DHHS MR Scanner. The maximum whole-body-averaged specific absorption rate (SAR) was 2.8 W/kg, which corresponds to a calorimetry measured value of 1.5 W/kg.

##### 3.0 Tesla systems:

In non-clinical testing, the Zenith AAA Endovascular Graft (similar construction as the Zenith Fenestrated AAA Endovascular Graft) produced a temperature rise of less than or equal to 1.9 °C at a maximum whole-body-averaged specific absorption rate (SAR) of 3.0 W/kg, for 15 minutes of MR scanning in a 3.0 Tesla Excite, GE Electric Healthcare, G3.0-052B Software, MR Scanner. The maximum whole-body-averaged specific absorption rate (SAR) was 3.0 W/kg, which corresponds to a calorimetry measured value of 2.8 W/kg.

#### Image artifact

The image artifact extends throughout the anatomical region containing the device, obscuring the view of immediately adjacent anatomical structures within approximately 20 cm of the device, as well as the entire device and its lumen, when scanned in nonclinical testing using the sequence: Fast spin echo, in a 3.0 Tesla, Excite, GE Electric Healthcare, with G3.0-052B Software, MR system with body radiofrequency coil.

For all scanners, the image artifact dissipates as the distance from the device to the area of interest increases. MR scans of the head and neck and lower extremities may be obtained without image artifact. Image artifact may be present in scans of the abdominal region and upper extremities, depending on distance from the device to the area of interest. Cook recommends that the patient register the MR conditions disclosed in this IFU with the MedicAlert Foundation. The MedicAlert Foundation can be contacted in the following manners.

Mail: MedicAlert Foundation International  
2323 Colorado Avenue  
Turlock, CA 95382  
Phone: 888-633-4298 (toll free)  
209-668-3333 from outside the US  
Fax: 209-669-2450  
Web: www.medicalert.org

#### 5. ADVERSE EVENTS

Potential adverse events that may occur and/or require intervention include, but are not limited to:

- Amputation
- Anesthetic complications and subsequent attendant problems (e.g., aspiration)
- Aneurysm enlargement
- Aneurysm rupture and death
- Aortic damage, including perforation, dissection, bleeding, rupture and death
- Arterial or venous thrombosis and/or pseudoaneurysm
- Bleeding, hematoma or coagulopathy
- Bowel complications (e.g., ileus, transient ischemia, infarction, necrosis)
- Cardiac complications and subsequent attendant problems (e.g., arrhythmia, myocardial infarction, congestive heart failure, hypotension, hypertension)
- Claudication (e.g. buttock, lower limb)
- Death
- Edema
- Embolization (micro and macro) with transient or permanent ischemia or infarction



- Endoleak
- Endoprosthesis: improper component placement; incomplete component deployment; component migration; suture break; occlusion; infection; stent fracture; graft material wear; dilatation; erosion; puncture; perigraft flow; barb separation and corrosion
- Fever and localized inflammation
- Fistula (e.g., aortoenteric, arteriovenous)
- Genitourinary complications and subsequent attendant problems (e.g., ischemia, erosion, fistula, incontinence, hematuria, infection)
- Hepatic failure
- Impotence
- Infection of the aneurysm, device or access site, including abscess formation, transient fever and pain
- Lymphatic complications and subsequent attendant problems (e.g., lymph fistula)
- Neurologic local or systemic complications and subsequent attendant problems (e.g., confusion, stroke, transient ischemic attack, paraplegia, paraparesis, paralysis)
- Occlusion of device or native vessel
- Organ impairment/loss due to side-branch vessel occlusion (in particular, renal and/or gastrointestinal impairment/loss)
- Pulmonary/respiratory complications and subsequent attendant problems (e.g., pneumonia, respiratory failure, prolonged intubation)
- Renal complications and subsequent attendant problems (e.g., artery stenosis or occlusion, contrast toxicity, infarct, insufficiency, failure)
- Surgical conversion to open repair
- Vascular access site complications, including infection, pain, hematoma, pseudoaneurysm, arteriovenous fistula, dissection
- Vascular spasm or vascular trauma (e.g., iliofemoral vessel dissection, bleeding, rupture, death)
- Vessel damage
- Wound complications and subsequent attendant problems (e.g., dehiscence, infection, hematoma, seroma, cellulitis).

## 6. SUMMARY OF CLINICAL STUDIES

The Zenith Fenestrated AAA Endovascular Graft US clinical study is a non-randomized, multi-center study that was conducted to help evaluate the safety and effectiveness of the Zenith Fenestrated AAA Endovascular Graft in the treatment of abdominal aortic aneurysms in patients with short infrarenal neck lengths (>4 mm and <15 mm). A total of 42 patients were enrolled among 7 investigational sites between January 6, 2005 and August 18, 2010. Each patient was treated with an individually tailored

Fenestrated Graft. The study was initially approved for 30 patients and use of available balloon-expandable stents in combination with the Fenestrated Graft. Following completion of the initial 30 patient enrollment, the study hypothesis and requirements for approval were agreed upon. The study was then expanded to include the Zenith Alignment Stent and enrollment of 12 additional patients, thus providing 42 total patients, which was the pre-specified study sample size. The adjunctive Zenith Alignment Stent was used in 11 total patients.

The primary safety and effectiveness endpoint was based on treatment success, which was defined as technical success (i.e., successful access of the aneurysm site and deployment of the Zenith Fenestrated AAA Endovascular Graft in the intended location, with all vessels targeted by fenestrations patent at the completion of the procedure) plus freedom from the following at 6 months: Type I and III endoleak, aneurysm growth >0.5 cm, any AAA-related serious adverse event (death, rupture, conversion), and any AAA-related major complication (Q-wave MI; congestive heart failure; cardiac ischemia requiring intervention; renal failure requiring permanent dialysis; bowel obstruction, ischemia, or fistula; stroke with permanent deficit; paralysis). The study results for the primary endpoint, treatment success, were explored in patients treated with the Zenith Fenestrated AAA Endovascular Graft and in matched patients treated with the standard Zenith AAA Endovascular Graft. Propensity score methods with a pre-specified one-to-one global matching algorithm were used to select patients from the Zenith AAA Endovascular Graft multicenter study. The covariates for matching were pre-specified and included the following relevant demographic, comorbid, and anatomic characteristics, all of which were comparable between the two groups: age, gender, height, weight, arrhythmia, cancer, chronic heart failure, chronic obstructive pulmonary disease, cerebrovascular disease, diabetes, hypertension, previous diagnosis of systemic infection, previous myocardial infarction, peripheral vascular disease, previous surgeries at access site, thromboembolic event, maximum aneurysm diameter, minimum aneurysm diameter, and neck diameter.

Additional measures assessed in the cohort of patients treated with the Fenestrated Graft included mortality, pre-specified morbid events, change in aneurysm size, endoleak, migration, device integrity, and secondary interventions. The patients were to be seen for clinical and imaging (CT and X-ray) follow-up at pre-discharge, 1 month, 6 months, 12 months, and yearly thereafter through 5 years.

**Table 6.1** reports the patient availability for follow-up. Of 42 patients enrolled in the clinical study, 95% (40) were evaluable for the primary endpoint analysis. The 42 patient cohort, combines patient data from the feasibility study (n = 30; implanted device between January 2005 – January 2006) with pivotal study data (n = 12).

Follow-up visit	Patients eligible for follow-up <sup>3</sup>	Percent of data available <sup>1</sup>			Adequate imaging to assess the parameter <sup>2</sup>				Events occurring before next interval				
		Clinical	X-ray	CT	Size increase	Endoleak	Migration	Fracture	Death	Conversion	Lost to follow-up (LTF) or withdrawal	Refused consent for 3-5 Year follow-up <sup>4</sup>	Not due for next visit
Pre-discharge	42 (0)	100.0% (42/42)	95.2% (40/42)	95.2% (40/42)	95.2% (40/42)	92.9% (39/42)	95.2% (40/42)	100.0% (42/42)	0	0	0	0	0
30-day	42 (0)	97.6% (41/42)	88.1% (37/42)	97.6% (41/42)	97.6% (41/42)	92.9% (39/42)	95.2% (40/42)	97.6% (41/42)	1	0	1	0	0
6-month	40 (0)	97.5% (39/40)	95.0% (38/40)	95.0% (38/40)	95.0% (38/40)	87.5% (35/40)	95.0% (38/40)	97.5% (39/40)	0	0	1	0	4
12-month	35 (3)	91.4% (32/35)	82.9% (29/35)	88.6% (31/35)	82.9% (29/35)	80.0% (28/35)	82.9% (29/35)	82.9% (29/35)	1	0	0	0	7
24-month	27 (0)	96.3% (26/27)	85.2% (23/27)	96.3% (26/27)	96.3% (26/27)	81.5% (22/27)	96.3% (26/27)	96.3% (26/27)	1	0	0	6	0
3-year	20 (0)	90.0% (18/20)	70.0% (14/20)	90.0% (18/20)	75.0% (15/20)	70.0% (14/20)	80.0% (16/20)	75.0% (15/20)	0	0	1	0	0
4-year	19 (0)	94.7% (18/19)	73.7% (14/19)	89.5% (17/19)	84.2% (16/19)	63.2% (12/19)	84.2% (16/19)	89.5% (17/19)	0	0	2	0	0
5-year	17 (0)	100.0% (17/17)	70.6% (12/17)	82.4% (14/17)	64.7% (11/17)	52.9% (9/17)	64.7% (11/17)	64.7% (11/17)	0	0	0	0	0

<sup>1</sup>Site submitted data.

<sup>2</sup>Based on core lab analysis – does not include imaging exams received by the core lab for analysis, but that have not yet been analyzed.

<sup>3</sup>Number in parenthesis indicates the number of patients without submitted data who are still eligible for follow-up.

<sup>4</sup>Initial cohort of 30 patients consented only for 2-year follow-up and therefore were asked to consent for 3-5 year follow-up.

**Table 6.2** summarizes the demographics and patient characteristics of patients implanted with the Zenith Fenestrated AAA Endovascular Graft.

Demographic	Result <sup>1</sup>
Age (years)	75.3 ± 7.4 (58 - 86), 42
<b>Gender</b>	
Male	78.6% (33/42)
Female	21.4% (9/42)
<b>Ethnicity</b>	
White	92.9% (39/42)
Hispanic or Latino	2.4% (1/42)
Black or African American	0.0% (0/42)
American Indian or Alaska Native	2.4% (1/42)
Asian	2.4% (1/42)
Native Hawaiian or other Pacific Islander	0.0% (0/42)
Other	0.0% (0/42)
Height (in)	67.5 ± 4.4 (51 - 74), 41
Weight (lbs)	190.6 ± 46.9 (110 - 342), 42
Body mass index	28.7 ± 4.8 (19.5 - 40.8), 41

<sup>1</sup> Mean values +/- the standard deviation, with the range of values shown in parentheses, followed by the number of patients evaluated

Table 6.3 presents the medical history.

**Table 6.3 Pre-existing comorbid medical conditions**

Medical history	Percent patients (number/total number)
<b>Cardiovascular</b>	
Previous myocardial infarction	23.8% (10/42)
Previous diagnosis of symptomatic congestive heart failure	9.5% (4/42)
Previous diagnosis of coronary artery disease	52.4% (22/42)
Previous diagnosis of cardiac arrhythmia	40.5% (17/42)
<b>Vascular</b>	
Thromboembolic event	11.9% (5/42)
Peripheral vascular disease	23.8% (10/42)
Family history of aneurysmal disease	14.3% (6/42) <sup>1</sup>
Hypertension	92.9% (39/42)
<b>Pulmonary</b>	
Chronic obstructive pulmonary disease	33.3% (14/42)
<b>Renal</b>	
Diagnosis of renal failure requiring dialysis	0.0% (0/42)
Renal insufficiency	9.5% (4/42)
GFR ≤ 60 ml/min/1.73 m <sup>2</sup>	21.4% (9/42)
<b>Endocrine</b>	
Diabetes	26.2% (11/42)
<b>Infectious disease</b>	
Previous diagnosis of sepsis	7.1% (3/42)
<b>Gastrointestinal</b>	
Gastrointestinal disease	40.5% (17/42)
<b>Hepatobiliary</b>	
Previous diagnosis of liver disease	2.4% (1/42)
<b>Neoplasms</b>	
Previous diagnosis of cancer	35.7% (15/42)
<b>Neurologic</b>	
Previous diagnosis of cerebrovascular disease	16.7% (7/42)
Previous endarterectomy	2.4% (1/42)
<b>Substance use</b>	
Excessive alcohol use	0.0% (0/42)
Tobacco use: currently smokes	28.6% (12/42)
quit smoking	57.1% (24/42)
never smoked	14.3% (6/42)
<b>Access site</b>	
Previous surgery at the intended access site	11.9% (5/42) <sup>2</sup>
Previous radiation at the intended access site	0.0% (0/42)

<sup>1</sup> In 11.9% (5/42) of patients family history of aneurysmal disease was reported as unknown.

<sup>2</sup> In 2.4% (1/42) of patients previous surgery at intended access site was reported as unknown.

Table 6.4 lists the anatomical characteristics of the subject population for this study, as assessed by the core lab.

**Table 6.4 Presenting anatomical dimensions, as assessed by core lab**

Measure	Mean ± S.D. (range), N=42
<b>Aortic diameters (mm)</b>	
Diameter at celiac artery	28.2 ± 3.2 (21.2 - 35.9)
Diameter at SMA	28 ± 3.5 (22.3 - 39.8)
Diameter at lowest patent renal artery	25.7 ± 3.2 (19.2 - 33.2)
Diameter at midpoint of renal arteries	25.5 ± 5.1 (0.0 - 32.2)
Maximum aneurysm diameter – long axis	61.1 ± 10.9 (45.2 - 94.2)
Maximum aneurysm diameter – short axis	56.8 ± 10.3 (43.4 - 90.4)
Proximal neck length (mm)	9.7 ± 3.5 (2.4 - 19.1)
<b>Angles (°)</b>	
Angle between immediate suprarenal neck and immediate infrarenal neck	15.9 ± 9.6 (2 - 40)
Angle between the proximal neck and the longitudinal axis of the aneurysm	34 ± 14.2 (7 - 57)
<b>Diameter of renal artery ostia (mm)</b>	
Right renal artery	6.5 ± 1.2 (4.6 - 8.9)
Left renal artery	6.8 ± 1.3 (4.0 - 9.4)

Table 6.5 reports the type of stent-graft components that were deployed during the index procedure. All but one patient received the standard 3-piece system (proximal graft, distal graft, contralateral leg) – one patient received only a proximal graft, which landed in a previous open surgical graft and thus did not require a distal graft or contralateral leg.

**Table 6.5 Stent-graft components deployed**

Type	Percent patients (number/total number)
Proximal graft	100% (42/42)
Distal graft	97.6% (41/42)*
Contralateral leg	97.6% (41/42)*
<b>Ancillary components</b>	
Main body extension	0.0% (0/42)
Additional iliac leg	7.1% (3/42)
Ipsilateral iliac leg extension	2.4% (1/42)
Contralateral iliac leg extension	7.1% (3/42)
Occluder	0.0% (0/42)
Converter	0.0% (0/42)

\* One patient that had undergone prior open surgical AAA repair received only the proximal fenestrated component

Table 6.6 reports the sizes (diameters and lengths) of the proximal grafts used during the initial implant procedure. The full range of available graft diameters and lengths was utilized.

**Table 6.6 Proximal graft sizes used**

Diameter (mm)	Length (mm)					Total
	97	107	109	122	124	
24	0	0	0	0	2	2
26	0	0	4	0	0	4
28	1	0	7	0	4	12
30	1	0	6	0	9	16
32	0	0	1	0	2	3
34	0	2	0	2	0	4
36	0	0	0	1	0	1
Total	2	2	18	3	17	42

Table 6.7 reports the sizes (diameters and lengths) of the distal grafts used during the initial implant procedure. The full range of available graft diameters and lengths was utilized.

**Table 6.7 Distal graft sizes used**

Diameter (mm)	Length (mm)						Total
	119	121	136	138	151	153	
12	0	2	2	1	0	3	8
16	0	2	3	4	2	2	17
20	1	0	1	3	1	5	14
24	0	0	1	0	1	0	2
Total	1	4	7	8	4	10	41

Table 6.8 reports the sizes (diameters and lengths) of the contralateral leg grafts used during the initial implant procedure.

Diameter (mm)	Length (mm)						Total
	54	56	71	73	88	90	
12	3	1	2	0	0	0	6
14	1	0	10	0	1	0	12
16	3	0	3	1	0	0	7
18	6	0	3	0	1	0	10
20	0	0	3	0	0	1	4
22	0	0	1	0	0	0	1
24	0	0	1	0	0	0	1
Total	13	1	23	1	2	1	41

The location of the most proximal graft margin relative to the renal arteries, SMA, and celiac artery is provided in Table 6.9. The proximal margin of the graft was above the renal arteries in all patients.

Location of proximal graft margin relative to specified vessel	Percent patients (number/total number)
Renal arteries	Above 100.0% (42/42)
	Below 0.0% (0/42)
SMA	Above 66.7% (28/42)
	Below 33.3% (14/42)
Celiac	Above 0.0% (0/42)
	Below 100.0% (42/42)

The specific graft fenestration/scallop configurations that were utilized to accommodate the vessels intended to remain patent are provided in Table 6.10. The most commonly used configuration was 2 fenestrations and 1 scallop.

Configurations	% (n/N)
1 scallop	9.5% (4/42)
1 small fenestration and 1 scallop	11.9% (5/42)
2 small fenestrations	4.8% (2/42)
2 small fenestrations and 1 scallop	69.0% (29/42)
2 small fenestrations and 1 large fenestration	4.8% (2/42)

Table 6.11 provides the total number of each stent type used during the initial implant procedure. Eleven (11) patients received a Zenith Alignment Stent.

Stent type/description	(n)
Zenith Alignment Stent (uncovered, balloon-expandable, 316 L stainless steel)	22
Uncovered, balloon-expandable, 316L stainless steel biliary stent	28
Uncovered, balloon-expandable, 316L stainless steel biliary/iliac stent	20
Uncovered, balloon-expandable, 316L stainless steel biliary/renal stent	8
Covered, balloon-expandable, 316L stainless steel tracheobronchial stent	2

Table 6.12 indicates which vessels were targeted by either a fenestration or scallop and were either stented or unstented. All vessels accommodated by a small fenestration were stented.

Vessel	Small fenestration		Large fenestration		Scallop		Total
	Stented	Unstented	Stented	Unstented	Stented	Unstented	
Celiac	0	0	0	0	0	0	0
SMA	0	0	0	2	0	29	31
Right renal	35	0	0	0	3	0	38
Left renal	36	0	0	0	4	2	42
Accessory	0	0	0	0	0	0	0
Total	71	0	0	2	7	31	111

#### Primary endpoint

Table 6.13 reports the 6-month treatment success for the Zenith Fenestrated AAA Endovascular Graft, as compared to the matched patients treated with the standard Zenith AAA Endovascular Graft. Of 42 patients enrolled in the clinical study, 40 were evaluable for the primary endpoint analysis (two patients were lost to follow-up). The 6-month treatment success rate was 97.5% in the Fenestrated endovascular treatment group compared to 95% in the matched Zenith AAA cohort.

Measure	Zenith Fenestrated	Zenith AAA
Treatment success	97.5% (39/40) <sup>1</sup>	95.0% (38/40) <sup>2</sup>

<sup>1</sup>Failure due to bowel ischemia

<sup>2</sup>Failure due to congestive heart failure in one and congestive heart failure as well as cardiac ischemia requiring intervention in another.

#### Safety data

Table 6.14 reports the technical success results for the Zenith Fenestrated AAA Endovascular Graft, which was defined as successful access of the aneurysm site and deployment of the Zenith Fenestrated AAA Endovascular Graft in the intended location, with all vessels targeted by fenestrations patent at the completion of the procedure. Technical success was 100%.

Measure	Percent (n/N)
Technical success	100.0% (42/42)

**Table 6.15** reports the Kaplan-Meier survival estimates for freedom from major adverse events (MAE) within 30 days (death, Q-wave MI, bowel ischemia, paralysis, stroke, reintubation, renal failure requiring dialysis). There were no MAEs in the Zenith AAA group within 30 days.

Event	Parameter	Zenith Fenestrated
Any MAE	Number at risk	41
	Cumulative events	1
	Cumulative censored	0
	Kaplan-Meier estimate	0.976
	Standard error	0.024
Death	Number at risk	42
	Cumulative events	0
	Cumulative censored	0
	Kaplan-Meier estimate	1.000
	Standard error	0.000
Q-wave MI	Number at risk	42
	Cumulative events	0
	Cumulative censored	0
	Kaplan-Meier estimate	1.000
	Standard error	0.000
Bowel ischemia	Number at risk	41
	Cumulative events	1
	Cumulative censored	0
	Kaplan-Meier estimate	0.976
	Standard error	0.024
Paralysis	Number at risk	42
	Cumulative events	0
	Cumulative censored	0
	Kaplan-Meier estimate	1.000
	Standard error	0.000
Stroke	Number at risk	42
	Cumulative events	0
	Cumulative censored	0
	Kaplan-Meier estimate	1.000
	Standard error	0.000
Re-intubation	Number at risk	42
	Cumulative events	0
	Cumulative censored	0
	Kaplan-Meier estimate	1.000
	Standard error	0.000
Renal failure requiring dialysis	Number at risk	42
	Cumulative events	0
	Cumulative censored	0
	Kaplan-Meier estimate	1.000
	Standard error	0.000

**Table 6.16** provides the Kaplan-Meier estimates for freedom from serious adverse events (death [all-cause and AAA-related], rupture, and conversion), as compared to Zenith AAA. AAA-related death was defined as any death occurring within 30 days of the initial implant procedure (or secondary intervention) or any death determined by the independent clinical events to be related. The cause of death was unknown in one patient from the Zenith Fenestrated group, which the CEC was therefore unable to adjudicate – this was the only patient death counted as AAA-related in the Zenith Fenestrated group. No aneurysm ruptures or conversions to open repair were reported in the Zenith Fenestrated group.

Event	Group	Parameter	30 days	365 days	730 days	1095 days	1460 days	1825 days
All-cause mortality	Zenith Fenestrated	Number at risk	42	36	27	20	19	14
		Cumulative events	0	1	2	4	4	4
		Cumulative censored	0	5	13	18	19	24
		Kaplan-Meier estimate	1.000	0.976	0.943	0.861	0.861	0.861
		Standard error	0.000	0.024	0.040	0.066	0.066	0.066
	Zenith AAA	Number at risk	33	32	30	30	28	17
		Cumulative events	0	0	2	2	2	2
		Cumulative censored	0	1	1	1	3	14
		Kaplan-Meier estimate	1.000	1.000	0.938	0.938	0.938	0.938
		Standard error	0.000	0.000	0.043	0.043	0.043	0.043
AAA-related mortality	Zenith Fenestrated	Number at risk	42	36	27	20	19	14
		Cumulative events	0	0	0	1*	1	1
		Cumulative censored	0	6	15	21	22	27
		Kaplan-Meier estimate	1.000	1.000	1.000	0.955	0.955	0.955
		Standard error	0.000	0.000	0.000	0.044	0.044	0.044
	Zenith AAA	Number at risk	33	32	30	30	28	17
		Cumulative events	0	0	0	0	0	0
		Cumulative censored	0	1	3	3	5	16
		Kaplan-Meier estimate	1.000	1.000	1.000	1.000	1.000	1.000
		Standard error	0.000	0.000	0.000	0.000	0.000	0.000
Rupture	Zenith Fenestrated	Number at risk	42	37	28	21	21	18
		Cumulative events	0	0	0	0	0	0
		Cumulative censored	0	5	14	21	21	24
		Kaplan-Meier estimate	1.000	1.000	1.000	1.000	1.000	1.000
		Standard error	0.000	0.000	0.000	0.000	0.000	0.000
	Zenith AAA	Number at risk	33	32	30	30	28	17
		Cumulative events	0	1	1	1	1	1
		Cumulative censored	0	0	2	2	4	15
		Kaplan-Meier estimate	1.000	0.970	0.970	0.970	0.970	0.970
		Standard error	0.000	0.030	0.030	0.030	0.030	0.030
Conversion	Zenith Fenestrated	Number at risk	42	37	28	21	21	18
		Cumulative events	0	0	0	0	0	0
		Cumulative censored	0	5	14	21	21	24
		Kaplan-Meier estimate	1.000	1.000	1.000	1.000	1.000	1.000
		Standard error	0.000	0.000	0.000	0.000	0.000	0.000
	Zenith AAA	Number at risk	33	32	30	30	28	17
		Cumulative events	0	1	1	1	1	1
		Cumulative censored	0	0	2	2	4	15
		Kaplan-Meier estimate	1.000	0.970	0.970	0.970	0.970	0.970
		Standard error	0.000	0.030	0.030	0.030	0.030	0.030

\* 1 case of death that the CEC was unable to adjudicate, which was conservatively counted as AAA-related for the purpose of analysis.

**Table 6.17** reports the Kaplan-Meier survival estimates for freedom from any pre-specified cardiovascular, pulmonary, renal, GI, wound, neurologic, and vascular event reported by the investigative sites, as compared to Zenith AAA. The procedure-related incidence (i.e., within 30 days) of cardiovascular, pulmonary, gastrointestinal, wound, and neurologic events appeared comparable between Zenith Fenestrated and Zenith AAA, and the occurrence of events in these categories beyond 30 days was not surprising given the pre-existing comorbid conditions of the patient populations. The percent of patients experiencing renal events or vascular events within 30 days trended higher for Zenith Fenestrated compared to Zenith AAA patients, the details of which are provided in **Tables 6.18** and **6.19**, respectively.

**Table 6.17 Kaplan-Meier estimates (freedom from morbidity, by category)**

Event	Group	Parameter	30 days	365 days	730 days	1095 days	1460 days	1825 days
Cardiovascular <sup>a</sup>	Zenith Fenestrated	Number at risk	40	30	21	15	15	10
		Cumulative events	2	6	7	8	8	10
		Cumulative censored	0	8	14	19	19	22
		Kaplan-Meier estimate	0.952	0.854	0.817	0.766	0.766	0.656
		Standard error	0.033	0.055	0.064	0.078	0.078	0.098
	Zenith AAA	Number at risk	29	27	24	24	23	14
		Cumulative events	4	5	6	6	6	6
		Cumulative censored	0	1	3	3	4	13
		Kaplan-Meier estimate	0.879	0.848	0.817	0.817	0.817	0.817
		Standard error	0.057	0.062	0.068	0.068	0.068	0.068
Pulmonary <sup>b</sup>	Zenith Fenestrated	Number at risk	41	32	24	18	17	12
		Cumulative events	1	4	4	5	5	6
		Cumulative censored	0	6	14	19	20	24
		Kaplan-Meier estimate	0.976	0.903	0.903	0.855	0.855	0.798
		Standard error	0.024	0.046	0.046	0.064	0.064	0.081
	Zenith AAA	Number at risk	33	32	29	29	28	17
		Cumulative events	0	0	1	1	1	1
		Cumulative censored	0	1	3	3	4	15
		Kaplan-Meier estimate	1.000	1.000	0.969	0.969	0.969	0.969
		Standard error	0.000	0.000	0.031	0.031	0.031	0.031
Renal <sup>c</sup>	Zenith Fenestrated	Number at risk	37	30	21	15	14	10
		Cumulative events	5	6	8	9	10	10
		Cumulative censored	0	6	13	18	18	22
		Kaplan-Meier estimate	0.881	0.856	0.791	0.742	0.692	0.692
		Standard error	0.050	0.054	0.067	0.079	0.088	0.088
	Zenith AAA	Number at risk	33	31	29	29	27	16
		Cumulative events	0	1	1	1	1	1
		Cumulative censored	0	1	3	3	5	16
		Kaplan-Meier estimate	1.000	0.970	0.970	0.970	0.970	0.970
		Standard error	0.000	0.030	0.030	0.030	0.030	0.030
GI <sup>d</sup>	Zenith Fenestrated	Number at risk	40	33	25	20	19	14
		Cumulative events	2	2	2	2	2	2
		Cumulative censored	0	7	15	20	21	26
		Kaplan-Meier estimate	0.952	0.952	0.952	0.952	0.952	0.952
		Standard error	0.033	0.033	0.033	0.033	0.033	0.033
	Zenith AAA	Number at risk	33	32	30	30	28	17
		Cumulative events	0	0	0	0	0	0
		Cumulative censored	0	1	3	3	5	16
		Kaplan-Meier estimate	1.000	1.000	1.000	1.000	1.000	1.000
		Standard error	0.000	0.000	0.000	0.000	0.000	0.000
Wound <sup>e</sup>	Zenith Fenestrated	Number at risk	41	32	24	19	18	13
		Cumulative events	1	3	3	3	3	3
		Cumulative censored	0	7	15	20	21	26
		Kaplan-Meier estimate	0.976	0.927	0.927	0.927	0.927	0.927
		Standard error	0.024	0.041	0.041	0.041	0.041	0.041
	Zenith AAA	Number at risk	32	31	29	29	26	15
		Cumulative events	1	1	1	1	2	2
		Cumulative censored	0	1	3	3	5	16
		Kaplan-Meier estimate	0.970	0.970	0.970	0.970	0.936	0.936
		Standard error	0.030	0.030	0.030	0.030	0.044	0.044
Neurologic <sup>f</sup>	Zenith Fenestrated	Number at risk	42	35	26	19	18	13
		Cumulative events	0	0	0	1	1	1
		Cumulative censored	0	7	16	22	23	28
		Kaplan-Meier estimate	1.000	1.000	1.000	0.950	0.950	0.950
		Standard error	0.000	0.000	0.000	0.049	0.049	0.049
	Zenith AAA	Number at risk	33	32	28	28	26	15
		Cumulative events	0	0	2	2	2	2
		Cumulative censored	0	1	3	3	5	16
		Kaplan-Meier estimate	1.000	1.000	0.934	0.934	0.934	0.934
		Standard error	0.000	0.000	0.045	0.045	0.045	0.045
Vascular <sup>g</sup>	Zenith Fenestrated	Number at risk	34	28	20	17	16	10
		Cumulative events	8	8	8	8	8	9
		Cumulative censored	0	6	14	17	18	23
		Kaplan-Meier estimate	0.810	0.810	0.810	0.810	0.810	0.759
		Standard error	0.061	0.061	0.061	0.061	0.061	0.075
	Zenith AAA	Number at risk	30	28	26	26	23	13
		Cumulative events	3	4	4	4	5	5
		Cumulative censored	0	1	3	3	5	15
		Kaplan-Meier estimate	0.909	0.879	0.879	0.879	0.845	0.845
		Standard error	0.050	0.057	0.057	0.057	0.064	0.064

<sup>a</sup> Cardiovascular pre-specified events: cardiac ischemia requiring intervention, inotropic support, Q-wave MI, non-Q-wave MI, congestive heart failure (CHF), arrhythmia requiring intervention or new treatment, and medically intractable hypertension.

<sup>b</sup> Pulmonary pre-specified events: pneumonia requiring antibiotics, supplemental oxygen at discharge, ventilation (>24 hours and >72 hours), and re-intubation.

<sup>c</sup> Renal pre-specified events: renal failure requiring dialysis, renal insufficiency, renal infarct, and occlusion of fenestrated renal vessel.

<sup>d</sup> GI pre-specified events: bowel obstruction, bowel ischemia/mesenteric ischemia, paralytic ileus >4 days, and aorto-enteric fistula.

<sup>e</sup> Wound pre-specified events: incisional hernia, wound infection requiring antibiotic treatment, wound complication requiring return to the operating room (OR), seroma requiring treatment, lymph fistula, and wound breakdown requiring debridement.

<sup>f</sup> Neurologic pre-specified events: transient ischemic attack (TIA)/reversible ischemic neurological deficit (RIND), stroke, spinal cord ischemia/paralysis.

<sup>g</sup> Vascular pre-specified events: embolization resulting in tissue loss or requiring intervention; limb thrombosis, aneurysm leak/rupture, pseudoaneurysm, increase in aneurysm size by >0.5 cm, vascular injury, and post-procedure transfusion.

Given the involvement of the renal arteries in the repair with a fenestrated graft, there is an expected higher risk for renal adverse events as compared to use of a standard, non-fenestrated endograft. Renal morbidity was therefore closely monitored during the study by evaluating several pre-specified events (renal infarct, renal insufficiency, renal failure requiring dialysis, renal artery occlusion). **Table 6.18** reports the Kaplan-Meier estimates for freedom from the individual pre-specified renal morbid events, as compared to Zenith AAA. Also included in **Table 6.18** is the Kaplan-Meier estimate for freedom from stenosis/compression events that required reintervention, as also counted (as device/renal stenosis) in **Table 6.24** (Reasons for Secondary Intervention).

There were five incidental findings of renal infarct on imaging (without an associated clinical event). Each occurred in a patient from the Zenith Fenestrated group that had some degree of calcification/thrombus in the sealing zone (one also with a history of infarct and coverage of an accessory renal artery at the time of the procedure).

Renal insufficiency was observed in Zenith Fenestrated (n=3) as well as Zenith AAA (n=1) patients. One of the Zenith Fenestrated patients with renal insufficiency was also the only patient in either group to require dialysis, which the CEC judged to be unrelated to AAA repair due to underlying renal dysfunction. Renal insufficiency in one of the other patients from the Zenith Fenestrated group was also judged unrelated to AAA repair by the CEC due to underlying renal dysfunction.

There were two reports of renal occlusion in the Zenith Fenestrated group, neither of which was associated with graft migration. One required reintervention and occurred in a patient with suboptimal placement of the renal stent in the middle/upper portion of the fenestration.

There were seven patients with stenosis/compression events requiring secondary intervention (one associated with migration), four of which had a peak systolic velocity <280 cm/s prior to reintervention.

**Table 6.18 Kaplan-Meier estimates for freedom from pre-specified renal events (regardless of whether determined by the clinical events committee to be related or unrelated to AAA repair)**

Event	Group	Parameter	30 days	365 days	730 days	1095 days	1460 days	1825 days
Renal infarct*	Zenith Fenestrated	Number at risk	37	31	24	19	18	14
		Cumulative events	5 <sup>a,b,c,d,e</sup>	5	5	5	5	5
		Cumulative censored	0	6	13	18	19	23
		Kaplan-Meier estimate	0.881	0.88	0.881	0.881	0.881	0.881
		Standard error	0.050	0.050	0.050	0.050	0.050	0.050
	Zenith AAA	Number at risk	33	32	30	30	28	17
		Cumulative events	0	0	0	0	0	0
		Cumulative censored	0	1	3	3	5	16
		Kaplan-Meier estimate	1.000	1.000	1.000	1.000	1.000	1.000
		Standard error	0.000	0.000	0.000	0.000	0.000	0.000
Renal insufficiency** (on two or more follow-up tests)	Zenith Fenestrated	Number at risk	42	35	25	18	16	11
		Cumulative events	0	0	1 <sup>f</sup>	2 <sup>g</sup>	3 <sup>h</sup>	3
		Cumulative censored	0	7	16	22	23	28
		Kaplan-Meier estimate	1.000	1.000	0.963	0.912	0.862	0.862
		Standard error	0.000	0.000	0.036	0.060	0.075	0.075
	Zenith AAA	Number at risk	33	31	29	29	27	16
		Cumulative events	0	1	1	1	1	1
		Cumulative censored	0	1	3	3	5	16
		Kaplan-Meier estimate	1.000	0.970	0.970	0.970	0.970	0.970
		Standard error	0.000	0.030	0.030	0.030	0.030	0.030
Dialysis***	Zenith Fenestrated	Number at risk	42	35	26	20	18	13
		Cumulative events	0	0	0	0	1 <sup>i</sup>	1
		Cumulative censored	0	7	16	22	23	28
		Kaplan-Meier estimate	1.000	1.000	1.000	1.000	0.947	0.947
		Standard error	0.000	0.000	0.000	0.000	0.051	0.051
	Zenith AAA	Number at risk	33	32	30	30	28	17
		Cumulative events	0	0	0	0	0	0
		Cumulative censored	0	1	3	3	5	16
		Kaplan-Meier estimate	1.000	1.000	1.000	1.000	1.000	1.000
		Standard error	0.000	0.000	0.000	0.000	0.000	0.000
Renal occlusion	Zenith Fenestrated	Number at risk	42	34	24	18	18	13
		Cumulative events	0	1 <sup>j</sup>	2 <sup>k</sup>	2	2	2
		Cumulative censored	0	7	16	22	22	27
		Kaplan-Meier estimate	1.000	0.975	0.945	0.945	0.945	0.945
		Standard error	0.000	0.025	0.038	0.038	0.038	0.038
	Zenith AAA	Number at risk	33	32	30	30	28	17
		Cumulative events	0	0	0	0	0	0
		Cumulative censored	0	1	3	3	5	16
		Kaplan-Meier estimate	1.000	1.000	1.000	1.000	1.000	1.000
		Standard error	0.000	0.000	0.000	0.000	0.000	0.000
Stenosis/compression requiring reintervention	Zenith Fenestrated	Number at risk	41	33	24	18	16	11
		Cumulative events	1 <sup>l</sup>	3 <sup>l,m</sup>	4 <sup>n</sup>	5 <sup>o</sup>	6 <sup>p</sup>	7 <sup>p</sup>
		Cumulative censored	0	6	14	19	20	24
		Kaplan-Meier estimate	0.976	0.927	0.897	0.850	0.800	0.747
		Standard error	0.024	0.040	0.049	0.065	0.078	0.089

\* As reported by sites, regardless of whether confirmed by core lab.

\*\* Creatinine rise >2 mg/dl and >30% from baseline.

\*\*\* Although dialysis in patients with a normal pre-operative renal function was pre-specified, the analysis was performed with consideration to dialysis in any patient.

<sup>a</sup> (0111011) Incidental finding on imaging without an associated clinical event at the time of reporting; patient noted to have (mild) thrombus and calcification in the seal zone on pre-procedure imaging.

<sup>b</sup> (0511009) Incidental finding on imaging without an associated clinical event at the time of reporting; patient noted to have (mild) thrombus and calcification in the seal zone on pre-procedure imaging; patient also with bilateral renal artery stenosis (uncovered, balloon-expandable 316L stainless steel biliary stent) treated with bilateral angioplasty and stenting. No evidence of graft migration or stent deformation, suggesting the stenosis may have resulted from local thrombus formation or intimal hyperplasia within the stented segment.

<sup>c</sup> (0511010) Incidental finding on imaging without an associated clinical event at the time of reporting; patient noted to have (moderate) thrombus and (mild) calcification in the seal zone on pre-procedure imaging; patient also with hydronephrosis on POD# 237.

<sup>d</sup> (1111002) Incidental finding on imaging without an associated clinical event at the time of reporting; patient noted to have (moderate) calcification in the seal zone as well as renal infarct on pre-procedure imaging, and also underwent intentional coverage of an accessory renal artery at the time of aneurysm repair.

<sup>e</sup> (1111007) Incidental finding on imaging without an associated clinical event at the time of reporting; patient noted to have (mild) calcification in the seal zone on pre-procedure imaging; patient also with renal insufficiency (creatinine rise >2 mg/dl and >30% from baseline) on a single follow-up (at POD# 424).

<sup>f</sup> (0211010) Patient with a decrease in GFR >30% at the 24-month follow-up, but not on subsequent follow-up at 36 months. The patient underwent secondary intervention to treat a Type II endoleak (on POD# 239) and hospitalization for congestive heart failure treated with Lasix (on POD# 314), but there were no reports of renal artery stenosis or occlusion at any time point.

<sup>g</sup> (0111006) Patient also with renal calculi noted on POD# 214; all events (renal calculi, renal insufficiency, and dialysis) were determined un-related to AAA repair by the CEC.

<sup>h</sup> (0421001) Patient also with stenosis of an unstented renal artery proximal to the graft margin, which underwent stenting on POD# 1221; all events (renal insufficiency and stenosis) were determined un-related to AAA repair by the CEC.

<sup>i</sup> (0211008) No evidence of graft migration, but with compression of the fenestration stent (uncovered, balloon-expandable 316L stainless steel biliary/renal stent), due likely to suboptimal deployment of the renal stent into the middle/upper portion of the fenestration; patient underwent secondary intervention (ilio-renal bypass).

<sup>j</sup> (0611003) No evidence of graft migration or fenestration stent compression (uncovered, balloon-expandable 316L stainless steel biliary/iliac stent), suggesting occlusion likely resulted from the development and progression of thrombus or intimal hyperplasia within the stented vessel; patient did not undergo secondary intervention; patient also with site-reported atrophy of kidney (on POD# 177).

<sup>k</sup> (0211011) Angiography revealed that the right renal artery was severely stenosed. Attempted cannulation was unsuccessful, as the fenestration stent (Zenith® Alignment Stent) was not flared at the time of the initial implant procedure. No evidence of graft migration or stent deformation, suggesting the stenosis may have resulted from local thrombus formation or intimal hyperplasia within the stented segment.

<sup>l</sup> (0111008) Right renal artery stenosis (uncovered, balloon-expandable 316L stainless steel biliary stent) was treated by angioplasty and additional stent placement. No evidence of graft migration or stent deformation, suggesting the stenosis may have resulted from local thrombus formation or intimal hyperplasia within the stented segment.

<sup>m</sup> (0111014) Bilateral renal artery stenoses (uncovered, balloon-expandable 316L stainless steel biliary stent) were treated by angioplasty and additional stent placement. No evidence of graft migration or stent deformation, suggesting the stenosis may have resulted from local thrombus formation or intimal hyperplasia within the stented segment.

<sup>n</sup> (0211007) Right renal artery stenosis (uncovered, balloon-expandable 316L stainless steel biliary/renal stent) was treated by angioplasty and additional stent placement. No evidence of graft migration or stent deformation, suggesting the stenosis may have resulted from local thrombus formation or intimal hyperplasia within the stented segment.

<sup>o</sup> (0511006) Right renal artery stent compression and subsequent stenosis (uncovered, balloon-expandable 316L stainless steel biliary stent) treated by angioplasty and stent placement. Compression of fenestration stent associated with graft migration (approximately 12 mm by 24 months) due likely to longitudinal progression of disease with further aortic neck dilatation.

<sup>p</sup> (0511003) Left renal artery stenosis (uncovered, balloon-expandable 316L stainless steel biliary stent) from slight compression of fenestration stent (with no measurable graft movement > 5 mm) treated by angioplasty and stent placement.

Given the expected longer procedure times for Zenith Fenestrated compared to Zenith AAA (252.2 ± 75.5 minutes for Zenith Fenestrated vs. 160.6 ± 60.6 minutes for Zenith AAA) and correspondingly greater amount of procedural blood loss (537.4 ± 498.5 cc for Zenith Fenestrated vs. 281.2 ± 192.4 cc for Zenith AAA), the need for post-procedure transfusion was also greater, as shown in **Table 6.19**, which provides the Kaplan-Meier estimates for freedom from individual pre-specified vascular events occurring in either the Zenith Fenestrated or Zenith AAA groups.

**Table 6.19 Kaplan-Meier estimates for freedom from pre-specified vascular events occurring in either Zenith Fenestrated or Zenith AAA**

Event	Group	Parameter	30 days	365 days	730 days	1095 days	1460 days	1825 days
Embolization resulting in tissue loss or requiring intervention	Zenith Fenestrated	Number at risk	41	34	25	19	18	13
		Cumulative events	1	1	1	1	1	1
		Cumulative censored	0	7	16	22	23	28
		Kaplan-Meier estimate	0.976	0.976	0.976	0.976	0.976	0.976
		Standard error	0.024	0.024	0.024	0.024	0.024	0.024
	Zenith AAA	Number at risk	33	32	30	30	28	17
		Cumulative events	0	0	0	0	0	0
		Cumulative censored	0	1	3	3	5	16
		Kaplan-Meier estimate	1.000	1.000	1.000	1.000	1.000	1.000
		Standard error	0.000	0.000	0.000	0.000	0.000	0.000
Limb thrombosis	Zenith Fenestrated	Number at risk	42	35	26	20	19	14
		Cumulative events	0	0	0	0	0	0
		Cumulative censored	0	7	16	22	23	28
		Kaplan-Meier estimate	1.000	1.000	1.000	1.000	1.000	1.000
		Standard error	0.000	0.000	0.000	0.000	0.000	0.000
	Zenith AAA	Number at risk	33	31	29	29	27	16
		Cumulative events	0	1	1	1	1	1
		Cumulative censored	0	1	3	3	5	16
		Kaplan-Meier estimate	1.000	0.970	0.970	0.970	0.970	0.970
		Standard error	0.000	0.030	0.030	0.030	0.030	0.030
Post-procedure transfusion	Zenith Fenestrated	Number at risk	34	28	20	17	16	10
		Cumulative events	8	8	8	8	8	9
		Cumulative censored	0	6	14	17	18	23
		Kaplan-Meier estimate	0.810	0.810	0.810	0.810	0.810	0.759
		Standard error	0.061	0.061	0.061	0.061	0.061	0.075
	Zenith AAA	Number at risk	30	29	27	27	24	14
		Cumulative events	3	3	3	3	4	4
		Cumulative censored	0	1	3	3	5	15
		Kaplan-Meier estimate	0.909	0.909	0.909	0.909	0.875	0.875
		Standard error	0.050	0.050	0.050	0.050	0.058	0.058

**Effectiveness Data**

**Table 6.20** reports the percent of patients with an increase (> 5 mm), decrease (> 5 mm), or no change (≤ 5 mm) in aneurysm size at each follow-up time point, as compared to pre-discharge based on the results from core lab analysis. There were two cases of aneurysm expansion, both of which occurred in patients with a persistent Type II endoleak.

**Table 6.20 Change in aneurysm size based on results from core lab analysis**

Item	1-month	6-month	12-month	24-month	36-month	48-month	60-month
Increase (> 5mm)	0.0% (0/39)	0.0% (0/38)	0.0% (0/29)	0.0% (0/26)	6.7% (1/15) <sup>1</sup>	6.3% (1/16) <sup>2</sup>	0.0% (0/11)
Decrease (> 5mm)	2.6% (1/39)	50.0% (19/38)	69.0% (20/29)	69.2% (18/26)	73.3% (11/15)	75.0% (12/16)	72.7% (8/11)
No change (≤ 5mm)	97.4% (38/39)	50.0% (19/38)	31.0% (9/29)	30.8% (8/26)	20.0% (3/15)	18.8% (3/16)	27.3% (3/11)

<sup>1</sup> Patient 0511004 had a persistent Type II endoleak requiring secondary intervention at 1393 days post-procedure.

<sup>2</sup> Patient 0211010 had a persistent Type II endoleak requiring secondary intervention at 239 days post-procedure, but the Type II endoleak was still evident on the 48-month exam.

**Table 6.21** reports endoleaks by type, as assessed by the core lab at each exam period. Except for two endoleaks of unknown type, all other reported endoleaks were Type II.

**Table 6.21 Endoleak based on results from core lab analysis**

Type	Pre-discharge	1-month	6-month	12-month	24-month	36-month	48-month	60-month
Any (new only)	32.5% (13/40)	2.4% (1/41)	5.3% (2/38)	0.0% (0/29)	0.0% (0/26)	0.0% (0/16)	0.0% (0/16)	0.0% (0/11)
Any (new and persistent)	32.5% (13/40)	22.0% (9/41)	23.7% (9/38)	27.6% (8/29)	15.4% (4/26)	12.5% (2/16)	12.5% (2/16)	0.0% (0/11)
Multiple	0.0% (0/40)	0.0% (0/41)	0.0% (0/38)	0.0% (0/29)	0.0% (0/26)	0.0% (0/16)	0.0% (0/16)	0.0% (0/11)
Proximal Type I	0.0% (0/40)	0.0% (0/41)	0.0% (0/38)	0.0% (0/29)	0.0% (0/26)	0.0% (0/16)	0.0% (0/16)	0.0% (0/11)
Distal Type I	0.0% (0/40)	0.0% (0/41)	0.0% (0/38)	0.0% (0/29)	0.0% (0/26)	0.0% (0/16)	0.0% (0/16)	0.0% (0/11)
Type II	30.0% (12/40)	22.0% (9/41)	21.1% (8/38)	27.6% (8/29)	15.4% (4/26)	12.5% (2/16)	12.5% (2/16)	0.0% (0/11)
Type III	0.0% (0/40)	0.0% (0/41)	0.0% (0/38)	0.0% (0/29)	0.0% (0/26)	0.0% (0/16)	0.0% (0/16)	0.0% (0/11)
Type IV	0.0% (0/40)	0.0% (0/41)	0.0% (0/38)	0.0% (0/29)	0.0% (0/26)	0.0% (0/16)	0.0% (0/16)	0.0% (0/11)
Unknown	2.5% (1/40)	0.0% (0/41)	2.6% (1/38)	0.0% (0/29)	0.0% (0/26)	0.0% (0/16)	0.0% (0/16)	0.0% (0/11)

**Table 6.22** reports the percent of patients with CEC-confirmed radiographic migration (≥10 mm) or clinically significant migration (measurable movement of the stent-graft >5 mm and that developed a type I endoleak or renal stenosis/occlusion with demonstrable deformation of the mating renal stent by core lab) at each follow-up time point (date of first occurrence). There were two reports of migration, one of which required secondary intervention (due to associated renal stenosis). Neither case was associated with aneurysm growth or endoleak. Both cases of migration occurred in patients with evidence of disease progression at follow-up (without aneurysm pressurization).

**Table 6.22 CEC-confirmed migration (date of first occurrence)**

Item	1-month	6-month	12-month	24-month	36-month	48-month	60-month
Radiographic migration	0.0% (0/40)	0.0% (0/38)	0.0% (0/30)	3.6% <sup>1</sup> (1/28)	0.0% (0/16)	0.0% (0/16)	9.1% <sup>2</sup> (1/11)
Clinically significant migration	0.0% (0/40)	0.0% (0/38)	0.0% (0/30)	3.6% <sup>1</sup> (1/28)	0.0% (0/16)	0.0% (0/16)	0.0% (0/11)

<sup>1</sup> Patient 0511006 with renal stenosis from associated stent compression (uncovered, balloon-expandable 316L stainless steel biliary stent) requiring secondary intervention. Longitudinal progression of disease with further aortic neck dilatation likely resulted in migration. There was no endoleak or increase in aneurysm size in this patient. The total amount of graft movement detected at the time of the clinically significant migration was approximately 12 mm (relative to the celiac).

<sup>2</sup> Patient 0511008 was without any associated renal stenosis requiring reintervention and additionally did not have any endoleak or increase in aneurysm size. Longitudinal progression of disease with further aortic neck dilatation likely resulted in migration. The total amount of graft movement was approximately 10 mm (relative to the celiac), which retrospectively occurred over 60 months. No interventions have been performed on this patient.

Device integrity observations are summarized in **Table 6.23**. Losses in device integrity included three patients with barb separation, one patient with possible fenestration stent fracture, and one patient with seal stent and fenestration stent fracture (who also had evidence of disease progression during follow-up in the absence of aneurysm pressurization). None of the integrity findings were associated with adverse clinical sequelae or the need for reintervention. Although not associated with a device integrity loss (i.e., fracture), other observations included 4 cases with fenestration stent deformation/compression (1 also with migration, 3 without migration), 2 of which underwent reintervention to treat stenosis.

**Table 6.23 Device integrity findings by core lab (time of first occurrence)**

Finding	Pre-discharge	1-month	6-month	12-month	24-month	36-month	48-month	60-month
<b>Stent graft</b>								
Barb separation	0.0% (0/42)	0.0% (0/41)	2.6% (1/39) <sup>1</sup>	3.4% (1/29) <sup>2</sup>	3.8% (1/26) <sup>3</sup>	0.0% (0/16)	0.0% (0/17)	0.0% (0/11)
Stent fracture (single)	0.0% (0/42)	0.0% (0/41)	0.0% (0/39)	3.4% (1/29) <sup>4</sup>	0.0% (0/26)	0.0% (0/16)	0.0% (0/17)	0.0% (0/11)
Stent fracture (multiple)	0.0% (0/42)	0.0% (0/41)	0.0% (0/39)	0.0% (0/29)	0.0% (0/26)	0.0% (0/16)	0.0% (0/17)	0.0% (0/11)
Component separation	0.0% (0/42)	0.0% (0/41)	0.0% (0/39)	0.0% (0/29)	0.0% (0/26)	0.0% (0/16)	0.0% (0/17)	0.0% (0/11)
Limb separation	0.0% (0/42)	0.0% (0/41)	0.0% (0/39)	0.0% (0/29)	0.0% (0/26)	0.0% (0/16)	0.0% (0/17)	0.0% (0/11)
Stent-to-graft separation	0.0% (0/42)	0.0% (0/41)	0.0% (0/39)	0.0% (0/29)	0.0% (0/26)	0.0% (0/16)	0.0% (0/17)	0.0% (0/11)
Other	0.0% (0/42)	0.0% (0/41)	0.0% (0/39)	0.0% (0/29)	0.0% (0/26)	0.0% (0/16)	0.0% (0/17)	0.0% (0/11)
<b>Fenestration stent</b>								
Fracture	0.0% (0/42)	0.0% (0/41)	2.6% (1/39) <sup>5</sup>	3.4% (1/29) <sup>6</sup>	0.0% (0/26)	0.0% (0/16)	0.0% (0/17)	0.0% (0/11)
Separation	0.0% (0/42)	0.0% (0/41)	0.0% (0/39)	0.0% (0/29)	0.0% (0/26)	0.0% (0/16)	0.0% (0/17)	0.0% (0/11)
Other	0.0% (0/42)	0.0% (0/41)	7.7% (3/39) <sup>6,7,8</sup>	3.4% (1/29) <sup>9</sup>	0.0% (0/26)	0.0% (0/16)	0.0% (0/17)	0.0% (0/11)

<sup>1</sup> Patient 0421003: Separation of a single fixation barb. No clinical sequelae related to the barb separation have been reported.

<sup>2</sup> Patient 0111009: Separation of a single fixation barb. No clinical sequelae related to the barb separation have been reported.

<sup>3</sup> Patient 0511008: Separation of two barbs. No clinical sequelae related to the barb separation have been reported, although radiographic migration (approximately 10 mm over 5 years) was observed and was due likely to longitudinal progression of disease with further aortic neck dilatation.

<sup>4</sup> Patient 0411001: Fracture of sealing stent (at the distal edge of the scallop fenestration) and left renal fenestration stent (uncovered, balloon-expandable 316L stainless steel biliary/iliac stent), but in a patient with progressive aneurysmal disease within and proximal to the treated segment, which likely resulted in uncharacteristic tension/loading of the stents. No subsequent renal events, endoleak, or secondary interventions reported in this patient.

<sup>5</sup> Patient 0511010: Fracture of left renal fenestration stent (Zenith® Alignment Stent) not readily confirmed based on subsequent bench top CT imaging studies that showed the same appearance of fracture, but in an entirely intact stent.

<sup>6</sup> Patient 1111011: Deformation of fenestration stent (Zenith® Alignment Stent) with no measurable graft movement > 5 mm and not requiring secondary intervention.

<sup>7</sup> Patient 0511003: Slight compression of fenestration stent (uncovered, balloon-expandable 316L stainless steel biliary stent) with no measurable graft movement > 5 mm. Angioplasty and stent placement was performed 1539 days post-procedure to treat stenosis.

<sup>8</sup> Patient 0511007: Slight compression of fenestration stent (uncovered, balloon-expandable 316L stainless steel biliary stent) with no measurable graft movement > 5 mm and not requiring secondary intervention.

<sup>9</sup> Patient 0511006: Compression of fenestration stent (uncovered, balloon-expandable 316L stainless steel biliary stent) associated with graft migration (approximately 12 mm by 24 months) due likely to longitudinal progression of disease with further aortic neck dilatation. Angioplasty and stent placement were performed 883 days post-procedure to treat stenosis.

**Table 6.24** summarizes the site reported reasons for secondary intervention. Of the 11 patients who underwent a secondary intervention, 7 did so because of renal stenosis (1 associated with graft migration and stent deformation, 1 associated with stent deformation without migration). In 4 patients, the peak systolic velocity was <280 cm/s prior to reintervention. The other reported reasons for reintervention included renal occlusion in 1, Type II endoleak in 2, and suspected Type I endoleak in 1 (ruled out by angiogram).

**Table 6.24 Reasons for secondary intervention (as reported by site)**

Finding	0-30 days	31-365 days	366-730 days	731-1095 days	1096-1460 days	1461-1825 days
<b>Aneurysm rupture</b>	0	0	0	0	0	0
<b>Symptoms</b>	0	0	0	0	0	0
<b>Device/renal stenosis</b>	1 <sup>1</sup>	2 <sup>5,6</sup>	1 <sup>7</sup>	1 <sup>8</sup>	1 <sup>9</sup>	1 <sup>11</sup>
<b>Device migration</b>	0	0	0	0	0	0
<b>Device separation</b>	0	0	0	0	0	0
<b>Occlusion</b>	0	12	0	0	0	0
<b>Device kink</b>	0	0	0	0	0	0
<b>Infection</b>	0	0	0	0	0	0
<b>Endoleak</b>						
Type I proximal	0	1 <sup>3</sup>	0	0	0	0
Type I distal	0	0	0	0	0	0
Type IIA (vessel perfusion)	0	1 <sup>4</sup>	0	0	1 <sup>10</sup>	0
Type IIB (vessel perfusion)	0	0	0	0	0	0
Type III (graft overlap joint)	0	0	0	0	0	0
Type IV (through graft body)	0	0	0	0	0	0
unknown	0	0	0	0	0	0
<b>Other</b>	0	0	0	1 <sup>8</sup>	1 <sup>10</sup>	0

<sup>1</sup> Patient 0211011: Angiography revealed that the right renal artery was severely stenosed. Attempted cannulation was unsuccessful, as the fenestration stent (Zenith® Alignment Stent) was not flared at the time of the initial implant procedure. No evidence of graft migration or stent deformation, suggesting the stenosis may have resulted from local thrombus formation or intimal hyperplasia within the stented segment.

<sup>2</sup> Patient 0211008: Angiogram demonstrated occluded left renal artery with proximal compression of the left renal stent (uncovered, balloon-expandable 316L stainless steel biliary/renal stent), which was treated with iliofemoral bypass. Compression without evidence of migration due likely to suboptimal deployment of the renal stent into the middle/upper portion of the fenestration

<sup>3</sup> Patient 0411004: Selective left renal angiography was performed for suspected Type I endoleak. No type I endoleak was identified; however, Type II endoleak was identified but not treated.

<sup>4</sup> Patient 0211010: Persistent Type II endoleak was treated by coil embolization.

<sup>5</sup> Patient 0111008: Right renal artery stenosis (uncovered, balloon-expandable 316L stainless steel biliary stent) was treated by angioplasty and additional stent placement. No evidence of graft migration or stent deformation, suggesting the stenosis may have resulted from local thrombus formation or intimal hyperplasia within the stented segment.

<sup>6</sup> Patient 0111014: Bilateral renal artery stenoses (uncovered, balloon-expandable 316L stainless steel biliary stent) were treated by angioplasty and additional stent placement. No evidence of graft migration or stent deformation, suggesting the stenosis may have resulted from local thrombus formation or intimal hyperplasia within the stented segment.

<sup>7</sup> Patient 0211007: Right renal artery stenosis (uncovered, balloon-expandable 316L stainless steel biliary/renal stent) was treated by angioplasty and additional stent placement. No evidence of graft migration or stent deformation, suggesting the stenosis may have resulted from local thrombus formation or intimal hyperplasia within the stented segment.

<sup>8</sup> Patient 0511006: Right renal artery stent compression and subsequent stenosis (uncovered, balloon-expandable 316L stainless steel biliary stent) treated by angioplasty and stent placement. Compression of fenestration stent associated with graft migration (approximately 12 mm by 24 months) due likely to longitudinal progression of disease with further aortic neck dilatation.

<sup>9</sup> Patient 0511009: Bilateral renal artery stenosis (uncovered, balloon-expandable 316L stainless steel biliary stent) was treated by bilateral angioplasty and stenting. No evidence of graft migration or stent deformation, suggesting the stenosis may have resulted from local thrombus formation or intimal hyperplasia within the stented segment.

<sup>10</sup> Patient 0511004: Underwent diagnostic angiogram for suspect Type Ila and Type III endoleak, which were not detected at 1137 days post-procedure; additional intervention performed 1393 days post-procedure, involving laparotomy, suture ligation of IMA, and exploration of aneurysm sac as treatment for Type II endoleak with aneurysm growth.

<sup>11</sup> Patient 0511003: Left renal artery stenosis (uncovered, balloon-expandable 316L stainless steel biliary stent) from slight compression of fenestration stent (with no measurable graft movement > 5 mm) treated by angioplasty and stent placement.

### Summary

This study enrolled 42 patients treated with the Zenith Fenestrated AAA Endovascular Graft, a line extension of the Zenith AAA Endovascular Graft that is customized to the individual anatomy of patients having an infrarenal aortic neck length that is too short for the standard endograft. A variety of fenestration/scallop configurations were utilized, the most frequent of which was 2 small fenestrations and 1 scallop. A total of 111 vessels were targeted by either a fenestration or scallop, 78 of which received a fenestration stent (all stented vessels were main renal arteries accommodated by either a small fenestration or a scallop), including 21 vessels (11 patients) receiving 22 Zenith Alignment Stents. All devices deployed successfully in the intended location, and all graft components and vessels targeted by a fenestration were patent upon completion of deployment, yielding a technical success rate of 100%.

The primary safety and effectiveness data showed that the 6-month treatment success rate for Zenith Fenestrated (97.5%) was similar to that for matched patients treated with Zenith AAA (95%).

There were no ruptures or conversions following treatment with Zenith Fenestrated at any time point. Only one death was counted as AAA-related because the cause was unknown and the CEC was therefore unable to adjudicate it – all other deaths in the Zenith Fenestrated group (3) were determined unrelated to AAA-repair by the CEC.

Pre-specified renal adverse events included renal infarct, renal insufficiency, renal failure requiring dialysis, and occlusion of a fenestrated renal vessel. There were five patients with renal infarct (none were associated with a clinical event), each of which occurred in a patient with some degree of either thrombus or calcification in the seal zone (as well as a history of infarct and coverage of an accessory renal in one). Two of three patients with renal insufficiency in the Zenith Fenestrated group had renal dysfunction prior to treatment and were considered unrelated to AAA-repair by the CEC, one of which was also the only patient in the Zenith Fenestrated group requiring dialysis (also unrelated according to the CEC). Two patients developed occlusion of a fenestrated renal vessel (neither was associated with graft migration), one of which had evidence of fenestration stent compression (from suboptimal stent placement in the mid/upper portion of the fenestration) that required reintervention.

There were no reports of Type I or Type III endoleak, and the only reports of aneurysm growth (2) occurred in patients with a Type II endoleak. There were 2 reports of migration, both in patients with evidence of disease progression at follow-up (without aneurysm pressurization), one of which had



associated fenestration stent compression requiring secondary intervention. One patient was noted to have fracture of a fenestration stent as well as the seal stent on the Fenestrated Graft, neither of which resulted in endoleak, a clinical renal event, or the need for secondary intervention. This patient also exhibited disease progression at follow-up in the absence of aneurysm pressurization. A possible second patient with fenestration stent fracture was identified without a subsequent clinical renal event or need for reintervention.

The majority of patients who underwent reintervention following treatment with the Zenith Fenestrated Graft (7 of 11) did so for renal stenosis. There was evidence of fenestration stent deformation in 2 of 7 patients that underwent reintervention for renal stenosis (1 from suboptimal stent placement in the mid/upper portion of the fenestration, and 1 from migration due to progression of disease at follow-up in the absence of aneurysm pressurization).

#### Post-approval study

The purpose of this post-approval study was to evaluate the long-term safety and performance of the Zenith® Fenestrated AAA Endovascular Graft to treat aortic or aortoiliac aneurysms in patients with short infrarenal aortic necks by primarily evaluating aneurysm-related mortality.

This study enrolled 88 total patients (including 67 patients enrolled in the pivotal and continued/expanded access phases of the pre-approval study), with 21 new patients enrolled (prospectively or retrospectively) from 6 sites that were randomly selected from the pool of institutions that used the standard (nonfenestrated) Zenith® AAA Endovascular Graft, did not enroll patients in the pre-approval study, had completed the commercial training program, and had the necessary research infrastructure and staff to support the study, thus providing for a secondary assessment of commercial training program effectiveness.

Patients with anatomy amenable to endovascular repair and who met other enrollment criteria were included in the study. Patients who did not meet the criteria were excluded. A patient was considered enrolled in the study once the delivery system of the study device was inserted under the skin.

At the physician's discretion, the Zenith® Alignment Stent may have been used to stent visceral vessels targeted by a fenestration. Clinical and imaging follow-up was performed in accordance with standard of care through 5 years. The primary endpoint was aneurysm-related mortality; additional endpoints to be assessed included device patency, morbidity, rupture, conversion, secondary interventions, endoleak, device integrity, change in aneurysm size, and migration.

#### Summary of post-approval study methods

##### Primary endpoint

The primary objective of the study was to assess the long-term safety and performance of the Zenith® Fenestrated AAA Endovascular Graft and determine whether the 5-year aneurysm-related mortality is reasonable considering the treatment alternatives.

The primary endpoint was evaluated according to the hypothesis that patients treated with the Zenith® Fenestrated AAA Endovascular Graft will have a rate of aneurysm-related mortality at 5 years that is less than the performance goal of 18%, and is expressed as follows:

Null Hypothesis: the 5-year AAA-related mortality rate,  $\gamma$ , is greater than or equal to 18%. (Interpretation: the AAA-related mortality rate does not meet the performance goal.)

H0:  $\gamma \geq 18\%$

Alternative Hypothesis: the 5-year AAA-related mortality rate,  $\gamma$ , is less than 18%. (Interpretation: the AAA-related mortality rate does meet the performance goal.)

Ha:  $\gamma < 18\%$

##### Secondary endpoints

The secondary endpoints/objectives of the study were as follows:

- Perform additional assessments of device patency, morbidity, rupture, conversion, secondary interventions, endoleak, device integrity, change in aneurysm size, and migration.
- Evaluate commercial training program effectiveness as measured by the composite freedom from the following events at 30 days in up to 3 patients from each site: technical failure, loss of patency (by core laboratory analysis), rupture, secondary intervention, conversion, and type I or II endoleak (by core laboratory analysis). Results for patients enrolled by physicians who completed the commercial training program were compared to results for patients treated by physicians who did not complete the training program (i.e., physicians who enrolled patients in the pre-approval study).

##### Length of follow-up

Patients were followed through 5 years according to the schedule shown in Table 6.25.

Table 6.25 Study follow-up schedule

	Pre-procedure	Procedure	30 day	6 month (optional)	12 month <sup>3</sup>
Clinical exam	X		X	X	X
CT	X		X <sup>1</sup>	X <sup>1</sup>	X <sup>1</sup>
Device x-ray			X	X	X
Angiography	X <sup>2</sup>	X			
Renal duplex ultrasound	X		X	X	X
Blood tests to assess renal function (e.g., serum creatinine, BUN)	X		X	X	X

<sup>1</sup> Duplex ultrasound along with a non-contrast CT used to assess the aneurysm for those patients experiencing renal failure or who are otherwise unable to undergo contrast enhanced CT scan.

<sup>2</sup> Pre-procedure angiography required at the discretion of the implanting physician or film reviewer.

<sup>3</sup> Patients followed at yearly intervals through five years.

##### Follow-up rates

Table 6.26 reports the availability of follow-up clinical and imaging data submitted by sites for the patients enrolled in the study.

Table 6.26 Clinical and imaging follow-up rates<sup>a</sup>

Visit	Eligible for follow-up	Percent of data available			Adequate imaging to assess each parameter				Events occurring before next interval				
		Clinical	CT	KUB (device X-ray)	Size Increase	Endoleak	Migration	Fracture	Death	Conversion	Lost to follow-up (LTF)/ (LTF)/ (withdrawal)	Refused consent for 3-5 year follow-up	Not due for next visit
Post-procedure	88	100% (88/88)	76.1% (67/88)	78.4% (69/88)	N/A	69.3% (61/88)	73.9% (65/88)	84.1% (74/88)	1	0	0	N/A	0
1-month	87	98.9% (86/87)	96.6% (84/87)	74.7% (65/87)	73.6% (64/87)	86.2% (75/87)	94.3% (82/87)	94.3% (82/87)	2	0	2 <sup>b,c,d</sup>	N/A	0
6-month	83	96.4% (80/83)	94.0% (78/83)	78.3% (65/83)	91.6% (76/83)	84.3% (70/83)	90.4% (75/83)	92.8% (77/83)	1	0	2 <sup>c,d</sup>	N/A	0
12-month	80	95.0% (76/80)	93.8% (75/80)	71.3% (57/80)	88.8% (71/80)	78.8% (63/80)	90.0% (72/80)	90.0% (72/80)	2	0	2 <sup>e,f</sup>	N/A	0
24-month	76	92.1% (70/76)	93.4% (71/76)	68.4% (52/76)	84.2% (64/76)	72.4% (55/76)	84.2% (64/76)	89.5% (68/76)	4 <sup>g</sup>	0	3 <sup>g,h</sup>	6 <sup>i</sup>	0
36-month	63	93.7% (59/63)	93.7% (59/63)	61.9% (39/63)	87.3% (55/63)	76.2% (48/63)	88.9% (56/63)	90.5% (57/63)	0	0	2 <sup>h,v</sup>	N/A	0
48-month	61	91.8% (56/61)	86.9% (53/61)	60.7% (37/61)	85.2% (52/61)	60.7% (37/61)	78.7% (48/61)	88.5% (54/61)	0	0	7 <sup>j,k,o,p,s,u,v</sup>	N/A	0
60-month	54 <sup>t</sup>	94.4% (51/54) <sup>u</sup>	88.9% (48/54)	63.0% (34/54) <sup>v</sup>	81.5% (44/54)	61.1% (33/54)	75.9% (41/54)	85.2% (46/54)	N/A	N/A	N/A	N/A	N/A

<sup>a</sup> Data are from the sites through December 11, 2020.

<sup>b</sup> One patient (0111010) did not have a 1-month follow-up exam, and this patient was later lost to follow-up 37 days after the procedure. The site identified the patient death through the social security death index 761 days after the procedure and thus this patient has been moved to the death column.

<sup>c</sup> One patient (0411002) did not have a 6-month follow-up exam, and this patient was later lost to follow-up 326 days after the procedure.

<sup>d</sup> One patient (0911115) did not have a 12-month follow-up exam and withdrew 345 days after the procedure.

<sup>e</sup> One patient (0911102) did not have a 12-month follow-up exam, and this patient later withdrew 442 days after the procedure.

<sup>f</sup> One patient (1111009) did not have a 24-month follow-up exam, and this patient later withdrew 930 days after the procedure.

<sup>g</sup> One patient (1111007) did not have a 12-month or 24-month follow-up exam, and this patient was later lost to follow-up 980 days after the procedure.

<sup>h</sup> One patient (0211008) did not have a 24-month or 36-month follow-up exam, and this patient was later lost to follow-up 1170 days after the procedure.

<sup>i</sup> One patient (0611002) did not have a 48-month follow-up exam, and this patient later withdrew 1489 days after the procedure because the distance to travel for the follow-up visits was too far.

<sup>j</sup> One patient (0511007) refused to return for the 60-month follow-up visit, and this patient later withdrew 1869 days after the procedure.

<sup>k</sup> One patient (0111016) withdrew from the study 1629 days after the procedure due to entering hospice care and dealing with longstanding cancer issues.

<sup>l</sup> Six patients (0111007, 0111008, 0111011, 0111014, 0411007, and 0611001) refused to consent to 3 5 year data collection.

<sup>m</sup> One patient (1350007) did not receive the device and was last seen for the 30-day follow-up visit 43 days after the attempted procedure.

<sup>n</sup> One patient (1350001) was withdrawn from the study by the principal investigator 779 days after the procedure because the patient was incarcerated. Vital status was confirmed by the site 2523 days after the procedure on July 02, 2020.

<sup>o</sup> One patient (0611101) did not have a 48-month follow-up exam, and this patient was later lost to follow-up 1574 days after the procedure.

<sup>p</sup> One patient (0911107) did not have a 48-month follow-up exam and was later withdrawn from the study by the principal investigator 1708 days after the procedure due to being noncompliant with the study follow-up schedule. This patient later returned to the hospital for the 60-month follow-up exam, and therefore is no longer considered withdrawn.

- <sup>a</sup> One patient (1350037) withdrew from the study 52 days after the procedure and is being followed at a nonstudy site.
- <sup>b</sup> One patient (2511101) withdrew from the study 530 days after the procedure.
- <sup>c</sup> One patient (0911120) did not have a 60-month follow-up exam, and this patient later withdrew 2029 days after the procedure.
- <sup>d</sup> One patient (3011101) did not have aortic or renal duplex ultrasounds at the 60-month follow-up visit.
- <sup>e</sup> One patient (1211110) did not have a clinical assessment, KUB, or renal duplex ultrasound at the 60-month follow-up visit.
- <sup>f</sup> One patient (1350039) did not have a 36-month follow-up exam, and this patient later withdrew 1139 days after the procedure. Vital status was confirmed 1702 days post-procedure on March 26, 2020 based on the site's medical record.
- <sup>g</sup> One patient (1350027) did not have a 48-month follow-up exam, and this patient later withdrew 1516 days after the procedure.
- <sup>h</sup> One patient (1350023) had the 48-month follow-up exam and subsequently withdrew from the study 1456 days after the procedure. Vital status was confirmed 1656 days post-procedure on May 14, 2019 based on the site's medical record.
- <sup>i</sup> One patient (1350006) had the 48-month follow-up exam and subsequently was lost to follow-up 1526 days after the procedure. Vital status was confirmed by the site 2232 days after the procedure on May 26, 2020.

## Summary of post-approval study results

### Primary endpoint results

Results of the hypothesis testing show the null hypothesis was rejected; the alternative hypothesis was accepted. **Table 6.27** presents the results of the hypothesis testing for the primary endpoint. Specifically, the AAA-related mortality rate at 5 years post-procedure (based on intent to treat – i.e., including all enrolled patients in the denominator) is 2.27% (p < 0.0001). Further analysis of the endpoint based on a denominator that included only patients who died, completed 5-year follow-up, or had confirmed 5-year vital status through other means remained low (2/65; 3.08% [UCL 10.68%]) and likewise continued to meet the performance goal of 18% for AAA-related mortality at 5 years (p < 0.01).

**Table 6.27 AAA-related mortality rate at 5 years post-procedure<sup>a</sup>**

Performance goal	5-year rate of AAA-related mortality	Confidence interval	P-value
18%	2.27% <sup>b</sup>	1.99%, 10.24%	< 0.0001

<sup>a</sup> Reported results based on intent-to-treat (i.e., including all patients (88) in the denominator). Further analysis based on a denominator that included only patients who died, completed 5-year follow-up, or had confirmed 5-year vital status through other means also met the performance goal (2/65; 3.08% [UCL 10.68%]; p < 0.01).

<sup>b</sup> Two AAA-related deaths. Patient 0911108: Bowel ischemia on postoperative day (POD) 0 and death on POD 2; CEC adjudicated death as AAA-related (procedure-related). Patient 0111010: Death on POD 761 according to social security index. Cause of death was unknown; therefore, the CEC was unable to adjudicate, but death was conservatively counted as AAA-related for purpose of endpoint analysis.

A total of 23 patients had missing 5-year vital status data for the primary endpoint analysis. The results from tipping point analysis indicated that in addition to the 2 deaths already counted as AAA-related (0911108, 0111010), it would require at least 22% (n=5) of the 23 cases with missing vital status data to also have AAA-related death in order to fail the study hypothesis, which is unlikely considering 1 of the patients did not receive the device while nearly all remaining patients had a favorable treatment outcome (i.e., a stable or shrinking aneurysm) at last follow-up. Specifically, 9 treated patients with missing vital status data at 5 years demonstrated aneurysm shrinkage (> 5 mm decrease in diameter) and 12 patients had a stable aneurysm (≤ 5 mm change in diameter) at last follow-up. Only 1 treated patient exhibited aneurysm growth (> 5 mm increase in diameter) at last follow-up; however, the growth was observed in the setting of a Type II endoleak, which resolved following reintervention.

### Secondary endpoint results

#### Commercial training program effectiveness

Per the protocol, the cohort relevant to evaluating commercial training program effectiveness was to consist of the first 3 patients from each site that enrolled in the post-approval study (i.e., if more than 3 patients were enrolled at a particular site, then those patients were excluded from the analysis). In total, 13 patients enrolled at 6 sites made up the post-approval study cohort that was analyzed to evaluate commercial training program effectiveness. For comparison, a similar cohort was selected from the pre-approval study (first 3 patients from each site), which consisted of 32 patients enrolled at 14 sites. There were no reports of technical failure (defined as unable to access the aneurysm site and/or unable to deploy the Zenith® Fenestrated AAA Endovascular Graft in the intended location) reported by the sites in either the pre-approval study or the post-approval study cohorts, only difficulty accessing the left renal artery was reported in 3 patients at 3 sites in the post-approval study (fenestration not aligning upon deployment, fenestrated device partially constrained, difficulty cannulating the renal artery). An Atrium iCAST™ covered stent was successfully deployed in the left renal artery in all 3 patients. There were no reports of loss of patency or type I or III endoleak within 30 days as assessed by the core laboratory. In addition, no rupture, conversion, or secondary interventions were reported within 30 days. The commercial training program for the post-approval study was therefore deemed effective.

#### Morbidity

The number of patients experiencing protocol-defined adverse events categorized according to organ system and by specific events within each organ system is reported in the sections that follow.

#### Morbidity by category

**Table 6.28** lists the percent of patients who experienced early (0-30 days) or late (31-365 days; 366-730 days; 731-1095 days; 1096-1460 days; 1461-1825 days; > 1825 days) events, categorized by organ system (cardiovascular, pulmonary, renal, gastrointestinal, neurological, vascular, and wound). In addition, a total of 70 patients experienced “other” events.

Category	Table 6.28 Percent of patients experiencing events by category						
	0-30 days (N=88)	31-365 days (N=87)	366-730 days (N=79)	731-1095 days (N=76)	1096-1460 days (N=64)	1461-1825 days (N=55)	> 1825 days (N=48)
Cardiovascular	2.3% (2)	10.3% (9)	3.8% (3)	6.6% (5)	6.3% (4)	14.5% (8)	2.1% (1)
Pulmonary	2.3% (2)	5.7% (5)	1.3% (1)	2.6% (2)	1.6% (1)	7.3% (4)	0% (0)
Renal	12.5% (11)	3.4% (3)	3.8% (3)	1.3% (1)	6.3% (4)	5.5% (3)	0% (0)
Gastrointestinal	4.5% (4)	0% (0)	1.3% (1)	0% (0)	0% (0)	0% (0)	0% (0)
Neurological	0% (0)	0% (0)	0% (0)	1.3% (1)	0% (0)	0% (0)	0% (0)
Vascular	17.0% (15)	2.3% (2)	0% (0)	2.6% (2)	4.7% (3)	5.5% (3)	0% (0)
Wound	4.5% (4)	5.7% (5)	0% (0)	0% (0)	0% (0)	0% (0)	0% (0)
Other	37.5% (33)	44.8% (39)	21.5% (17)	35.5% (27)	18.8% (12)	32.7% (18)	8.3% (4)

#### Morbidity by event

The following sections list the percent of patients who experienced early (0-30 days) or late (31-365 days; 366-730 days; 731-1095 days; 1096-1460 days; 1461-1825 days; > 1825 days) adverse events within a specific organ system. Preexisting conditions at the time of admission were not considered adverse events.

#### Cardiovascular events

**Table 6.29** lists the percent of patients who experienced specific cardiovascular events.

Event	Table 6.29 Percent of patients with cardiovascular events						
	0-30 days (N=88)	31-365 days (N=87)	366-730 days (N=79)	731-1095 days (N=76)	1096-1460 days (N=64)	1461-1825 days (N=55)	> 1825 days (N=48)
Q-wave MI	0% (0)	1.1% (1) <sup>b</sup>	0% (0)	0% (0)	0% (0)	0% (0)	0% (0)
Non-Q-wave MI	0% (0)	1.1% (1) <sup>c</sup>	0% (0)	0% (0)	0% (0)	1.8% (1) <sup>d</sup>	0% (0)
Congestive heart failure	0% (0)	2.3% (2) <sup>e</sup>	1.3% (1) <sup>f</sup>	0% (0)	3.1% (2) <sup>g,h</sup>	9.1% (5) <sup>i,j,k,l,m,n</sup>	0% (0)
Arrhythmia (requiring treatment or new treatment)	2.3% (2) <sup>a</sup>	3.4% (3) <sup>d,e,g</sup>	0% (0)	3.9% (3) <sup>h,i,q</sup>	4.7% (3) <sup>m,q,r</sup>	7.3% (4) <sup>k,l,w,x</sup>	2.1% (1) <sup>h,b</sup>
Ischemia requiring intervention	0% (0)	2.3% (2) <sup>f</sup>	2.5% (2) <sup>v,y</sup>	2.6% (2) <sup>z</sup>	1.6% (1) <sup>o</sup>	1.8% (1) <sup>w</sup>	0% (0)
Inotropic support	0% (0)	0% (0)	0% (0)	0% (0)	0% (0)	0% (0)	0% (0)
Medically intractable hypertension	0% (0)	0% (0)	0% (0)	0% (0)	0% (0)	0% (0)	0% (0)

<sup>a</sup> Patients 0111009 and 0111011 (arrhythmia requiring treatment). CEC adjudicated both events to be aneurysm-related (procedure-related).

<sup>b</sup> Patient 1111002. Reported as anterior septal MI. Site was unable to determine if Q-wave or non-Q-wave, but is reported as Q-wave MI to be conservative. CEC adjudicated this event to be unrelated (related to preexisting condition).

<sup>c</sup> Patients 0211008 and 0211010 (CHF). CEC adjudicated 0211008 to be unrelated (related to other cause). CEC adjudicated 0211010 to be unrelated (related to preexisting condition).

<sup>d</sup> Patient 0511007 (arrhythmia requiring treatment).

<sup>e</sup> Patient 1311106 (arrhythmia requiring treatment).

<sup>f</sup> Patient 1211106 (ischemia requiring intervention). The patient recovered after a coronary artery stent was placed. CEC adjudicated this event to be unrelated (related to preexisting condition).

<sup>g</sup> Patient 0211006 (CHF). CEC adjudicated this event to be unrelated (related to preexisting condition).

<sup>h</sup> Patient 0211010 (arrhythmia requiring treatment). CEC adjudicated this event to be unrelated (related to preexisting condition).

<sup>i</sup> Patient 0511008 (ischemia requiring intervention). CEC adjudicated this event to be unrelated (related to preexisting condition).

<sup>j</sup> Patient 0111004 (non-Q-wave MI).

<sup>k</sup> Patient 0511004 (arrhythmia requiring intervention).

- <sup>l</sup> Patient 1211106 (arrhythmia requiring intervention). The patient recovered with treatment (drug therapy).
- <sup>m</sup> Patient 0211011 (arrhythmia requiring intervention, CHF). This patient had a change of medications and cardioversion two times. CHF occurred 1360 days post-procedure. Arrhythmia requiring intervention did not go to CEC for adjudication. CEC adjudicated the CHF event to be unrelated (related to other condition).
- <sup>n</sup> Patient 1111101 (ischemia requiring intervention). The patient had a coronary artery bypass 808 days post-procedure and has recovered. CEC adjudicated this event to be unrelated (related to preexisting condition).
- <sup>o</sup> Patient 0511011 (ischemia requiring intervention). CEC adjudicated this event to be unrelated (related to preexisting condition).
- <sup>p</sup> Patient 1350029 (non-Q-wave MI). CEC adjudicated this event to be unrelated (related to preexisting condition).
- <sup>q</sup> Patient 1350031 (arrhythmia requiring intervention, CHF). The patient first experienced arrhythmia at 174 days post-procedure. The patient recovered following treatment with adenosine. The patient experienced four additional episodes of arrhythmia at 313, 328, 341, and 354 days post-procedure. For each episode, the patient recovered following a change in medication or treatment with radiofrequency ablation. The patient experienced an additional two episodes of arrhythmia at 813 and 833 days post-procedure. The treatment for the first of these two episodes was a change in medication (metoprolol to sotalol). The treatment for the second of these two episodes was an additional medication (Tikosyn). The patient experienced an additional three episodes of arrhythmia at 1094 days post-procedure and recovered with cardioversion, 1136 days post-procedure and recovered with ablation, and 1250 days post-procedure and recovered with AV nodal ablation. The patient experienced CHF 1151 days post-procedure and recovered with IV diuretic therapy. CEC adjudicated the CHF to be unrelated (related to preexisting condition).
- <sup>r</sup> Patient 1350036 (ischemia requiring intervention). The patient underwent coronary artery stent placement and dual antiplatelet therapy 66 days post-procedure. CEC adjudicated this event to be unrelated (related to preexisting condition).
- <sup>s</sup> Patient 0211103 (CHF). CEC adjudicated this event to be unrelated (related to preexisting condition).
- <sup>t</sup> Patient 0611105 (CHF, arrhythmia requiring intervention). CEC adjudicated the CHF to be unrelated (related to other condition).
- <sup>u</sup> Patient 1211110 (CHF). CEC adjudicated this event to be unrelated (related to preexisting condition).
- <sup>v</sup> Patient 1350025 (ischemia requiring intervention). CEC adjudicated this event to be unrelated (related to preexisting condition).
- <sup>w</sup> Patient 1411101 (ischemia requiring intervention, arrhythmia requiring intervention). CEC adjudicated the ischemia to be unrelated (related to preexisting condition). The patient experienced two episodes of arrhythmia at 1674 and 1695 days post-procedure.
- <sup>x</sup> Patient 1911103 (CHF, arrhythmia requiring intervention). CEC adjudicated the CHF to be unrelated (related to aortic valve disease).
- <sup>y</sup> Patient 1350032 (cardiac ischemia requiring intervention). The patient underwent coronary artery stent placement. CEC adjudicated this event to be unrelated (related to other condition).
- <sup>z</sup> Patient 0611101 (arrhythmia requiring intervention). The patient had a change of medications. This case did not go to the CEC for adjudication.
- <sup>aa</sup> Patient 1350027 (CHF). This event was reported during a phone call between the site and the patient; no additional information is available.
- <sup>bb</sup> Patient 1350038 (arrhythmia requiring intervention). The patient recovered with treatment (insertion of a permanent cardiac pacemaker).

## Pulmonary events

**Table 6.30** lists the percent of patients who experienced specific pulmonary events.

Event	Table 6.30 Percent of patients with pulmonary events						
	0-30 days (N=88)	31-365 days (N=87)	366-730 days (N=79)	731-1095 days (N=76)	1096-1460 days (N=64)	1461-1825 days (N=55)	> 1825 days (N=48)
Re-intubation or ventilation > 24 hrs	0% (0)	0% (0)	0% (0)	0% (0)	0% (0)	0% (0)	0% (0)
Pneumonia requiring antibiotics	0% (0)	5.7% (5) <sup>b</sup>	1.3% (1) <sup>c</sup>	2.6% (2) <sup>d,e</sup>	1.6% (1) <sup>f</sup>	7.3% (4) <sup>f,g,h,j</sup>	0% (0)
Supplemental O2 at discharge	2.3% (2) <sup>a</sup>	0% (0)	0% (0)	1.3% (1) <sup>d</sup>	0% (0)	0% (0)	0% (0)

- <sup>a</sup> Patients 0511009 and 0911120 (supplemental oxygen at the time of discharge). CEC adjudicated the event for patient 0511009 to be unrelated (related to preexisting condition).
- <sup>b</sup> Patients 0111014, 1111002, 1111007, 1211106, and 1350006 (pneumonia requiring antibiotics). Patient 1111007 had pneumonia requiring antibiotics at 38, 165, and 261 days post-procedure. CEC adjudicated all pneumonia events for patient 1111007 to be unrelated (related to other or preexisting condition). CEC adjudicated the event for patient 0111014 to be unrelated (related to secondary procedure). CEC adjudicated the event for patient 1111002 to be unrelated (related to preexisting condition).
- <sup>c</sup> Patient 0911110 (pneumonia requiring antibiotics).
- <sup>d</sup> Patient 0511009 (pneumonia requiring antibiotics and supplemental oxygen at the time of discharge). CEC adjudicated these events to be unrelated (related to preexisting condition).
- <sup>e</sup> Patient 0111009 (pneumonia requiring antibiotics). CEC adjudicated this event to be unrelated (related to other cause).
- <sup>f</sup> Patient 0611003 (pneumonia requiring antibiotics).
- <sup>g</sup> Patient 1211110 (pneumonia requiring antibiotics). Patient experienced pneumonia at 1115 and 1555 days post-procedure.
- <sup>h</sup> Patient 0611105 (pneumonia requiring antibiotics).
- <sup>i</sup> Patient 1350034 (pneumonia requiring antibiotics).

## Renal events

**Table 6.31** lists the percent of patients who experienced specific renal events.

Event	Table 6.31 Percent of patients with pulmonary events						
	0-30 days (N=88)	31-365 days (N=87)	366-730 days (N=79)	731-1095 days (N=76)	1096-1460 days (N=64)	1461-1825 days (N=55)	> 1825 days (N=48)
Dialysis in patients with normal pre-operative renal function	1.1% (1) <sup>j</sup>	0% (0)	0% (0)	0% (0)	0% (0)	0% (0)	0% (0)
Dialysis in patients with abnormal pre-operative renal function	0% (0)	0% (0)	0% (0)	0% (0)	1.6% (1) <sup>g</sup>	0% (0)	0% (0)
Serum creatinine > 2.0 mg/dL and rise > 30%	1.1% (1) <sup>i</sup>	0% (0)	1.3% (1) <sup>d</sup>	1.3% (1) <sup>p</sup>	3.1% (2) <sup>h,m</sup>	5.5% (3) <sup>k,l,o</sup>	0% (0)
Occlusion of a fenestrated renal vessel	0% (0)	2.3% (2) <sup>b,c</sup>	2.5% (2) <sup>e,f</sup>	0% (0)	1.6% (1) <sup>k</sup>	0% (0)	0% (0)
Renal infarct	10.2% (9) <sup>a</sup>	2.3% (2) <sup>c,n</sup>	0% (0)	0% (0)	0% (0)	0% (0)	0% (0)

- <sup>a</sup> Patients 0111011, 0511009, 0511010, 0911120, 1111002, 1111007, 1311106, 1350030, and 1350032 (renal infarct). CEC adjudicated all events to be aneurysm-related (procedure-related for each except 1111002, which was technique-related).
- <sup>b</sup> Patient 0211008 (occlusion of a fenestrated vessel). CEC adjudicated this event to be aneurysm-related (procedure, technique, and device-related).
- <sup>c</sup> Patient 0911115 (occlusion of a fenestrated vessel and renal infarct). CEC adjudicated these events to be aneurysm-related (procedure-related).
- <sup>d</sup> Patient 0211010 (serum creatinine rise > 2.0 mg/dL and > 30% above baseline during two follow-up periods). Although no stenosis or occlusion of any targeted vessel has been identified at any follow-up time period, CEC adjudicated this event to be aneurysm-related (procedure-related) (Scr pre-procedure: 1.2 mg/dL; post-procedure: 0.9 mg/dL; 1-month: 1.3 mg/dL; 6-month: 1.6 mg/dL; 12-month: 1.8 mg/dL; 24-month: 2.3 mg/dL; 36-month: 1.6 mg/dL; 48-month: not done; 60-month: not done). Of note, the serum creatinine decreased at the 36-month follow-up time period.
- <sup>e</sup> Patient 0611003 (occlusion of a fenestrated vessel). The patient was diagnosed with slight atrophy of the left kidney at 177 days post-procedure with confirmed renal artery occlusion at 373 days post-procedure. The patient has not been treated for vessel occlusion because the creatinine has remained stable (Scr pre-procedure: 1.0 mg/dL; 60-month: 1.1 mg/dL). CEC adjudicated this event to be aneurysm-related (device related).
- <sup>f</sup> Patient 1111011 (occlusion of a fenestrated vessel). CEC adjudicated this event to be aneurysm-related (device-related).
- <sup>g</sup> Patient 0111006 (serum creatinine rise > 2.0 mg/dL and > 30% above baseline during two follow-up periods). CEC adjudicated this event to be unrelated (related to preexisting condition). The patient presented with an atrophic kidney prior to treatment with the Zenith<sup>®</sup> Fenestrated AAA Endovascular Graft (Scr pre-procedure: 1.4 mg/dL; post-procedure: 1.1 mg/dL; 1-month: 1.7 mg/dL; 6-month: 1.8 mg/dL; 12-month: 1.7 mg/dL; 24-month: 2.1 mg/dL; 36-month: 2.3 mg/dL; 48-month: not done; 60-month: not done). The patient was put on dialysis 1189 days post-procedure and was identified with acute renal failure. CEC also adjudicated this event to be unrelated (related to preexisting condition).
- <sup>h</sup> Patient 0421001 (serum creatinine rise > 2.0 mg/dL and > 30% above baseline during two follow-up periods). Renal stenosis of nontargeted, nonstented right renal artery has also been reported. CEC adjudicated both events to be unrelated (related to preexisting condition) (Scr pre-procedure: 1.9 mg/dL; post-procedure: 1.5 mg/dL; 1-month: 1.4 mg/dL; 6-month: 1.6 mg/dL; 12-month: 1.4 mg/dL; 24-month: 1.5 mg/dL; 36-month: 2.3 mg/dL; 48-month: 4.8 mg/dL; 60-month: 2.8 mg/dL).
- <sup>i</sup> Patient 1350003 (serum creatinine rise > 2.0 mg/dL and > 30% above baseline during two follow-up periods). CEC adjudicated this event to be aneurysm-related (procedure-related).
- <sup>j</sup> Patient 1350027 (dialysis in patients with normal pre-operative renal function). CEC adjudicated this event to be aneurysm-related (procedure-related).
- <sup>k</sup> Patient 0211103 (occlusion of a fenestrated renal vessel). CEC adjudicated this event to be aneurysm-related (procedure and device-related). This patient also had serum creatinine rise > 2.0 mg/dL and > 30% above baseline during two follow-up periods. CEC adjudicated this event to be related (procedure and device-related due to progression of left renal artery stenosis to occlusion).
- <sup>l</sup> Patient 0111016 (serum creatinine rise > 2.0 mg/dL and > 30% above baseline during two follow-up periods). CEC adjudicated this event to be unrelated (related to preexisting condition).
- <sup>m</sup> Patient 1111013 (serum creatinine rise > 2.0 mg/dL and > 30% above baseline during two follow-up periods). CEC adjudicated this event to be unrelated (related to preexisting condition).
- <sup>n</sup> Patient 1350033 (renal infarct). CEC adjudicated this event to be aneurysm-related (procedure-related).
- <sup>o</sup> Patient 3011101 (serum creatinine rise > 2.0 mg/dL and > 30% above baseline during two follow-up periods). CEC adjudicated this event to be unrelated (related to preexisting condition).

**Gastrointestinal events**

**Table 6.32** lists the percent of patients who experienced specific gastrointestinal events.

Event	Table 6.32 Percent of patients with gastrointestinal events						
	0-30 days (N=88)	31-365 days (N=87)	366-730 days (N=79)	731-1095 days (N=76)	1096-1460 days (N=64)	1461-1825 days (N=55)	> 1825 days (N=48)
Bowel obstruction	0% (0)	0% (0)	1.3% (1) <sup>c</sup>	0% (0)	0% (0)	0% (0)	0% (0)
Bowel ischemia/infarct	3.4% (3) <sup>a</sup>	0% (0)	0% (0)	0% (0)	0% (0)	0% (0)	0% (0)
Aorto-enteric fistula	0% (0)	0% (0)	0% (0)	0% (0)	0% (0)	0% (0)	0% (0)
Paralytic ileus > 4 days	1.1% (1) <sup>b</sup>	0% (0)	0% (0)	0% (0)	0% (0)	0% (0)	0% (0)

<sup>a</sup> Patients 0211011, 0911108, and 1111102 (bowel ischemia). CEC adjudicated these events to be aneurysm-related (procedure-related).

<sup>b</sup> Patient 0111008 (paralytic ileus > 4 days). CEC adjudicated this event to be aneurysm-related (procedure-related).

<sup>c</sup> Patient 0511010 (bowel obstruction). CEC adjudicated this event to be unrelated (related to preexisting condition).

**Neurological events**

**Table 6.33** lists the percent of patients who experienced specific neurological events.

Event	Table 6.33 Percent of patients with neurological events						
	0-30 days (N=88)	31-365 days (N=87)	366-730 days (N=79)	731-1095 days (N=76)	1096-1460 days (N=64)	1461-1825 days (N=55)	> 1825 days (N=48)
Stroke	0% (0)	0% (0)	0% (0)	1.3% (1) <sup>a</sup>	0% (0)	0% (0)	0% (0)
TIA	0% (0)	0% (0)	0% (0)	0% (0)	0% (0)	0% (0)	0% (0)
Spinal cord ischemia/ paralysis	0% (0)	0% (0)	0% (0)	0% (0)	0% (0)	0% (0)	0% (0)

<sup>a</sup> Patient 0211010 (stroke). CEC adjudicated this event to be unrelated (related to preexisting condition).

**Vascular events**

**Table 6.34** lists the percent of patients who experienced specific vascular events.

Event	Table 6.34 Percent of patients with vascular events						
	0-30 days (N=88)	31-365 days (N=87)	366-730 days (N=79)	731-1095 days (N=76)	1096-1460 days (N=64)	1461-1825 days (N=55)	> 1825 days (N=48)
Limb thrombosis	0% (0)	0% (0)	0% (0)	0% (0)	0% (0)	0% (0)	0% (0)
Distal embolization resulting in tissue loss or requiring intervention	2.3% (2) <sup>a,b</sup>	0% (0)	0% (0)	0% (0)	0% (0)	0% (0)	0% (0)
Post-procedural transfusion	14.8% (13) <sup>a,c</sup>	0% (0)	0% (0)	0% (0)	0% (0)	1.8% (1) <sup>f</sup>	0% (0)
Pseudoaneurysm	0% (0)	0% (0)	0% (0)	0% (0)	0% (0)	0% (0)	0% (0)
Vascular injury	1.1% (1) <sup>d</sup>	1.1% (1) <sup>b</sup>	0% (0)	1.3% (1) <sup>j</sup>	0% (0)	0% (0)	0% (0)
Aneurysm, vessel leak, or rupture	0% (0)	0% (0)	0% (0)	1.3% (1) <sup>g</sup>	0% (0)	1.8% (1) <sup>h</sup>	0% (0)
Aneurysm enlargement by > 5 mm relative to the smallest of any prior measurement	0% (0)	1.1% (1) <sup>e</sup>	0% (0)	0% (0)	4.7% (3) <sup>i,j,l</sup>	1.8% (1) <sup>m</sup>	0% (0)

<sup>a</sup> Patient 0111009 (distal embolization requiring intervention and transfusion). CEC adjudicated these events to be aneurysm-related (procedure-related).

<sup>b</sup> Patient 0911107 (distal embolization requiring intervention). CEC adjudicated this event to be aneurysm-related (procedure-related).

<sup>c</sup> Patients 0111007, 0111008, 0111011, 0411002, 0511004, 0511011, 0611003, 0911108, 1211106, 1211110, 1350008, and 1350032 (transfusion). CEC adjudicated events for patients 0111008, 0111011, and 0611003 to be aneurysm-related (procedure-related).

<sup>d</sup> Patient 0911115 (vascular injury).

<sup>e</sup> Patients 0611101 and 1411101 (increase in aneurysm size > 5 mm). Both patients had core laboratory-reported type II endoleak.

<sup>f</sup> Patient 0111004 (transfusion). Patient required transfusions at 1468 and 1506 days post-procedure.

<sup>g</sup> Patient 1211106 (aneurysm, vessel leak, or rupture). CEC adjudicated this event to be aneurysm-related (related to component failure) and also stated that they did not consider this an aneurysm rupture, but a new endoleak.

<sup>h</sup> Patient 1911103 (vascular injury). Patient had a hemiretinal vein occlusion.

<sup>i</sup> Patient 1350038 (vascular injury). Patient experienced acute dissection of the ascending aorta.

<sup>j</sup> Patient 1350032 (increase in aneurysm size > 5 mm). The site reported that the treated aneurysm had decreased in size, and an aneurysm in the left common iliac artery, which had developed since the patient's enrollment in the study, had grown. The core laboratory reported a type I distal endoleak and a decrease in the maximum size of the treated aneurysm at the 3-year time point.

<sup>k</sup> Patient 1350028 (aneurysm, vessel leak, or rupture). The site and core laboratory each reported type III endoleak. Additional details are available in the Rupture section.

<sup>l</sup> Patient 1350008 (increase in aneurysm size > 5 mm). The site and core laboratory each reported type II endoleak. The site has no immediate plans for intervention but continues to monitor the patient. The patient completed the 5-year follow-up exam and has been exited from the study.

<sup>m</sup> Patient 1350025 (increase in aneurysm size > 5 mm). The site reported a type II endoleak. Additional details can be found in the Secondary Interventions section.

**Wound events**

**Table 6.35** lists the percent of patients who experienced specific wound events.

Event	Table 6.35 Percent of patients with wound events						
	0-30 days (N=88)	31-365 days (N=87)	366-730 days (N=79)	731-1095 days (N=76)	1096-1460 days (N=64)	1461-1825 days (N=55)	> 1825 days (N=48)
Infection requiring antibiotics	2.3% (2) <sup>a</sup>	2.3% (2) <sup>c</sup>	0% (0)	0% (0)	0% (0)	0% (0)	0% (0)
Incisional hernia	0% (0)	3.4% (3) <sup>d</sup>	0% (0)	0% (0)	0% (0)	0% (0)	0% (0)
Lymph fistula	0% (0)	0% (0)	0% (0)	0% (0)	0% (0)	0% (0)	0% (0)
Seroma requiring treatment	0% (0)	1.1% (1) <sup>e</sup>	0% (0)	0% (0)	0% (0)	0% (0)	0% (0)
Breakdown requiring debridement	0% (0)	0% (0)	0% (0)	0% (0)	0% (0)	0% (0)	0% (0)
Complication requiring return to operating room	2.3% (2) <sup>b,f</sup>	0% (0)	0% (0)	0% (0)	0% (0)	0% (0)	0% (0)

<sup>a</sup> Patients 0111004 and 1211110 (infection requiring antibiotics).

<sup>b</sup> Patient 0611101 (excisional debridement with muscle flap closure bilaterally).

<sup>c</sup> Patients 1111007 and 1211106 (infection requiring antibiotics). CEC adjudicated the event for patient 1111007 to be aneurysm-related (procedure-related).

<sup>d</sup> Patients 0111004, 0111007, and 1350028 (incisional hernia).

<sup>e</sup> Patient 1211106 (seroma requiring treatment).

<sup>f</sup> Patient 1350027 (pseudoaneurysm at left entry site that was repaired with patch angioplasty).

**Rupture**

The number of patients experiencing aneurysm rupture is reported in **Table 6.36**, categorized as early (0-30 days) or late (31-365 days; 366-730 days; 731-1095 days; 1096-1460 days; 1461-1825 days; > 1825 days).

**Table 6.36 Rupture**

Event	0-30 days	31-365 days	366-730 days	731-1095 days	1096-1460 days	1461-1825 days	> 1825 days
Rupture	0	0	0	0	0	1 <sup>a</sup>	0

*a Patient 1350028 experienced component separation and aneurysm rupture at the 5-year time point. The patient had no prior report of aneurysm growth > 5 mm from the smallest prior measurement and had no prior report of endoleak. The patient was admitted to a nonstudy hospital 1818 days post-procedure after a fall. Abdominal pain and anemia were noted. At 1822 days post-procedure, the 5-year follow-up CT scan was performed, which showed aneurysm growth > 5 mm from baseline. The patient was transferred to the study hospital. The site reported a type III endoleak between the proximal and distal components of the main body, as well as separation of these components, and aneurysm leak/rupture. The site noted that the endoleak had developed from elongation of the aorta. The core laboratory review also noted a type III endoleak and component separation between the proximal and distal components of the main body graft. On the same day, a secondary intervention for aneurysm rupture and device separation was performed, which involved placement of Gore excluder AAA endoprosthesis cuffs. After assessment of a post-secondary intervention CT scan, the site reported successful repair of the endoleak. Core laboratory evaluation of this CT scan confirmed that an endoleak was not present. The CEC adjudicated this event as aneurysm-related (related to component failure).*

**Conversion**

No conversions to open repair have been reported.

**Secondary interventions**

There were 30 secondary interventions in 25 unique patients, as summarized in **Table 6.37** below.

**Table 6.37 Secondary interventions to date**

Patient number	Days after procedure	Intervention
0111008	238	Additional stent implanted to treat right renal artery stenosis. Follow-up demonstrated a patent renal artery.
0111014	245	Angioplasty and additional stents implanted to treat bilateral renal artery stenosis. Follow-up demonstrated patent renal arteries.
0111016	1490	Coil embolization to treat a persistent type II endoleak. The site noted that the intervention was successful.
0111017	427	A stent was placed to treat right renal artery stenosis. The site noted that the intervention was successful.
	840	Angioplasty and additional stent implanted to treat left renal artery stenosis. The site noted that the intervention was successful.
0211007	406	Repeat balloon angioplasty and additional stent implanted to treat right renal artery stenosis. Follow-up demonstrated a patent renal artery.
0211008	222	Graft implanted to successfully bypass occluded section of renal artery.
0211010	239	Coil embolization of inferior mesenteric artery (IMA) for persistent type II endoleak. Type II endoleak was noted on the 4-year follow-up exam. The site noted that the intervention was successful.
0211011	30	Angiography was performed to evaluate potential occlusion of a fenestrated renal vessel. Diagnostic angiography successfully determined that the right renal artery was severely stenosed, but thrombectomy was unable to be performed as a larger catheter could not be passed into the renal artery.
	1746	Coil embolization and ancillary component placed to treat a site-reported persistent type I endoleak. The site noted that the intervention was successful.
0211103	1582	Renal angioplasty to treat device stenosis. The site noted that the intervention was successful.
0511003	1539	Additional stent implanted and angioplasty performed to treat left renal artery stenosis. The site noted that the intervention was successful.
0511004	1393	Laparotomy with suture ligation of the IMA was performed to treat aneurysm growth due to persistent type II endoleak (two previous attempts to coil embolize the IMA had failed). The site noted that the intervention was successful.
0511006	883	Angioplasty and additional stents implanted to treat "partially crushed" right renal artery stent and subsequent stenosis. Intra-operative angiogram demonstrated a patent right renal artery at the end of the procedure.
0511009	1400	Bilateral renal artery angioplasty and stent placement performed to treat bilateral renal artery stenosis. Right iliac artery stent placed as well. The site noted that the intervention was successful.
0611101	224	Coil and N-BCA glue embolization performed to treat a type II endoleak causing an enlarging AAA. The site noted that the intervention was successful.
0611105	743	Angioplasty and stent placement performed to treat a stenosis of the right renal artery stent. The site noted that the intervention was successful.
0911006	1003	A stent was placed in the left renal artery to treat a site-reported type I proximal endoleak. The site noted that the intervention was successful.
	1100	The site reported a type I proximal endoleak. The site attempted coil embolization, but failed; access into the vessel supplying the endoleak could not be attained.
	1142	The site reported a type I proximal endoleak. The site performed a successful coil embolization.
1111011	398	Percutaneous attempt to cannulate the right renal artery stent. The site noted that the intervention was not successful and further treatment options were to be discussed with the patient.
	435	Surgical common hepatic artery to right renal artery bypass performed using reverse greater saphenous vein to treat a crushed right renal stent. The site noted that the intervention was successful.
1211106 <sup>a</sup>	1031	Ancillary components placed in the right and left iliac arteries to treat an infrarenal aneurysm rupture and a persistent endoleak of unknown type. The site noted that the intervention was successful.
1211109	382	Angioplasty and stent placement performed to treat a stenosis of the left renal artery stent. Follow-up demonstrated a patent renal artery.
1350021	263	The site reported type I distal and type II endoleaks. The site performed a successful coil embolization to resolve type I and type II endoleaks.
1350025	1719	Coil embolization of the inferior mesenteric artery and ancillary component placement to treat an enlarging aneurysm due to a persistent type II endoleak (per site assessment). The site noted that the intervention was successful.
1350028	1822	Endovascular repair using Gore excluder AAA endoprosthesis cuffs to treat aneurysm rupture and type III endoleak that developed from elongation of the aorta and separation of the aortic component from the bifurcated component. The site noted that the intervention was successful.
1350031	763	Coil embolization to treat a persistent type II endoleak. The site noted that the intervention was successful.
1350032	1316	Embolization of the left hypogastric artery and extension into the left external iliac artery to treat type I distal endoleak and left common iliac enlargement. The site noted that the intervention was successful.
1411101	1188	Angioplasty and stent placed to treat what the site believed to be a persistent type II endoleak. The site noted that the intervention was successful.

<sup>a</sup> The CEC adjudicated this as related to component failure and noted that they did not consider this event to be an aneurysm rupture, but rather an endoleak due to the leak of contrast into the aneurysm sac.

## Endoleaks

Endoleaks by type, as assessed by the core laboratory at each exam period, are reported in **Table 6.38**.

Exam period		Percent of patients
Post-procedure	Type I proximal	0% (0/61)
	Type I distal	0% (0/61)
	Type II	29.5% (18/61)
	Type III	0% (0/61)
	Type IV	0% (0/61)
	Type unknown	1.6% (1/61)
	All types	31.1% (19/61)
1-month	Type I proximal	0% (0/75)
	Type I distal	0% (0/75)
	Type II	24.0% (18/75)
	Type III	0% (0/75)
	Type IV	0% (0/75)
	Type unknown	0% (0/75)
	All types	24.0% (18/75)
6-month	Type I proximal	0% (0/70)
	Type I distal	0% (0/70)
	Type II	22.9% (16/70)
	Type III	0% (0/70)
	Type IV	0% (0/70)
	Type unknown	2.9% (2/70)
	All types	25.7% (18/70)
12-month	Type I proximal	0% (0/63)
	Type I distal	0% (0/63)
	Type II	22.2% (14/63)
	Type III	0% (0/63)
	Type IV	0% (0/63)
	Type unknown	4.8% (3/63)
	All types	27.0% (17/63)
24-month	Type I proximal	0% (0/55)
	Type I distal	0% (0/55)
	Type II	20.0% (11/55)
	Type III	0% (0/55)
	Type IV	0% (0/55)
	Type unknown	5.5% (3/55)
	All types	25.5% (14/55)
36-month	Type I proximal	0% (0/48)
	Type I distal	2.1% (1/48)
	Type II	20.8% (10/48)
	Type III	0% (0/48)
	Type IV	0% (0/48)
	Type unknown	2.1% (1/48)
	All types	25.0% (12/48)
48-month	Type I proximal	0% (0/37)
	Type I distal	0% (0/37)
	Type II	13.5% (5/37)
	Type III	0% (0/37)
	Type IV	0% (0/37)
	Type unknown	0% (0/37)
	All types	13.5% (5/37)
60-month	Type I proximal	0% (0/33)
	Type I distal	0% (0/33)
	Type II	9.1% (3/33)
	Type III	3.0% (1/33)
	Type IV	0% (0/33)
	Type unknown	0% (0/33)
	All types	12.1% (4/33)

## Device integrity

At each exam period, the implanted devices were assessed by the core laboratory for integrity. This assessment included examination of KUB X-ray and/or CT imaging of the proximal graft, distal graft, iliac limbs, leg extension(s), renal stents, and if present, converter, occluder, and main body extension. **Table 6.39** reports the device integrity findings based on core laboratory analysis.

**Table 6.39 Percent of patients with device integrity findings based on core laboratory analysis (date of first occurrence)**

Finding	Post-procedure							
	Post-procedure	1-month	6-month	12-month	24-month	36-month	48-month	60-month
	<b>Stent graft</b>							
Barb separation	0% (0/74)	0% (0/82)	1.3% (1/77) <sup>a</sup>	1.4% (1/72) <sup>b</sup>	1.5% (1/68) <sup>c</sup>	0% (0/57)	1.9% (1/54) <sup>m</sup>	2.2% (1/46) <sup>n</sup>
Stent fracture (single)	0% (0/74)	0% (0/82)	0% (0/77)	2.8% (2/72) <sup>d,j</sup>	0% (0/68)	0% (0/57)	0% (0/54)	0% (0/46)
Stent fracture (multiple)	0% (0/74)	0% (0/82)	0% (0/77)	0% (0/72)	0% (0/68)	0% (0/57)	0% (0/54)	0% (0/46)
Component separation	0% (0/74)	0% (0/82)	0% (0/77)	0% (0/72)	0% (0/68)	0% (0/57)	0% (0/54)	2.2% (1/46) <sup>o</sup>
Limb separation	0% (0/74)	0% (0/82)	0% (0/77)	0% (0/72)	0% (0/68)	0% (0/57)	0% (0/54)	0% (0/46)
Stent-to-graft separation	0% (0/74)	0% (0/82)	0% (0/77)	0% (0/72)	0% (0/68)	0% (0/57)	0% (0/54)	0% (0/46)
Other	0% (0/74)	0% (0/82)	0% (0/77)	0% (0/72)	0% (0/68)	0% (0/57)	0% (0/54)	0% (0/46)
	<b>Fenestration stent</b>							
Fracture	0% (0/74)	0% (0/83)	2.6% (2/77) <sup>e,k</sup>	1.4% (1/72) <sup>d</sup>	0% (0/68)	0% (0/58)	0% (0/51)	0% (0/44)
Separation	0% (0/74)	0% (0/83)	0% (0/77)	0% (0/72)	0% (0/68)	0% (0/58)	0% (0/51)	0% (0/44)
Other	0% (0/74)	0% (0/83)	3.9% (3/77) <sup>g,h</sup>	1.4% (1/72) <sup>i</sup>	0% (0/68)	1.7% (1/58) <sup>j</sup>	0% (0/51)	0% (0/44)

<sup>a</sup> Patient 0421003: Separation of a single fixation barb. No clinical sequelae related to the barb separation were reported.

<sup>b</sup> Patient 0111009: Separation of a single fixation barb. No clinical sequelae related to the barb separation were reported.

<sup>c</sup> Patient 0511008: Separation of two barbs. No clinical sequelae related to the barb separation were reported, although radiographic migration (approximately 10 mm over 5 years) was observed and was likely due to longitudinal progression of disease with further aortic neck dilatation.

<sup>d</sup> Patient 0411001: Fracture of sealing stent (at the distal edge of the scallop fenestration) and left renal fenestration stent (uncovered, balloon-expandable 316L stainless steel biliary/iliac stent), but in a patient with progressive aneurysmal disease within and proximal to the treated segment, which likely resulted in uncharacteristic tension/loading of the stents. No subsequent renal events, endoleak, or secondary interventions were reported in this patient.

<sup>e</sup> Patient 0511010: Fracture of left renal fenestration stent (Zenith® Alignment Stent) not readily confirmed based on subsequent bench top CT imaging studies that showed the same appearance of fracture, but in an entirely intact stent.

<sup>f</sup> Patient 1111011: Deformation of right renal fenestration stent (Zenith® Alignment Stent) with no measurable graft movement > 5 mm. On post-operative day (POD) 398, a secondary intervention was performed to treat worsening renal function and an angiogram was performed to attempt to cannulate the right renal artery; cannulation was unsuccessful. On POD 435, the patient had a hepatic artery to right renal artery bypass using reverse greater saphenous vein to treat an occlusion caused by the crushed right renal stent. This secondary intervention was successful.

<sup>g</sup> Patient 0511003: Slight compression of left renal fenestration stent (uncovered, balloon-expandable 316L stainless steel biliary stent) with no measurable graft movement > 5 mm. Due to stenosis, on POD 1539, the patient underwent angioplasty and stent placement. Restenosis was identified at the 60-month follow-up and a successful secondary intervention was performed on POD 1876. The CEC adjudicated this event as unrelated.

<sup>h</sup> Patient 0511007: Slight compression of the left renal fenestration stent (uncovered, balloon-expandable 316L stainless steel biliary stent) with no measurable graft movement > 5 mm and not requiring secondary intervention.

<sup>i</sup> Patient 0511006: Compression of the right renal fenestration stent (uncovered, balloon-expandable 316L stainless steel biliary stent) associated with graft migration (approximately 12 mm by 24 months) due likely to longitudinal progression of disease with further aortic neck dilatation. Due to stenosis, on POD 883, the patient underwent angioplasty and stent placement.

<sup>j</sup> Patient 0611101: Single stent fracture in the proximal graft, approximately at the level of the renal arteries, was observed on the 12-month KUB. No clinical sequelae related to the stent fracture were reported.

<sup>k</sup> Patient 0211103: Fracture and deformity of the left renal fenestration stent (Zenith® Alignment Stent). On POD 1124, the patient was reported to have an occlusion of a fenestrated renal vessel, but the occlusion was not treated (secondary intervention for stenosis on the right side was performed on POD 1582). The patient was noted to have creatinine rise > 2.0 mg/dl and > 30% above baseline during two follow-up periods. The CEC adjudicated this event as AAA-related (procedure-related and device-related due to progression of the left renal artery stenosis to occlusion).

<sup>l</sup> Patient 1111102: Compression of left renal stent due to angulation. No other renal events were reported, and the patient did not require a secondary intervention for this event.

<sup>m</sup> Patient 0111017: Separation of one barb at 48 months. Barb separation was confirmed by the CEC, noted for the first time at 24 months following retrospective review of imaging.

<sup>n</sup> Patient 1111013: Separation of one barb observed at 60 months. Barb separation was confirmed by the CEC. No clinical sequelae related to the barb separation were reported.

<sup>o</sup> Patient 1350028: Component separation of the proximal and distal main body grafts. The patient also had growth > 5 mm, Type III endoleak, and rupture. On POD 1822, the patient underwent successful endovascular repair.

#### Device patency

The percentage of patients with patency loss involving either the stent-graft or a vessel accommodated by a fenestration is provided in **Table 6.40**.

**Table 6.40 Percent of patients with loss of patency based on core laboratory analysis or as reported by the site (date of first occurrence)**

Post-procedure	1-month	6-month	12-month	24-month	36-month	48-month	60-month
0% (0/67)	0% (0/82)	2.6% (2/78) <sup>a,b</sup>	2.7% (2/74) <sup>c,d</sup>	0% (0/66)	1.8% (1/56) <sup>e</sup>	0% (0/49)	0% (0/44)

<sup>a</sup> Patient 0211008 had renal artery occlusion; the patient underwent secondary intervention, as described in Table 6.37.

<sup>b</sup> Patient 0911115 had accessory renal artery occlusion; no secondary intervention was performed.

<sup>c</sup> Patient 0611003 had renal artery occlusion; no secondary intervention was performed.

<sup>d</sup> Patient 1111011 had renal artery occlusion; the patient underwent secondary intervention, as described in Table 6.37.

<sup>e</sup> Patient 0211103 had renal artery occlusion and fenestration stent fracture. This patient had serum creatinine rise > 2.0 mg/dl and > 30% above baseline during two follow-up periods; no secondary intervention was performed for left renal occlusion.

#### Aneurysm size

To characterize a change in the treated aneurysm size, aneurysm shrinkage was defined as a decrease in aneurysm size of > 5 mm from the post-procedure measurement, aneurysm growth was defined as an increase in aneurysm size of > 5 mm from the post-procedure measurement, and no change was defined as an increase or decrease in aneurysm size ≤ 5 mm from the post-procedure measurement. For patients who did not have a post-procedure measurement, the next available follow-up visit was used as baseline. The changes in aneurysm size, as observed from post-procedure to each follow-up exam (based on core laboratory evaluation), are presented in **Table 6.41**.

**Table 6.41 Aneurysm size changes from pre-discharge to each exam time point**

Exam period		Percent of patients
1-month	Shrinkage	1.6% (1/64)
	No change	98.4% (63/64)
	Growth	0% (0/64)
6-month	Shrinkage	52.6% (40/76)
	No change	47.4% (36/76)
	Growth	0% (0/76)
12-month	Shrinkage	66.2% (47/71)
	No change	32.4% (23/71)
	Growth	1.4% (1/71) <sup>e</sup>
24-month	Shrinkage	70.3% (45/64)
	No change	28.1% (18/64)
	Growth	1.6% (1/64) <sup>f</sup>
36-month	Shrinkage	72.7% (40/55)
	No change	18.2% (10/55)
	Growth	9.1% (5/55) <sup>a,b,d,f,h</sup>
48-month	Shrinkage	75.0% (39/52)
	No change	15.4% (8/52) <sup>i</sup>
	Growth	9.6% (5/52) <sup>b,c,d,f,h</sup>
60-month	Shrinkage	72.7% (32/44)
	No change	15.9% (7/44)
	Growth	11.4% (5/44) <sup>a,f,g,h,j</sup>

<sup>a</sup> Aneurysm expansion due to type II endoleak (patient 0511004).

<sup>b</sup> Aneurysm expansion due to type II endoleak (patient 0111016).

<sup>c</sup> Aneurysm expansion due to type II endoleak (patient 0211010).

<sup>d</sup> Aneurysm expansion due to type II endoleak (patient 0211011).

<sup>e</sup> Aneurysm expansion due to site-reported type II endoleak (patient 1350039); the core laboratory reported that endoleak could not be assessed.

<sup>f</sup> Aneurysm expansion due to type II endoleak (patient 1350008) (site-reported at 48 months).

<sup>g</sup> Aneurysm expansion due to type III endoleak (patient 1350028). See the Rupture section for more details.

<sup>h</sup> Aneurysm expansion due to type II endoleak (patient 1350025). Additional details can be found in the Secondary Interventions section.

<sup>i</sup> The first maximum aneurysm major diameter measurement was provided by core laboratory for patient 1350003 at the 24-month follow-up exam (46.6 mm). Therefore, this patient is not included in this table. This patient had one other aneurysm size measurement at the 48-month time point (45.7 mm).

<sup>j</sup> Aneurysm expansion due to type II endoleak (patient 1350031).

#### Migration

Details regarding the two migration cases are summarized below in **Table 6.42**.

**Table 6.42 Migrations**

Patient number	Time period first identified	Radiographic or clinically significant migration <sup>a</sup>	Description of migration
0511006	24 months	Radiographic and clinically significant migration	In-stent right renal artery stenosis (≥ 60%) was identified by the core laboratory at 24 months. An arteriogram at 883 days post-procedure confirmed 60-70% stenosis of the right renal stent, which was successfully treated with 2 Express™ stents (see the Secondary Interventions section). Primary contributing factor: caudal movement (> 10 mm as determined by the CEC) of proximal component.
0511008	60 months	Radiographic migration	Separation of two barbs identified by the CEC at 24 months, with confirmation at later time periods. At 60 months, the CEC determined that there was caudal movement (> 10 mm) of the proximal component. At 60 months, all vessels targeted by a fenestration remain patent.

<sup>a</sup> Radiographic migration is defined as movement of the stent-graft ≥ 10 mm. Clinically significant migration is defined as movement of the stent-graft that requires surgical or endovascular intervention.

#### Study strengths and weaknesses

The study was well controlled having been conducted in accordance with 21 CFR 812, ICH GCP, and other applicable requirements as appropriate.

Additionally, the study utilized an independent core laboratory to ensure uniform analysis of pre-procedure and follow-up imaging exams.

While the same inclusion/exclusion criteria applied to all patient cohorts comprising the post-approval study (pivotal, continued/extended access, post-approval), the post-approval cohort allowed for both prospective and retrospective enrollment. However, consecutive screening was necessary in order to mitigate any potential for bias.

The comorbid medical conditions of the patient population, which often resulted in death for reasons unrelated to the study aneurysm/device, limited the number of enrolled patients with completed 5-year follow-up. As also described in the Primary Endpoint Results section, a tipping point analysis was performed due to missing 5-year vital status data in 23 patients.

## 7. PATIENT SELECTION AND TREATMENT

(See Warnings and Precautions)

### 7.1 Individualization of treatment

Each patient must be evaluated on an individual basis to determine the specific location of the graft fenestrations (refer to Planning and Sizing Sheet), with careful consideration also given to both the potential benefits and specific risks associated with the procedure.

Considerations regarding the use of the Zenith Fenestrated AAA Endovascular Graft (see Warnings) include:

- Risk of aneurysm rupture
- Morbidity and mortality associated with conventional surgical repair
- Comorbidities
- Size of aneurysm
- History of renal failure
- Life expectancy
- Anesthetic risk
- Age of patient
- Iliofemoral access vessel size and morphology (minimal thrombus, calcification and/or tortuosity) should be compatible with vascular access techniques and accessories of the delivery profile of a 14 French to 22 French vascular introducer sheath.

**NOTE:** Iliac conduits may be used to ensure the safe insertion of the delivery system.

- Non-aneurysmal infrarenal aortic segment (neck) proximal to the aneurysm:
  - with a length that is at least 4 mm and unsuitable for a non-fenestrated graft,
  - with a diameter measured outer wall to outer wall of no greater than 31 mm and no less than 19 mm,
  - with an angle less than 45 degrees relative to the long axis of the aneurysm, and
  - with an angle less than 45 degrees relative to the axis of the suprarenal aorta.
- Ipsilateral iliac artery distal fixation site greater than 30 mm in length and 9-21 mm in diameter (measured outer wall to outer wall).
- Contralateral iliac artery distal fixation site greater than 30 mm in length and 7-21 mm in diameter (measured outer wall to outer wall).
- Freedom from significant femoral/iliac artery occlusive disease that would impede flow through the endovascular graft.

The final treatment decision is at the discretion of the physician and patient.

## 8. PATIENT COUNSELING INFORMATION

The physician and patient (and/or family members) should review the risks and benefits when discussing this fenestrated endovascular device and procedure including:

- Risks and differences between endovascular repair (fenestrated and non-fenestrated) and surgical repair
- Potential advantages of traditional open surgical repair
- Potential advantages of fenestrated endovascular repair
- The possibility that subsequent interventional or open surgical repair of the aneurysm may be required after initial endovascular repair.

In addition to the risks and benefits of an endovascular repair, the physician should assess the patient's commitment and compliance to post-operative follow-up as necessary to ensure continuing safe and effective results. Listed below are additional topics to discuss with the patient as to expectations after an endovascular repair:

- There have been limited numbers of patients treated with fenestrated endovascular grafts when compared to non-fenestrated endovascular grafts
- Long-term performance of fenestrated endovascular grafts and stents in the fenestrations/scallops has not yet been established
- All patients should be advised that endovascular treatment requires life-long, regular follow-up to assess their health and the performance of their endovascular graft
- Patients with specific clinical findings (e.g., endoleaks, enlarging aneurysms, changes in the structure or position of the endovascular graft, or stenosis/occlusion of vessels accommodated by fenestrations) should receive enhanced follow-up.

Specific follow-up guidelines are described in **Section 12, Imaging guidelines and post-operative follow-up.**

## 9. HOW SUPPLIED

The Zenith Fenestrated AAA Endovascular Graft is supplied sterile and pre-loaded in peel-open packages. The device is intended for single use only and the fenestration/scallop location is individually tailored for each patient. Do not re-sterilize the device. Inspect the device and packaging to verify that no damage has occurred as a result of shipping. Do not use this device if damage has occurred or if the sterilization barrier has been damaged or broken. If damage has occurred, do not use the product and return to your Cook representative or your nearest Cook office. Prior to use, verify correct devices (quantity and size) have been supplied for the patient by matching the device to the order prescribed by the physician for that particular patient. Do not use after the expiration date printed on the label. Store in a cool dry place. The proximal body and distal bifurcated body grafts are loaded into either a 6.7 mm I.D. (20 French) or 7.3 mm I.D. (22 French) Flexor introducer sheath. The sheath's surface is treated with a hydrophilic coating that, when activate, enhances trackability. To activate the hydrophilic coating, the surface must be wiped with a 4X4 gauze pad soaked in saline solution.

## 10. CLINICAL USE INFORMATION

### 10.1 Physician training

**CAUTION:** Always have a vascular surgery team available during implantation or reintervention procedures in the event that conversion to open surgical repair is necessary.

**CAUTION:** The Zenith Fenestrated AAA Endovascular Graft with the H&L-B One-Shot Introduction System should only be used by physicians and teams trained in vascular interventional techniques and in the use of this device, which requires precise planning/sizing as well as accurate longitudinal positioning and rotational orientation during placement. The recommended skill/knowledge requirements for physicians using the Zenith Fenestrated AAA Endovascular Graft with the H&L-B One-Shot Introduction System are outlined below:

#### Patient selection:

- Knowledge of the natural history of abdominal aortic aneurysms (AAA) and co-morbidities associated with AAA repair
- Knowledge of radiographic image interpretation, device/fenestration selection and sizing.

#### A multi-disciplinary team that has combined procedural experience with:

- Femoral cutdown, arteriotomy and repair
- Percutaneous access and closure techniques
- Non-selective and selective wire guide and catheter techniques, especially accessing visceral vessels (e.g., renal arteries)
- Fluoroscopic and angiographic image interpretation
- Embolization
- Angioplasty
- Endovascular stent-graft placement
- Renal/visceral stent placement
- Snare techniques
- Appropriate use of radiographic contrast material
- Techniques to minimize radiation exposure
- Expertise in necessary patient follow-up modalities.

### 10.2 Inspection prior to use

Inspect the device and packaging to verify that no damage has occurred as a result of shipping. Do not use this device if damage has occurred or if the sterilization barrier has been damaged or broken. If damage has occurred, do not use the product and return to your Cook representative or your nearest Cook office. Prior to use, verify correct devices (quantity and size) have been supplied for the patient by matching the device to the order prescribed by the physician for that particular patient.

### 10.3 Materials required

(Not included in 3-piece modular system)

- Zenith AAA Endovascular Graft Ancillary Kit
- Fluoroscope with digital angiography capabilities (C-arm or fixed unit)
- Contrast media
- Syringe
- Heparinized saline solution.

### 10.4 Materials recommended

(Not included in 3-piece modular system)

The following products are recommended:

- .035 inch (0.89 mm) extra stiff wire guide, 260 cm; for example:
  - Cook Amplatz Ultra Stiff Wire Guides (AUS)
  - Cook Lunderquist Extra Stiff Wire Guides (LES)
- .035 inch (0.89 mm) standard wire guide; for example:
  - Cook .035 inch wire guides
  - Cook Nimble™ Wire Guides
  - Cook Rosen Wire Guide
- Molding Balloons (e.g., CODA)
- Zenith Alignment Stents
- Introducer sets; for example:
  - Cook Check-Flo® Introducer Sets
  - Cook Extra Large Check-Flo Introducer Sets
  - Cook Flexor® Balkin Up & Over® Contralateral Introducers
- Sizing catheter; for example:
  - Cook Auros® Centimeter Sizing Catheters
- Angiographic radiopaque tip catheters; for example:
  - Cook Beacon® Tip Angiographic Catheters
  - Cook Beacon Tip Royal Flush Catheters
- Entry needles; for example:
  - Cook single wall entry needles.

### 10.5 Device diameter sizing guidelines

The choice of diameter should be determined from the outer wall to outer wall vessel diameter and not the lumen diameter. Undersizing or excessive oversizing may result in incomplete sealing or comprised flow.

**Table 10.5.1 Proximal body graft diameter sizing**

Intended aortic vessel diameter	Main body diameter	Introduction sheath Fr	Introduction sheath I.D./O.D.
19	24	20	6.7 mm/7.7 mm
20	24	20	6.7 mm/7.7 mm
21	24	20	6.7 mm/7.7 mm
21	26	20	6.7 mm/7.7 mm
22	26	20	6.7 mm/7.7 mm
23	28	20	6.7 mm/7.7 mm
24	28	20	6.7 mm/7.7 mm
24	30	20	6.7 mm/7.7 mm
25	30	20	6.7 mm/7.7 mm
26	30	20	6.7 mm/7.7 mm
26	32	20	6.7 mm/7.7 mm
27	32	20	6.7 mm/7.7 mm
28	32	20	6.7 mm/7.7 mm
28	34	20	6.7 mm/7.7 mm
29	34	20	6.7 mm/7.7 mm
29	36	22	7.3 mm/8.5 mm
30	36	22	7.3 mm/8.5 mm
31	36	22	7.3 mm/8.5 mm



**Table 10.5.2 Distal body (ipsilateral limb) graft diameter sizing**

Intended iliac vessel diameter	Ipsilateral limb diameter	Introduction sheath Fr	Introduction sheath I.D./O.D.
9	12	20	6.7 mm/7.7 mm
10	12	20	6.7 mm/7.7 mm
11	12	20	6.7 mm/7.7 mm
12	16	20	6.7 mm/7.7 mm
13	16	20	6.7 mm/7.7 mm
14	16	20	6.7 mm/7.7 mm
15	16	20	6.7 mm/7.7 mm
15	20	20	6.7 mm/7.7 mm
16	20	20	6.7 mm/7.7 mm
17	20	20	6.7 mm/7.7 mm
18	20	20	6.7 mm/7.7 mm
18	24	20	6.7 mm/7.7 mm
19	24	20	6.7 mm/7.7 mm
20	24	20	6.7 mm/7.7 mm
21	24	20	6.7 mm/7.7 mm

**10.6 Device length sizing guidelines**

The proximal body graft and distal body graft are available in multiple lengths. The chosen lengths should provide a minimum two-stent overlap should the graft components align completely along the greater curve of the aorta/aneurysm over time. Planning for a longer overlap length initially (e.g., 3-4 stents) is therefore preferable.

**Table 10.6.1 Proximal graft lengths**

Diameter mm	Body length mm
24	76 / 91 / 94 / 106 / 109 / 121 / 124
26	76 / 91 / 94 / 106 / 109 / 121 / 124
28	76 / 91 / 94 / 106 / 109 / 121 / 124
30	76 / 91 / 94 / 106 / 109 / 121 / 124
32	76 / 91 / 94 / 106 / 109 / 121 / 124
34	84 / 99 / 114 / 129 / 107 / 122 / 137
36	84 / 99 / 114 / 129 / 107 / 122 / 137

**Table 10.6.2 Distal graft lengths**

Ipsilateral limb diameter mm	Body length mm	Ipsilateral limb length mm
12	76 / 91 / 106 / 121	28 / 45 / 62
16	76 / 91 / 106 / 121	28 / 45 / 62
20	76 / 91 / 106 / 121	28 / 45 / 62
24	76 / 91 / 106 / 121	28 / 45 / 62

**10.7 Graft fenestration/scallop guidelines**

The proximal body graft may contain up to three precisely located holes (fenestration(s)), and cut-outs from the proximal margin (scallop(s)) of the graft material. The fenestration and/or scallop locations are individualized to the patient anatomy based on measurements from high resolution pre-operative CT imaging. Refer to the Planning and Sizing Sheet for information regarding how these locations are determined.

**11. INSTRUCTIONS FOR USE****11.1 General use information**

Prior to use of the Zenith Fenestrated AAA Endovascular Graft with the H&L-B One-Shot Introduction System, review this Suggested Instructions for Use booklet. The following instructions embody a basic guideline for device placement. Variations in the following procedures may be necessary.

These instructions are intended to help guide the physician and do not take the place of physician judgment.

**11.2 Pre-implant determinants**

Verify from pre-implant planning (refer to Planning and Sizing Sheet) that the correct device has been selected. Determinants include:

1. Femoral artery selection for introduction of the main body system, (i.e., define respective contralateral and ipsilateral iliac arteries).
2. Angulation of aortic neck, aneurysm and iliacs.
3. Quality of the aortic neck.
4. Diameters of infrarenal aortic neck and distal iliac vessels.
5. Distance from renal arteries to the aortic bifurcation.
6. Distance from the renal arteries to the hypogastric (internal iliac) arteries/attachment site(s).
7. Aneurysm(s) extending into the iliac arteries may require special consideration in selecting a suitable graft/artery interface site.
8. Consider the degree of vascular calcification.
9. Size and location/position of visceral vessel origins.

**NOTE:** Each respective vessel diameter and length (aorta, ipsilateral iliac and contralateral iliac) provides the necessary criteria for choosing the appropriate endovascular graft.

**11.3 Patient preparation**

1. Refer to institutional protocols relating to anesthesia, anticoagulation and monitoring of vital signs.
2. Position patient on imaging table allowing fluoroscopic visualization from the aortic arch to the femoral bifurcations.
3. Expose both common femoral arteries using standard surgical technique.
4. Establish adequate proximal and distal vascular control of both femoral vessels.

**11.4 Fenestrated system****11.4.1 Proximal body graft preparation/flush**

1. Remove black-hubbed shipping stylet (from the inner cannula), cannula protector tube (from the inner cannula) and dilator tip protector (from the dilator tip). Remove Peel-Away® sheath from back of the Captor hemostatic valve. (Figure 6) Elevate distal tip of system and flush through the stopcock on the hemostatic valve until fluid emerges from the flushing groove in the tip. (Figure 7) Continue to inject a full 20 cc of flushing solution through the device. Discontinue injection and close stopcock on connecting tube.

**NOTE:** Graft flushing solution of heparinized saline is often used.

2. Attach syringe with normal heparinized saline to the hub on the inner cannula. Flush until fluid exits the distal tip. (Figure 8)

**NOTE:** When flushing system, elevate distal end of system to facilitate removal of air.

3. Soak 4X4 gauze pad in saline solution and use to wipe Flexor introducer sheath to activate the hydrophilic coating. Hydrate both sheath and dilator tip liberally.

**11.4.2 Distal bifurcated body graft preparation/flush**

1. Remove black-hubbed shipping stylet (from the inner cannula), cannula protector tube (from the inner cannula) and dilator tip protector (from the dilator tip). Remove Peel-Away sheath from back of the Captor hemostatic valve. (Figure 9) Elevate distal tip of system and flush through the stopcock on the hemostatic valve until fluid emerges from the flushing groove in the tip. (Figure 10) Continue to inject a full 20 cc of flushing solution through the device. Discontinue injection and close stopcock on connecting tube.

**NOTE:** Graft flushing solution of Heparinized saline is always used.

2. Attach syringe with normal Heparinized saline to the hub on the inner cannula. Flush until fluid exits the distal tip. (Figure 10)

**NOTE:** When flushing system, elevate distal end of system to facilitate removal of air.

3. Soak 4X4 gauze pad in saline solution and use to wipe Flexor introducer sheath to activate the hydrophilic coating. Hydrate both sheath and dilator tip liberally.

**11.4.3 Iliac leg (contralateral) preparation/flush**

Refer to the Instructions for Use enclosed in the device packaging for the iliac leg graft for instruction on preparation/flush.

**11.4.4 Vascular access and angiography**

1. Puncture the selected common femoral arteries using standard technique with an 18 or 19UT gage arterial needle. Upon vessel entry, insert:

- Wire guides - standard .035 inch diameter, 145 cm long, J tip or Bentson Wire Guide
- Appropriate size sheaths (e.g., 6.0 or 8.0 French)
- Flush catheter (often radiopaque sizing catheters - e.g., Centimeter Sizing Catheter or straight flush catheter).

2. Perform angiography to identify level(s) of renals, aortic bifurcation and iliac bifurcations.

**NOTE:** If fluoroscope angulation is used with an angulated neck it may be necessary to perform angiograms using various projections.

**NOTE:** A previous planning exercise will have determined which side will be used to introduce the proximal and distal bodies.

**11.4.5 Proximal body placement**

**CAUTION: Verify that the predetermined access site is chosen for the introduction and placement of the proximal body.**

1. Ensure the delivery system has been flushed with heparinized saline and that all air is removed from the system.
2. Give systemic heparin and check flushing solutions. Flush after each catheter and/or wire guide exchange.

**NOTE:** Monitor the patient's coagulation status throughout the procedure.

3. On ipsilateral side, replace J wire with stiff wire guide (LES) .035 inch, 260 cm long and advance through catheter and up to the thoracic aorta. Remove flush catheter and sheath. Maintain wire guide position.

**NOTE:** A straight angiographic catheter should be inserted up the contralateral side to aid in placement of graft.

4. Before insertion, position proximal body delivery system on patient's abdomen under fluoroscopy to assist with orientation and positioning. Rotate to a position where the anterior markers are situated in the most anterior (12:00 o'clock) position. The sidearm of the hemostatic valve may serve as an external reference to the fenestration(s) and/or scallop(s), anterior and posterior markers and body side markers.

**CAUTION: Maintain wire guide position during delivery system insertions.**

**CAUTION: To avoid any twist in the endovascular graft, during any rotation of the delivery system, be careful to rotate all of the components of the system together (from outer sheath to inner cannula).**

5. Advance the delivery system until the radiopaque markers indicating the fenestration(s) and/or scallop(s) are at the level of the appropriate arteries. Check that the distal end of the graft is in a satisfactory position above the aortic bifurcation and that the anterior and posterior markers indicate that the graft is in satisfactory orientation. (Figure 11)

**NOTE:** Angiography should be performed as needed throughout deployment, to confirm correct placement of the graft.

6. Verify position of the wire guide in the thoracic aorta. Ensure that fenestration(s) and/or scallops are at the level of the appropriate arteries and the anterior markers are in the most anterior (12:00 o'clock) position.

**NOTE:** The vertical anterior markers, and the horizontal posterior markers should form a cross, on the fluoroscopic image, when correctly oriented. (Figure 11)

**NOTE:** The fenestration/scallop markers should be in close apposition to the appropriate side branch vessels.

Clear identification of fenestration position(s) may not be possible until the graft has been partially unsheathed.

**NOTE:** Ensure the Captor Hemostatic Valve on the introducer sheath is turned to the open position. (Figure 12)

7. Stabilize the grey positioner (the shaft of the delivery system) while withdrawing the sheath. Deploy the first two (2) covered stents by withdrawing the sheath while monitoring device location.

8. Perform angiography, and adjust graft placement as necessary. Continue to withdraw the sheath making positional adjustments as necessary.

**NOTE:** Techniques to ensure that the fenestration(s) and/or scallop(s) will accurately align with their respective vessels will vary, and will depend upon vessel anatomy, graft design, and physician preferences.

**NOTE:** If a small fenestration is being utilized, care should be taken to properly align the fenestration with the respective vessel.

9. Proceed with deployment until the graft has been fully unsheathed. (Figure 13)

10. When a satisfactory graft position has been achieved, exchange the contralateral angiographic catheter and wire guide with a selective wire guide/selective catheter positioned just below the level of the proximal body. Cannulate the partially deployed proximal main body. Advance the selective catheter over the selective wire guide into

the renal artery. Exchange the selective wire with a Rosen wire or equivalent wire guide.

- Utilizing contralateral access sheath and wire guide, advance a guiding catheter into each small fenestration and its respective vessel. (Figure 14)

**NOTE:** Non-compliant angioplasty balloons may be used as an alternative to guiding catheters.

**NOTE:** Cannulation of the scallop and its respective vessel may also be achieved using similar techniques.

**NOTE:** It is not recommended to use balloons or guiding catheters to guide final placement of large fenestrations as stent struts across fenestration may interfere.

**NOTE:** To ensure renal stent placement in the lower portion of the fenestration, it may be necessary to slightly advance the graft after catheter/sheath access to the renal vessels, before removal of the diameter reducing ties.

**CAUTION:** Before release of the diameter reducing ties, verify that the position of the ipsilateral access wire extends just distal to the aortic arch.

**CAUTION:** During proximal trigger-wire removal, top cap advancement, and subsequent suprarenal stent deployment, verify that the position of the main body wire guide extends just distal to the aortic arch and that support of the system is maximized.

- Verify proper position of proximal body. Remove the safety lock from the first (distal) gold trigger-wire release mechanism. Withdraw and remove the trigger-wire by sliding the gold trigger-wire release mechanism off the handle and then remove via its slot over the inner cannula. (Figure 15)

**NOTE:** At this point, the proximal main body graft should be fully expanded with the proximal bare stent contained within the top cap.

- Remove the safety lock from the top stent trigger-wire release mechanism. Under fluoroscopy, withdraw and remove the trigger-wire to unlock the suprarenal stent from the top cap by sliding the black trigger-wire release mechanism off the handle and then remove via its slot over the inner cannula. (Figure 16)

**NOTE:** If resistance is felt or system bowing is noticed, the trigger-wire is under tension. Excessive force may cause the graft position to be altered. If excessive resistance or delivery system movement is noted, stop and assess the situation.

If unable to remove the black trigger-wire release mechanism from the top cap, perform the following steps under fluoroscopy:

- Remove tension on the trigger-wire by loosening the pin vise and slightly pulling the inner cannula to move the top cap down over the suprarenal stent. Avoid compressing the Zenith Fenestrated proximal body.
- Retighten the pin vise.
- Remove the black trigger-wire release mechanism.

d. Continue with (14) in Section 11.4.5, Proximal body placement.

**NOTE:** If still unable to remove the black trigger-wire release mechanism from the top cap, see Section 13 Trigger-Wire Release Troubleshooting.

**NOTE:** The distal stent is still secured by the trigger-wire.

- Loosen the pin vise. (Figure 17) Control the position of the graft by stabilizing the grey positioner of the introducer.

**CAUTION:** Before deployment of the suprarenal stent, verify that the position of the access wire extends just distal to the aortic arch. Ensure that the dilator tip will not extend beyond the end of the access wire guide during advancement, and if required re-position the access wire guide into the aortic arch to accommodate.

- Deploy the suprarenal stent by advancing the top cap inner cannula 1 to 2 mm at a time while controlling the position of the proximal body until the top stent is fully deployed. (Figures 18a and 18b) Advance the top cap cannula an additional 1 to 2 cm and then retighten the pin vise to avoid contact with the deployed suprarenal stent.

**WARNING:** The Zenith Fenestrated AAA Endovascular Graft incorporates a suprarenal stent with fixation barbs. Exercise extreme caution when manipulating interventional devices in the region of the suprarenal stent.

**NOTE:** If unable to deploy the suprarenal stent by advancing the top cap, see Section 14, Suprarenal stent deployment troubleshooting.

- Remove the safety lock from the second (proximal) white trigger-wire release mechanism. Withdraw and remove the trigger-wire to detach the distal end of the endovascular graft from the delivery system by sliding the white trigger-wire release mechanism off the handle and then remove via its slot over the device inner cannula. (Figure 19)

**NOTE:** Check to make sure that all trigger-wires are removed prior to withdrawal of the delivery system.

#### 11.4.6 Docking of top cap

- Loosen the pin vise. (Figure 20)
- Secure sheath and inner cannula to avoid any movement of these components.
- Advance the grey positioner over the inner cannula until it docks with the top cap. (Figures 21a, 21b and 21c)

**NOTE:** If resistance occurs, slightly rotate grey positioner and continue to gently advance.

- Retighten the pin vise and withdraw the entire top cap and grey positioner through the graft and through the sheath by pulling on the pink hub of the inner cannula. (Figure 22) Leave the sheath and wire guide in place.
- Close the Captor Hemostatic Valve by turning it in a clockwise direction until it stops.

#### 11.4.7 Fenestration stent placement and deployment

##### General use information

In the event that small fenestrations are being utilized, stents may be placed to secure positive alignment. Standard techniques for placement of arterial stents should be employed during use of stents. The Zenith Alignment Stent is available for this purpose. Refer to the Zenith Alignment Stent Suggested Instructions for Use for details.

- Return to the guide catheter and wire guide which cannulate the small fenestration and respective vessel.
- Introduce appropriately sized balloon expandable stent and advance to the ostium of the fenestration/vessel. Advance stent partially into the vessel, leaving approximately 4-5 mm of stent in the aorta. (Figure 23)

**NOTE:** Fluoroscopic views tangential to the fenestration will optimize visualization of the stent position relative to the stent graft.

- Expand stent.

- Remove the balloon and replace with an oversized angioplasty balloon.

Advance the balloon until the proximal tip is positioned at the ostium.

- Inflate the balloon to flare the intra-aortic segment of the stent.

(Figure 24)

**CAUTION:** This technique requires high quality imaging. Mobile image intensifiers may provide less than adequate imaging quality.

- Remove the angioplasty balloon.

- Withdraw renal access sheaths, catheters and wire guides in the contralateral side to a level just above the aortic bifurcation.

**NOTE:** In the event that there is more than one fenestration, repeat the preceding steps for each additional small fenestration.

#### 11.4.8 Distal bifurcated body placement

- Ensure the delivery system has been flushed with heparinized saline and that all air is removed from the system.

- Check flushing solutions. Flush after each catheter and/or wire guide exchange.

- Before insertion, position distal bifurcated body delivery system on patient's abdomen under fluoroscopy to determine the orientation of the contralateral limb. The side arm of the hemostatic valve may serve as an external reference to the contralateral limb radiopaque marker.

**NOTE:** Distal bifurcated body delivery system will not pass through the sheath used to deliver the proximal body.

**NOTE:** The proximal body delivery sheath must be removed prior to insertion of the distal bifurcated body delivery system.

- Insert Distal Bifurcated Body delivery system over the wire, into the femoral artery with attention to sidearm reference.

**CAUTION:** Maintain wire guide position during delivery system insertion.

**CAUTION:** To avoid any twist in the endovascular graft, during any rotation of the delivery, be careful to rotate all of the components of the system together (from outer sheath to inner cannula).

- Advance delivery system until the contralateral limb is positioned in suitable orientation above and anterior to the origin of the contralateral iliac. (Figure 25) If the contralateral limb radiopaque marker is not properly aligned, rotate the entire system until it is.

- Repeat angiogram to verify:

- The degree of overlap with proximal body (no less than 2 stents)
- The position of the contralateral limb
- The position of the ipsilateral iliac limb with respect to the common iliac bifurcation.

Reposition distal bifurcated body as required.

**CAUTION:** When introducing distal bifurcated body, observe proximal body closely to avoid any disruption to its position.

**NOTE:** Ensure the Captor Hemostatic Valve on the introducer sheath is turned to the open position. (Figure 26)

- Stabilize the grey positioner (the shaft of the delivery system) while withdrawing the sheath. Deploy the first two (2) covered stents by withdrawing the sheath while monitoring device location. Proceed with deployment until contralateral limb is fully deployed. (Figure 27)

#### 11.4.9 Contralateral iliac wire guide placement

- Manipulate the wire guide from the contralateral side and into the contralateral limb and into the Distal Bifurcated Body. (Figure 28) AP and oblique fluoroscopic views can aid in verification of device cannulation.

- Advance the angiographic catheter into the body of the graft to the level of the overlap between the proximal and distal graft components. Perform angiography to confirm correct position inside the Distal Bifurcated Body. Advance the catheter to where the proximal end of the Distal Bifurcated Body is attached to the introducer.

#### 11.4.10 Distal bifurcated body deployment

- Perform angiography to confirm proper position of the ipsilateral iliac leg with respect to the internal iliac (hypogastric) artery. Adjust position if necessary.

- Withdraw sheath until the iliac leg is fully deployed.

- Remove the safety lock from the black trigger-wire release mechanism. Withdraw and remove the trigger-wire by sliding the black trigger-wire release mechanism off the handle and then remove via its slot over the device inner cannula. (Figure 29)

- Advance the contralateral catheter to above the level of the proximal graft, and pass a supportive wire guide (AUS or LES) through it to the level of the arch. Remove the catheter.

#### 11.4.11 Iliac leg (contralateral) placement

Refer to the Instructions for Use enclosed in the device packaging for the iliac leg graft. Once placement of the contralateral iliac leg is complete, continue with deployment of the distal bifurcated body. (Section 11.4.12)

#### 11.4.12 Distal bifurcated body deployment (continued)

- Remove the safety lock from the white trigger-wire release mechanism. Withdraw and remove the trigger-wire by sliding the white trigger-wire release mechanism off the handle and then remove via its slot over the device inner cannula. (Figure 30)

- Under fluoroscopy and after verification of iliac leg graft position, withdraw grey positioner with secured inner cannula.

- Re-check the position of the wire guides. Leave sheath and wire guide in place.

- Close the Captor Hemostatic Valve on the introducer sheath by turning in a clockwise direction until hemostasis is achieved. (Figure 31)

#### 11.4.13 Molding balloon insertion

- Prepare Molding balloon as follows:

- Flush wire lumen with heparinized saline.
- Remove all air from balloon.

- In preparation for the insertion of the molding balloon, open the Captor Hemostatic Valve by turning it counter-clockwise.

- Advance the Molding balloon over the wire guide and through the Captor Hemostatic Valve of the distal bifurcated body introduction system to level of renal arteries. Maintain proper sheath positioning.

**NOTE:** Captor Hemostatic Valve may be utilized to assist with hemostasis by turning in a clockwise rotation to the "close" position.

**NOTE:** Captor Hemostatic Valve should always be in the "open" position when repositioning of molding balloon.

- Expand the molding balloon with diluted contrast media (as directed by the manufacturer) in the area of the suprarenal stent and the infrarenal neck, starting proximally and working in the distal direction. (Figure 32)

**CAUTION: Prior to molding in the vicinity of any Fenestration stent(s) confirm that the aortic section of the stent has been flared.**

**CAUTION: Confirm complete deflation of balloon prior to repositioning.**

- Withdraw the Molding balloon to the ipsilateral limb distal fixation site and expand.

**CAUTION: Do not inflate balloon in the vessel outside of graft, as doing so can result in vessel damage (e.g., rupture).**

- Deflate and remove molding balloon. Transfer the molding balloon onto the contralateral wire guide and into the contralateral iliac leg introduction system. Advance molding balloon to the contralateral limb overlap and expand.

**CAUTION: Confirm complete deflation of balloon prior to repositioning.**

- Withdraw the molding balloon to the contralateral iliac leg/vessel distal fixation and expand. (Figure 32)

**CAUTION: Do not inflate balloon in the vessel outside of graft, as doing so can result in vessel damage (e.g., rupture).**

- Remove molding balloon and replace it with an angiographic catheter to perform completion angiograms.
- Remove or replace all stiff wire guides to allow iliac arteries to resume their natural position.

#### Final angiogram

- Position angiographic catheter just above the level of the branch vessel(s) accommodated by a fenestration/scallop. Perform angiography to verify branch vessel (e.g., renal artery, superior mesenteric artery) patency and that there are no endoleaks. Verify patency of internal iliac arteries.
- Confirm there are no endoleaks or kinks and verify position of proximal gold radiopaque markers. Remove the sheaths, wires and catheters.

**NOTE:** If endoleaks or other problems are observed, refer to **Section 1.6, Ancillary components.**

- Repair vessels and close in standard surgical fashion.

## 12. IMAGING GUIDELINES AND POST-OPERATIVE FOLLOW-UP

### 12.1 General

All patients should be advised that endovascular treatment with this device requires lifelong, regular follow-up to assess their health and the performance of their endovascular graft. Patients with specific clinical findings (e.g., endoleaks, enlarging aneurysms, or changes in the structure or position of the endovascular graft) may require additional follow-up. Patients should be counseled on the importance of adhering to the follow-up schedule, both during the first year and at yearly intervals thereafter. Patients should be informed that regular and consistent follow-up is a critical part of ensuring the ongoing safety and effectiveness of endovascular treatment of abdominal aneurysms with this device. Physicians should evaluate patients on an individual basis and prescribe follow-up relative to the needs and circumstances of each individual patient.

Please refer to **Table 12.1** for recommended imaging and post-operative follow-up requirements. Precise planning and sizing of the Zenith Fenestrated AAA Endovascular Graft requires high resolution CT pre-procedure in order to obtain accurate measurements for determining graft size (diameter and length) and fenestration/scallop location. Regular follow-up imaging is important to monitor the performance of the device, allowing for timely reintervention if necessary. The imaging recommended at follow-up (CT/X-ray) is the same as for a non-fenestrated device and is intended to similarly provide for an assessment of device integrity, endoleak, change in aneurysm size, and device position (migration, component overlap). Following placement of a fenestrated graft, it is also important to evaluate the patency of vessels accommodated by fenestrations, which can also be supported by high resolution CT imaging. Duplex ultrasound may also be a useful screening tool in assessing the patency of vessels accommodated by a fenestration, provided the results are interpreted using appropriate criteria.

**Table 12.1 Recommended imaging and post-operative follow-up schedule**

	Pre-procedure	Procedure	30-day	6-month (optional)	12-month <sup>3</sup>
Clinical exam	X		X	X	X
CT	X		X <sup>1</sup>	X <sup>1</sup>	X <sup>1</sup>
Device x-ray			X	X	X
Angiography	X <sup>2</sup>	X			
Renal Duplex Ultrasound	X		X	X	X
Blood Tests (Serum Creatinine, BUN)	X		X	X	X

<sup>1</sup> Duplex ultrasound along with a non-contrast CT may be used to assess the aneurysm for those patients experiencing renal failure or who are otherwise unable to undergo contrast enhanced CT scan.

<sup>2</sup> Pre-procedure angiography may be required at discretion of implanting physician or film reviewer.

<sup>3</sup> Annually thereafter.

### 12.2 Angiography

Angiographic imaging is recommended during the procedure to evaluate anatomy and facilitate device placement. In addition, selective catheterization of the visceral vessels targeted by a fenestration is recommended. At the completion of the procedure, patency of the following arteries: aorta, celiac, superior mesenteric, right and left renals and/or accessory renals, and right and left internal external iliac arteries should be evaluated. Pre-procedural angiography may be required at the discretion of the implanting physician or film reviewer.

### 12.3 Computed tomography (CT)

High resolution CT imaging is recommended pre-procedure in order to obtain accurate measurements for determining graft size (diameter and length) and fenestration/scallop location. CT images are also recommended at 30 days post-procedure, optionally at 6 months post-procedure and yearly thereafter to provide for an assessment of endoleak, change in aneurysm size, and device position (migration, component overlap). Following placement of a fenestrated graft, it is also important to evaluate the patency of vessels accommodated by fenestrations, which can also be supported by high resolution CT imaging.

**Table 12.3.1** lists the general scan parameters for evaluation of patients with the Zenith Fenestrated AAA Endovascular Graft.

**Table 12.3.1 Recommended CT imaging parameters  
Recommendations for optimal imaging**

Scan parameters	Recommendations for optimal imaging
Acceptable machines	Spiral CT or high performance MDCT capable of >40 seconds
Scan Parameters	Optimize the technique for body habitus and slice thickness
Superior Extent	Above diaphragm
Inferior Extent	Proximal femur
Slice Thickness	≤1.0 mm
Slice Spacing	At least 50% overlap
Field of View (FOV)	Adjust for body habitus (include all anatomy / soft tissue)
IV Contrast	100-200 cc, tailored to the needs or limitations of individual patient
Reconstruction Algorithm	1 mm throughout

### 12.4 Device x-ray

X-rays are recommended at 30 days post-procedure, optionally at 6 months post-procedure and yearly thereafter as an adjunct to CT to assess device integrity. It is important to ensure that the entire device is captured on the images for device assessment. Recommended imaging parameters include:

- The patient be in the supine position
- 40 inch focal film distance (FFD)
- Obtain 4 views: AP, LAT, 30° RPO, and 30° LPO centered on umbilicus
- In order to properly penetrate and expose the abdomen utilize lumbar spine technique, center photo cell or manual technique.

### 12.5 Renal duplex ultrasound

Duplex ultrasound may be used as a screening tool for assessing the patency of vessels to be accommodated by a fenestration both pre- and post-procedure. Duplex ultrasound can be an important adjunct to non-contrast enhanced CT in patients with renal failure or who are otherwise contraindicated to receive iodinated contrast. The following information should be included in the evaluation if duplex ultrasound is performed:

- Transverse and longitudinal imaging from the level of the proximal abdominal aorta - demonstrating celiac, mesenteric and renal arteries - to the iliac bifurcations to verify if endoleaks are present and vessels are patent utilizing color flow and color power Doppler (if accessible)
- Spectral analysis confirmation of any suspected endoleaks
- Transverse and longitudinal imaging of the maximum aneurysm diameter.

### 12.6 MRI safety and compatibility

For MRI Safety and Compatibility refer to **Section 4.5.**

### 12.7 Supplemental imaging

Additional radiological imaging may be necessary to further evaluate the endovascular graft in situ based on findings revealed by previous imaging assessments. The following recommendations may be considered.

- If there is evidence of poor or irregular position of the endovascular graft, severe angulation, kinking, or migration of the endovascular graft on X-rays, a spiral CT should be performed to assess aneurysm size and the presence or absence of an endoleak.
- If a new endoleak or increase in AAA size is observed by spiral CT, adjunctive studies such as 3-D reconstruction or angiographic assessment of the endovascular graft and native vasculature may be helpful in further evaluating any changes of the endovascular graft or aneurysm.
- Spiral CT without contrast or Renal Duplex Ultrasound may be considered in select patients who cannot tolerate contrast media or who have renal function impairment. For centers with appropriate expertise, gadolinium or CO<sub>2</sub> angiography may be considered in patients with renal function impairment requiring angiographic assessment.

## 13. TRIGGER-WIRE RELEASE TROUBLESHOOTING

**CAUTION: The following steps should be performed only if unable to remove the proximal trigger-wire as described in Section 11.4.5, Proximal body placement (13).**

**NOTE:** Technical assistance from a Cook product specialist may be obtained by contacting your local Cook representative.

### 13.1 Alternate proximal body deployment

- Cut the exposed suprarenal stent trigger-wire between the white and black release mechanisms (Figure 33) and remove the black release mechanism from the handle.
- Remove the safety lock from the white (distal) trigger-wire release mechanism.
- Withdraw the white trigger-wire release mechanism and then remove via its slot over the device inner cannula.

**NOTE:** This will detach the distal end of the graft from the grey positioner.

- Using locking forceps, clamp and secure the cut end of the suprarenal stent trigger-wire. (Figure 34)

- Loosen the pin vise and, while maintaining inner cannula and trigger-wire position, advance the grey positioner and sheath into the graft until the tip of the grey positioner is approximately 2 cm from the gold markers on the proximal edge of the proximal body (Figure 35). The advanced grey positioner provides added support to the inner cannula.

**NOTE:** Take care when advancing the grey positioner as there will be sheaths and wire guides positioned in target vessels. Ensure that the tip of the grey positioner is not advanced into the top cap.

**NOTE:** Maintain gentle tension on the suprarenal stent trigger-wire to remove any slack in the wire as the grey positioner and sheath are being advanced.

- Lock the pin vise. Confirm that the suprarenal stent trigger-wire is secured by the forceps.
- Stabilize the grey positioner and slowly advance the sheath until the sheath tip is 2 mm from the gold markers. (Figure 36)

**NOTE:** Take care when advancing the sheath as there will be other sheaths and wire guides positioned in target vessels. Take care not to advance the graft itself during sheath advancement.

- Stabilize the sheath and slightly retract the grey positioner with inner cannula to move the top cap down over the suprarenal stent (Figure 37).

**NOTE:** Avoid compressing the body of the graft.

- Ensure the fenestrations are positioned correctly. Test the resistance on the trigger wire and make minor adjustments as necessary to reduce trigger wire resistance (Section 13.1, 8).

- Remove the suprarenal stent trigger-wire.

- Withdraw the sheath until the tapered tip of the grey positioner is exposed.

- If there are multiple fenestrations, withdraw all but one of the fenestration guiding catheters. It is the physician's preference as to which guiding catheter to withdraw. It is recommended that the decision be made based on the ease of cannulation of the fenestrations and their respective vessels. (Figure 38)

**NOTE:** Leave the wire guides in place when removing the guiding catheter(s).

- (a) If there is a single fenestration, then the proximal body needs to be cannulated with a suitable wire guide from the same side as the in-situ guide catheter. This is to allow placement of a molding balloon within the proximal body.

- Advance a molding balloon along the now available wire guide into the proximal body and position it just superior to the distal-most end of the graft.

**NOTE:** When using the molding Balloon, ensure the appropriate sheath is used – either through the in-situ 20 Fr contralateral sheath or, if direct punctures have been used, through a 14 Fr introducer sheath. This will ensure the safe retrieval of the molding balloon.

- Inflate the balloon to the full diameter of the graft. (Figure 39)

- Loosen the pin vise (Figure 40). Control the position of the graft by stabilising the grey positioner and balloon catheter.

**CAUTION: Before deployment of the suprarenal stent, verify that the position of the access wire extends just distal to the aortic arch. Ensure that the dilator tip will not extend beyond the end of the access wire guide during advancement, and if required re-position the access wire guide into the aortic arch to accommodate.**

- Deploy the suprarenal stent by advancing the top cap inner cannula 1 to 2 mm at a time while controlling the position of the proximal body until the top stent is fully deployed (Figures 41 and 42). Advance the top cap cannula an additional 1 to 2 cm and then retighten the pin vise (Figure 43) to avoid contact with the deployed suprarenal stent.

**WARNING: The Zenith Fenestrated AAA Endovascular Graft incorporates a suprarenal stent with fixation barbs. Exercise extreme caution when manipulating interventional devices in the region of the suprarenal stent.**

- If there are multiple fenestrations (Section 13.1, 12), deflate the balloon then withdraw it leaving the wire guide in place

- (a) If there is a single fenestration (Section 13.1, 12a), then the molding balloon and wire guide can be safely removed.

**NOTE:** Care should be taken during removal to not disturb the guide sheath and wire guide, which remain in the target vessel

- Advance the access sheath and aligning stent, which was removed to facilitate the molding balloon, back over the wire guide, through the fenestration and into the respective vessel. (Figure 44)

**NOTE:** Check to make sure that all trigger-wires are removed prior to withdrawal of the delivery system.

### 13.2 Docking of top cap

- Loosen the pin vise. (Figure 45)

- Secure sheath and inner cannula to avoid any movement of these components.

- Advance the grey positioner over the inner cannula until it docks with the top cap. (Figures 46, 47 and 48)

**NOTE:** If resistance occurs, slightly rotate grey positioner and continue to gently advance.

- Retighten the pin vise and withdraw the entire top cap and grey positioner through the graft and through the sheath by pulling on the inner cannula. (Figure 49) Leave the sheath and wire guide in place.

- Close the Captor Hemostatic Valve on the Flexor introducer sheath by turning it in a clockwise direction until it stops.

- Return to Section 11.4.7, Fenestration Stent Placement and Deployment.

## 14. SUPRARENAL STENT DEPLOYMENT TROUBLESHOOTING

**CAUTION: The following steps should be performed only if unable to deploy the suprarenal stent by advancing the top cap as described in Section 11.4.5, Proximal body placement (15).**

**NOTE:** Technical assistance from a Cook product specialist may be obtained by contacting your local Cook representative.

### 14.1 Proximal body placement with distal attachment

If the suprarenal stent cannot be fully deployed by advancing the top cap inner cannula, perform the following steps under fluoroscopy.

- Tighten the pin-vise. If there are multiple fenestrations, withdraw all but one of the fenestration guiding catheters. It is the physician's preference

as to which guiding catheter to withdraw. It is recommended that the decision be made based on the ease of cannulation of the fenestrations and their respective vessels. (Figure 50)

- If there is a single fenestration, then the proximal body needs to be cannulated with a suitable wire guide from the same side as the in-situ guide catheter. This is to allow placement of a molding balloon within the proximal body.

**NOTE:** Leave the wire guides in place when removing the guiding catheter(s).

- Advance a molding balloon along the now available wire guide into the proximal body and position it just superior to the distal-most end of the graft.

**NOTE:** When using the molding Balloon, ensure the appropriate sheath is used – either through the in-situ 20 Fr Contralateral sheath or, if direct punctures have been used, through a 14 Fr introducer sheath. This will ensure the safe retrieval of the molding balloon.

- To add support to the inner cannula, inflate the balloon to the full diameter of the graft. (Figure 51)

- Loosen the pin vise. (Figure 52)

- Control the position of the graft by stabilising the grey positioner and balloon catheter.

**CAUTION: Before deployment of the suprarenal stent, verify that the position of the access wire extends just distal to the aortic arch. Ensure that the dilator tip will not extend beyond the end of the access wire guide during advancement, and if required re-position the access wire guide into the aortic arch to accommodate.**

- Deploy the suprarenal stent by advancing the top cap inner cannula 1 to 2 mm at a time while controlling the position of the proximal body until the top stent is fully deployed. (Figures 53 and 54) Advance the top cap cannula an additional 1 to 2 cm and then retighten the pin vise (Figure 55) to avoid contact with the deployed suprarenal stent.

**NOTE:** Care should be taken during removal to not disturb the guide sheath and wire guide(s), which remain in the target vessel(s).

**If the suprarenal stent is fully deployed:**

- If there are multiple fenestrations (Section 14.1, 1), deflate the balloon then withdraw it leaving the wire guide in place. Advance the access sheath and aligning stent, which was removed to facilitate the molding balloon, back over the wire guide, through the fenestration and into the respective vessel. (Figure 56)

- If there is a single fenestration (Section 14.1, 1a), then the molding balloon and wire guide can be safely removed.

**NOTE:** Care should be taken during removal to not disturb the guide sheath and wire guide(s), which remain in the target vessel(s).

**WARNING: The Zenith Fenestrated AAA Endovascular Graft incorporates a suprarenal stent with fixation barbs. Exercise extreme caution when manipulating interventional devices in the region of the suprarenal stent.**

- Return to Section 11.4.6, Docking of top cap.

If still unable to fully deploy the suprarenal stent, perform the following steps:

### 14.2 Proximal body placement without distal attachment

- Tighten the pin vise and deflate the balloon, while maintaining balloon position.

- Remove the safety lock from the white trigger-wire release mechanism. Withdraw and remove the trigger-wire to detach the distal end of the endovascular graft from the delivery system by sliding the trigger-wire release mechanism off the handle and remove via its slot over the device inner cannula. (Figure 57)

- Loosen the pin vise (Figure 58) and, while maintaining inner cannula position, advance the grey positioner and sheath into the graft until the tip of the grey positioner is approximately 2 cm from the gold markers on the proximal edge of the proximal body (Figure 59). The advanced grey positioner provides added support to the inner cannula.

**NOTE:** Take care when advancing the grey positioner as there will be sheaths and wire guides positioned in target vessels. Ensure that the tip of the grey positioner is not advanced into the top cap.

- Lock the pin vise.

- Verify position of the gold markers and ensure the fenestrations are positioned correctly.

- To add support to the inner cannula, inflate the balloon to the full diameter of the graft. (Figure 60)

- Loosen the pin vise (Figure 61). Control the position of the graft by stabilising the grey positioner and balloon catheter.

**CAUTION: Before deployment of the suprarenal stent, verify that the position of the access wire extends just distal to the aortic arch. Ensure that the dilator tip will not extend beyond the end of the access wire guide during advancement, and if required re-position the access wire guide into the aortic arch to accommodate.**

- Deploy the suprarenal stent by advancing the top cap inner cannula 1 to 2 mm at a time while controlling the position of the proximal body until the top stent is fully deployed (Figures 62 and 63). Advance the top cap cannula an additional 1 to 2 cm and then retighten the pin vise (Figure 64) to avoid contact with the deployed suprarenal stent.

**NOTE:** Care should be taken during removal to not disturb the guide sheath and wire guide(s), which remain in the target vessel(s).

- If there are multiple fenestrations (Section 14.1, 1), deflate the balloon then withdraw it leaving the wire guide in place. Advance the access sheath and aligning stent, which was removed to facilitate the molding balloon, back over the wire guide, through the fenestration and into the respective vessel. (Figure 65)

- If there is a single fenestration (Section 14.1, 1a), then the molding balloon and wire guide can be safely removed.

**NOTE:** Care should be taken during removal to not disturb the guide sheath and wire guide(s), which remain in the target vessel(s).

**WARNING: The Zenith Fenestrated AAA Endovascular Graft incorporates a suprarenal stent with fixation barbs. Exercise extreme caution when manipulating interventional devices in the region of the suprarenal stent.**

- Return to Section 11.4.6, Docking of top cap.

**NOTE:** Check to make sure that all trigger-wires are removed prior to withdrawal of the delivery system.









**MR Conditional**



**Quantity per box**



**Keep dry**



**Keep away from sunlight**

---

**Manufacturer**

**William A. Cook Australia Pty. Ltd.**

95 Brandl Street  
Eight Mile Plains QLD 4113  
Australia

Phone: +61 7 3434 6777, 1800 777 222

**Cook Incorporated**

750 Daniels Way  
Bloomington, IN 47404  
U.S.A.

2022-04  
IFU-FU-Rev004  
cookmedical.com  
© COOK 2022